

Case Report

Management of Vertically Growing Class II Malocclusion with a Combination Therapy- A Case Report

¹Jiju Mohan, ²Sandhya Maheshwari,, ³Deepika Bais

^{1,3}Junior Resident, ²Professor

¹⁻³Department of Orthodontics and Dental Anatomy, Dr. Z. A. Dental College, Aligarh Muslim University, Aligarh, India

To cite: Jiju Mohan,
Sandhya Maheshwari,,
Deepika Bais

Management of Vertically
Growing Class II
Malocclusion with a
Combination Therapy- A
Case Report.

J Contemp Orthod 2019;3(4):
23-30.

Received on:
20-10-2019

Accepted on:
13-11-2019

Source of Support: Nil

Conflict of Interest: None

ABSTRACT

The success of the class II treatment depends on the proper diagnosis and treatment planning for that the major role is played by the clinician and the facial growth pattern also plays an important role. The unfavorable growth patterns make it difficult to correct the skeletal malocclusion or to improve the facial profile. The successful use of functional appliances in treatment of skeletal Class II malocclusion is based upon age of patient, compliance of the patient and facial growth pattern. This case report aims to show how the effect of twin block on a growing patient with permanent dentition phase and hyperdivergent growth pattern helps in utilizing the remaining growth and thus minimizing the severity of skeletal malocclusion later followed by extraction of all 1st premolars and helps in achieving the pleasant profile and smile.

Key words: Hyperdivergent growth pattern, vertical growth, twin block, class II malocclusion.

INTRODUCTION

In correcting the dental and skeletal class II malocclusion with mandibular retrognathism and slight maxillary prognathism where the mandibular growth is unfavorable (Retrognathic hyperdivergent), in turn increases the severity of the malocclusion. ^[1] So the proper diagnosis and treatment planning is required. If such case is in the non growing phase might end up with surgical treatment plan, but if is in growing phase one can utilizes the growth to increase the supplementary mandibular length which can help in reducing the severity of the skeletal malocclusion ^[2].

In the present case report a 13 year old female patient reported to the Department of Orthodontics and Dental Anatomy, Dr. ziauddin ahmad dental college and hospital, AMU complaining of forwardly placed upper front teeth. The patient's medical, dental and familial history was not contributory for her malocclusion. The mandibular movements were normal with no sign and symptom of TMD.

The patient was in the permanent dentition. On extra oral examination the patient had an apparently symmetrical, mesoprosopic face, convex profile, 100 % incisal display with symmetrical gummy smile of 2.5mm, incompetent lips with lip trap (Fig1).

Intra-orally, patient presented with a Class II Division 1 malocclusion with Class II molar and canine relation bilaterally, Proclined and protruded maxillary anteriors, mild

mandibular crowding with deep curve of spee, overbite of 80%, overjet of 8mm and Gingivitis in relation to maxillary incisors (fig2).

DIAGNOSIS

T The lateral cephalometric(fig3a) findings were suggestive of “A case of skeletal class II malocclusion with prognathic maxilla and retrognathic mandible (ANB = 7°) with Angle Class II molar and canine relation and hyperdivergent growth pattern (SN-MP = 36 °)”. The orthopantomogram(fig3b) show permanent dentition with all developing third molar buds with no caries and periapical pathologies [Table 1].

Treatment Objectives:

- ✓ To achieve favourable skeletal Class I by growth modification with the functional appliance.
- ✓ To achieve Class I molar and canine relation.
- ✓ Levelling of curve of spee.
- ✓ To achieve normal overjet and overbite.
- ✓ To achieve lip competency and soft tissue balance.

TREATMENT PLAN

Phase 1: Orthopedic stage -myofunctional appliance therapy with twin block.

Phase 2: followed by fixed orthodontic mechanotherapy with extraction of all 1st premolars.

THE PHASE 1: ORTHOPEDIC STAGE

twin block was also seen and control and slight reduction of

| | | Pre-treatment | Post twin block | Post treatment |
|--|-------------------|---------------|-----------------|----------------|
| SNA | | 84° | 83° | 82° |
| SNB | | 77° | 80° | 80° |
| ANB | | 7° | 3° | 2° |
| WITS | | 4mm | 2.5mm | 1.5mm |
| MAXILLENGTH(PNS-A [⊥]) :49MM | | 41 mm | 41mm | 41mm |
| MANDI LENGTH(GO-PG): 77 MM | | 61 mm | 63mm | 63mm |
| SN-MP | | 36° | 35 ° | 35 ° |
| GONIAL ANGLE (123±7°) | | 133° | 131° | 130° |
| MX 1 TO NA: (24.02±5.82°) | | 38° | 35° | 21° |
| MX 1 TO PALATAL PLANE (71°) | | 58° | 58° | 65° |
| U1 TO NA | | 11mm,38° | 9mm,35° | 2.5mm,21° |
| L1 TO NB | | 10mm,38° | 10mm,40° | 4mm,30° |
| INTERINCISAL ANGLE | | 108° | 109° | 121° |
| IMPA | | 104° | 106° | 98° |
| NASOLABIAL ANGLE | | 85° | 91° | 98° |
| INTER LABIAL GAP | | 2mm | 5mm | 1mm |
| LIP STRAIN | | 5mm | 3mm | 0mm |
| E – LINE | UPPER LIP (-4mm) | 5mm | 4mm | 0mm |
| | LOWER LIP (-2 mm) | 4mm | 2mm | 0 mm |
| S – LINE | UPPER LIP (0mm) | 7mm | 7mm | 2mm |
| | LOWER LIP (0mm) | 6mm | 4mm | 2mm |

The patient was asked to wear an acrylic twin block for full time [Figure 5]. This phase was continued for 8 months with full time wearing for 6 months followed by retention period. The treatment objectives achieved post twin block therapy were reduction in overjet from 9mm to 4 mm, skeletal Class I by growth modification with increase in supplementary mandibular length and a headgear effect of

hyper divergence.

IN THE RETENTION PHASE:

In this phase patient was instructed to wear upper reverse incline plane for full time followed by PEA (MBT prescription 0.022x0.028 slot) for levelling and alignment followed by extraction of all 1st premolar and En masse

retraction with sliding mechanics.

STAGE 2: FIXED ORTHODONTIC TREATMENT PHASE.

Treatment reassessment was done after phase 1: The treatment objectives of achieving class I molar and end-on class II canine relation with the increase in supplementary mandibular growth and reduction in slight overjet with control of hyperdivergence throughout the treatment was achieved by the end of 8 months of myofunctional appliance therapy.

After the myofunctional appliance therapy the malocclusion landed up to be the class I bimaxillary protrusion with proclined maxillary and mandibular incisor with the remaining of the overjet. So the extraction of all 1st premolar was planned with minimum anchorage and sliding mechanics [Figure 6] to achieve appropriate overjet and overbite with class I canine relationship and intrusion of incisors for curve of spee correction.

All the remaining objectives were achieved at the End of phase 2 which took around 12 months. There was further reduction in overjet from 4 mm to 1mm with the reduction in optimum overbite. The Class I molar relation was maintained then and the Class I canine relationship was achieved with control of hyper divergence throughout the treatment . Later the finishing and detailing keys were achieved at the end of the treatment which took approximately 3 months [Figure 7].

The lateral cephalometric comparison between pre treatment and post twin block appliance and post treatment with all 1st premolar extraction [Shown in Table 1].

The superimposition shows that the molar and canine relationship was corrected to class I with the reduction in incisor proclination and the facial profile was improved with the chin lip contour shows decrease in the protrusion if upper lip and achievement of good lip seal. The lower facial height remained constant.

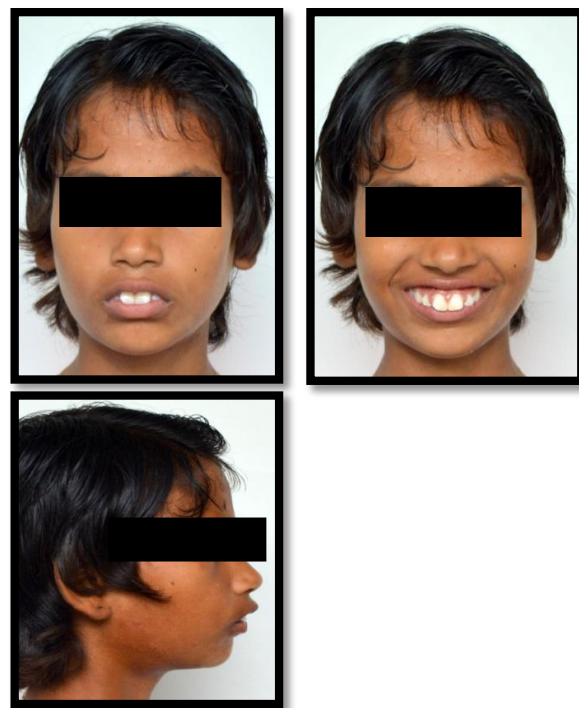

Fig 1: Pretreatment facial photographs

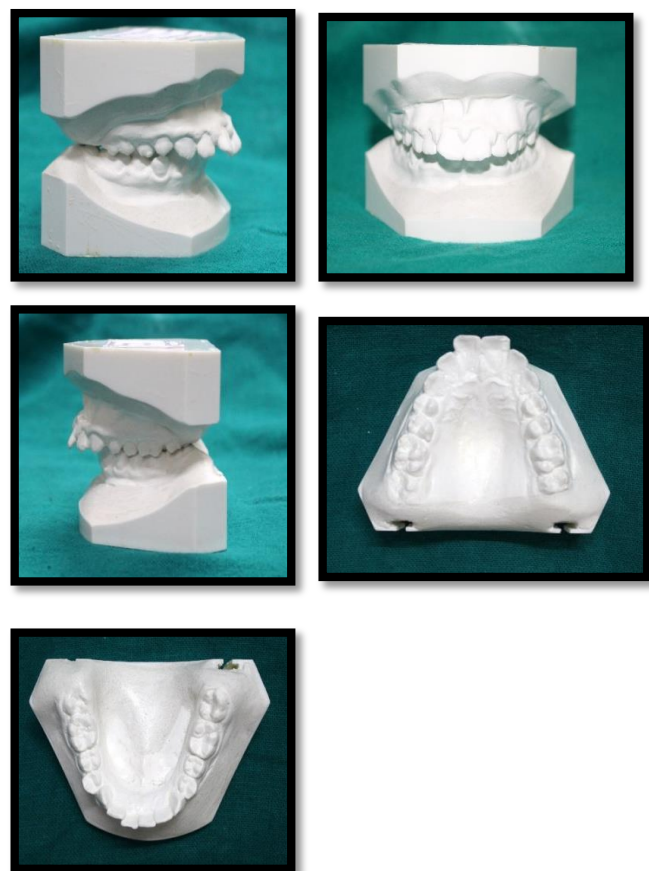

Fig 2: Pretreatment intra-oral study models.

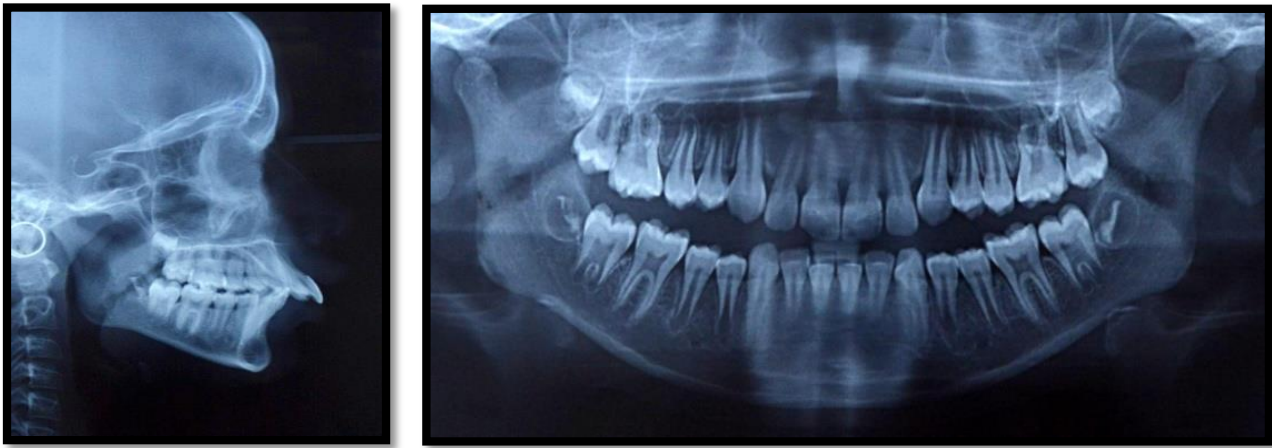

Fig 3: (a) pretreatment lateral cephalogram and (b) OPG.

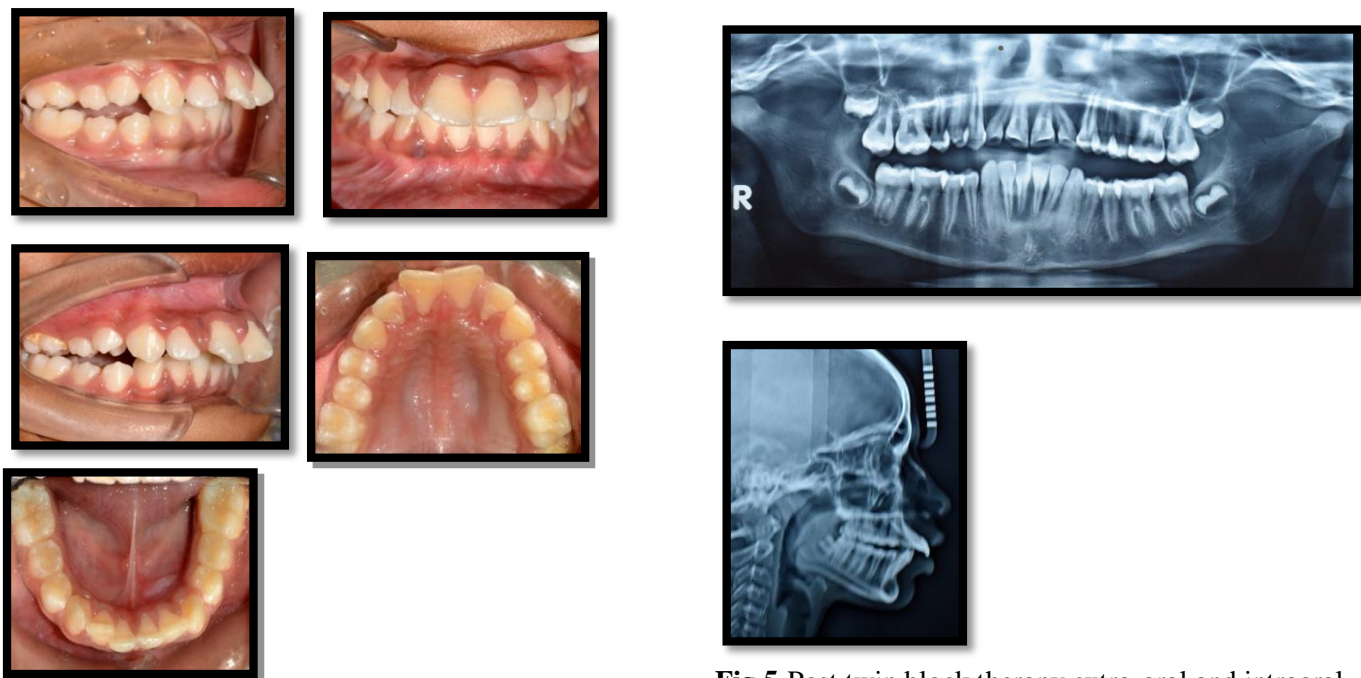


Fig 5-Post twin block therapy extra-oral and intraoral photographs and radiographs

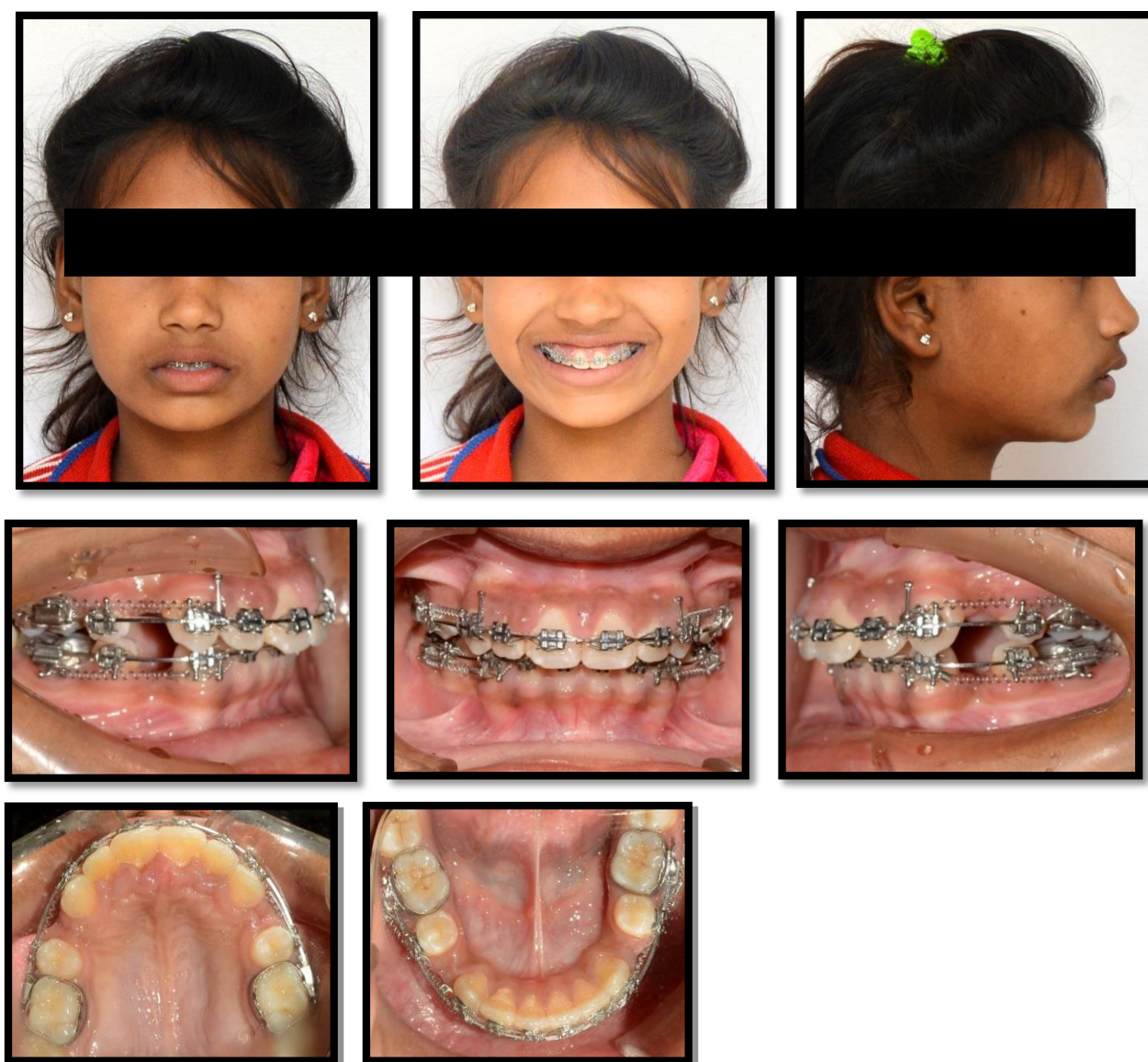
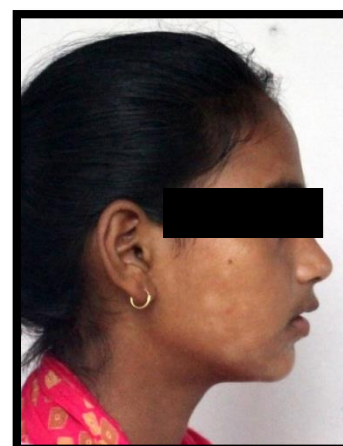
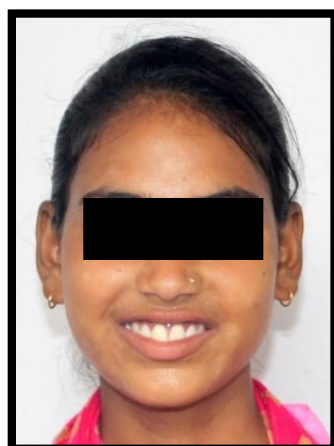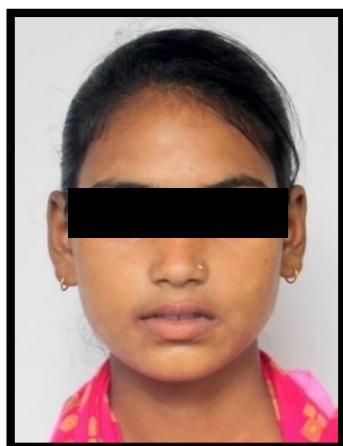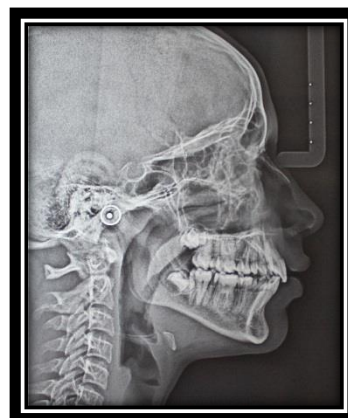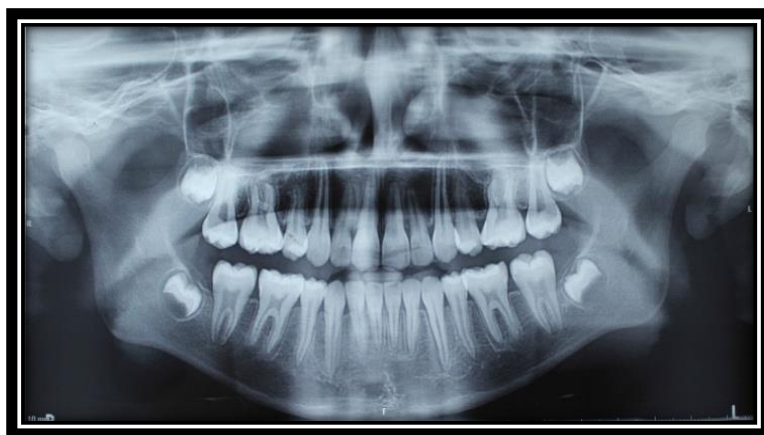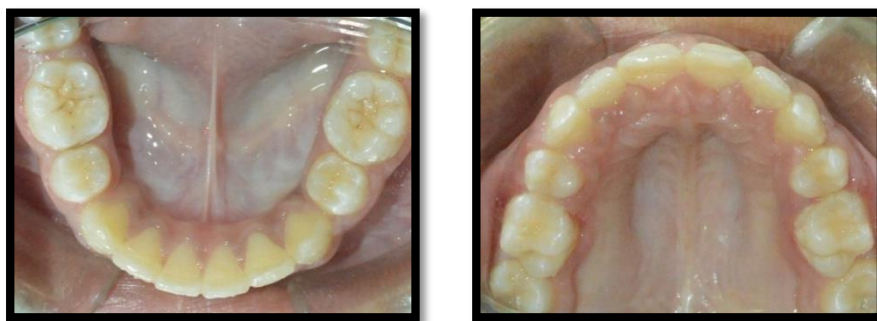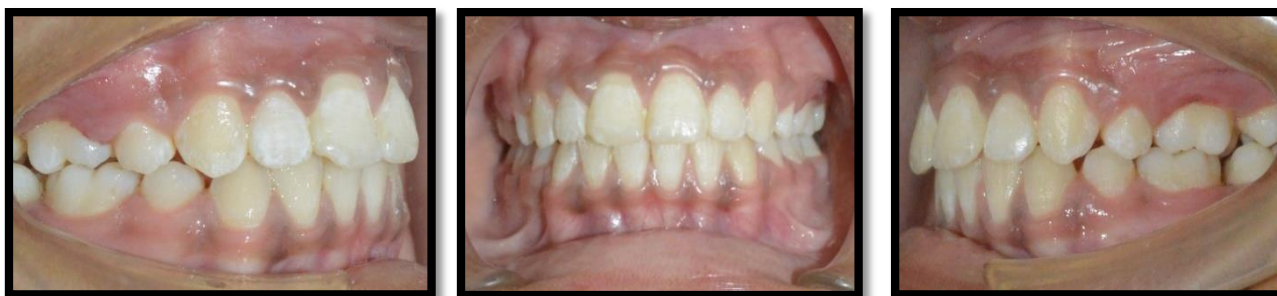Fig 6:- Stage photographs showing fixed orthodontic mechanotherapy followed by extraction of all 1st premolars, and retraction with sliding mechanics with minimum anchorage.





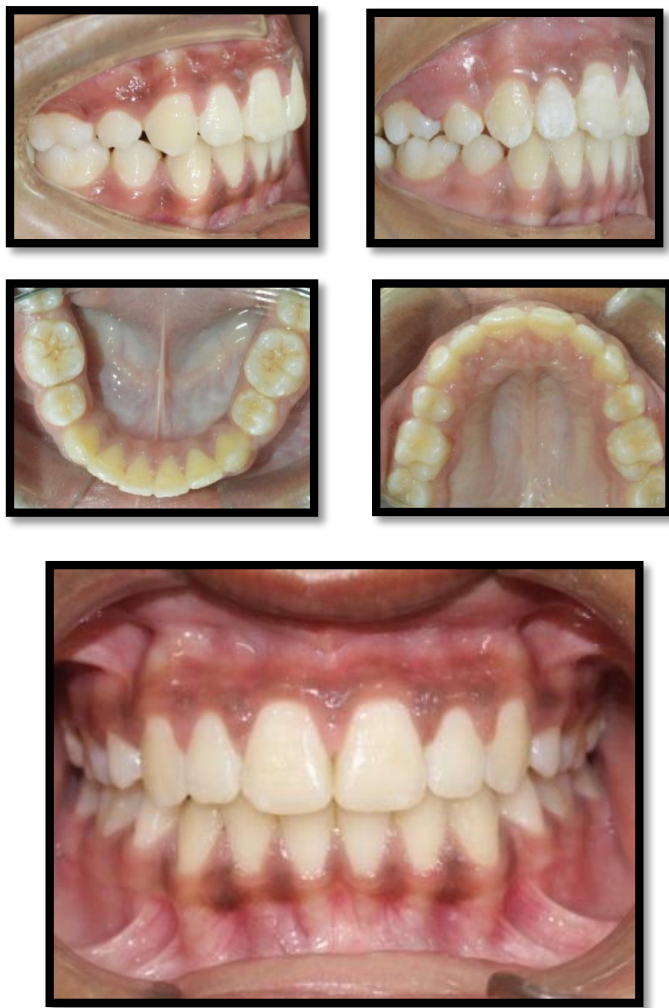

Fig 8- 1 year follow up extra and intra oral records of the patient.

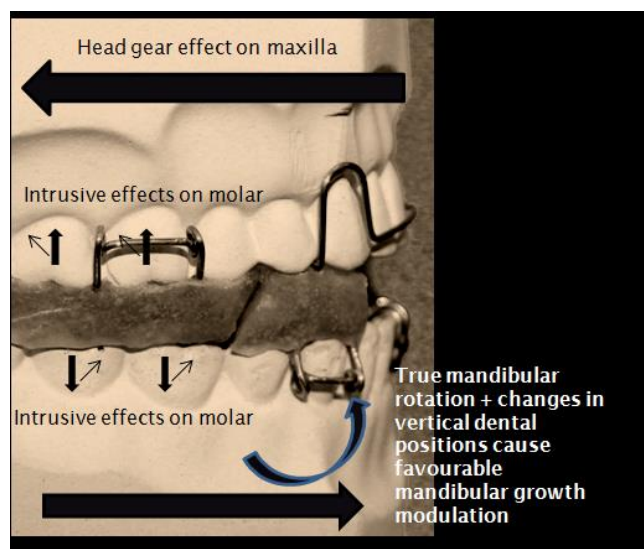


Fig 9: Mechanism of high block twin block.

DISCUSSION

Treatment considerations of Class II malocclusion in a growing individual are influenced to a large extent by growth pattern which can be hyperdivergent, hypodivergent or normodivergent. The amount and direction of growth will significantly alter the orthodontic biomechanics. As Most of the orthodontic mechanics are extrusive, so proper treatment planning must be done specially for hyperdivergent cases [3]. Retrognathic hyperdivergent patients are among the most difficult to treat owing to their complex malocclusion and vertical skeletal growth pattern. The treatment options for such cases are surgical treatment approach and/or non surgical treatment approach. Although traditional approach corrects the malocclusion but does not address the skeletal and soft tissue problem adequately and often fails to control the vertical dimension. Therefore, the surgical approach is a choice of treatment as it produces remarkable skeletal change which is not effectively seen in traditional fixed orthodontic treatment.

In surgical approach the surgery must be delayed until the growth is completed and the patient also hesitates due to the risk, morbidity and financial constraints [4]. So for this reason in the present case we have used the combined approach of orthopedics with extraction fixed orthodontics treatment as the patient was in growing phase with CVMI stage III known to be the best timing for treatment with functional jaw orthopedics [5]. Vertical control of hyperdivergent with mandibular retrognathism depends on true mandibular rotation, which is a primary determinant of anteroposterior chin position. Based on the relation between true rotation of mandible and vertical dental changes, the treatment aimed at reducing vertical skeletal dysplasia thus improving profile convexity with the focus on the vertical control of the dentition [6]. Therefore, along with correction of the dental malocclusion, this approach produces beneficial skeletal changes, including significant increase in SNA, decreases in the gonial angle, increase in the SNB angle with decrease in ANB, increases in chin projection, decrease in facial convexity, and control of vertical facial height (Fig-9) [7].

In one of the study by Antonarakis and Kiliaridis[8] it is demonstrated that the treatment outcomes during functional appliance therapy in Class II Division 1 growing children is greatly influenced by the functional capacity of masticatory muscle. Therefore, one can hypothesize that differences in masticatory muscle capacity in different growth pattern may influence treatment outcome with functional appliance therapy because of their role in controlling the vertical dimension. There are obvious advantages of treating Class II growing patients with myofunctional appliance prior to fixed

orthodontic treatment. As it leads to the management of disto-occlusion with myofunctional therapy with the improvement in the orofacial functions through muscle adaptation along with dental changes and favourable skeletal growth modulation [9].

CONCLUSION

The same treatment mechanics system will produce different responses in different patients with individual growth pattern. Muscle strength often determines these responses.

The worst mistake in orthodontic treatment one can cause is the over eruption of molars in a patient with weak musculature which often leads to worsening of malocclusion.

Using mechanics that limit molar extrusion or controlled mechanics is a better choice for treating hyperdivergent cases.

REFERENCES

1. Pachori Y, Navlani M, Gaur T, Bhatnagar S. Treatment of skeletal class II division 1 malocclusion with mandibular deficiency using myofunctional appliances in growing individuals. *J Indian Soc Pedod Prev Dent* 2012;30:56-65.
2. Khan N, Adeni KM, Parameswaran R, Vijayalakshmi D. Surgical Management of Hyperdivergent Class II Malocclusion with Vertical Maxillary Excess: A 2-year Follow-up. *Contemp Clin Dent*. 2018;9(Suppl 2):S382–S387. doi:10.4103/ccd.ccd_484_18.
3. F. F. Schudy (1964) Vertical Growth Versus Anteroposterior Growth As Related To Function And Treatment. *The Angle Orthodontist: April 1964, Vol. 34, No. 2, pp. 75-93.*
4. Harzer, et al. Molecular diagnosis in Orthodontics, Facial orthopedics and orthognathic surgery: implications for treatment progress and relapse. *Semin Ortho*. 2010;16:118–127.
5. Baccetti, Tiziano et al. Treatment timing for Twin-block therapy. *American Journal of Orthodontics and Dentofacial Orthopedics, Volume 118, Issue 2, 159 - 170*
6. Alec J. Rice, Roberto Carrillo, Phillip M. Campbell, Reginald W. Taylor, and Peter H. Buschang (2019) Do orthopedic corrections of growing retrognathic hyperdivergent patients produce stable results?. *The Angle Orthodontist: July 2019, Vol. 89, No. 4, pp. 552-558.*
7. O'Brien Kevin, et al. Effectiveness of early orthodontic treatment with the Twin-block appliance: A multicenter, randomized, controlled trial. Part 2: Psychosocial effect. *Am J Orthod Dentofacial Orthop*. 2003;124:488–9
8. Antonarakis GS, Kiliaridis S. Predictive value of masseter muscle thickness and bite force on Class II functional appliance treatment: a prospective controlled study. *Eur J Orthod* 2015;37:570-7.
9. McNamara, et al. Treatment timing for Twin-block therapy. *Am J Orthod Dentofacial Orthop*. 2000;118:159–70