

Virtual Placement of The Mandibular Buccal Shelf Bone Screw: A CBCT Evaluation

¹Minu C Mathews, ²Bejoy P.U

¹Post Graduate Student, Department of Orthodontics & Dentofacial Orthopedics, Malabar Dental College and Research Centre, Malappuram, Kerala

²Professor & Head, Department of Orthodontics & Dentofacial Orthopedics, Malabar Dental College and Research Centre, Malappuram, Kerala

To cite:

Minu C Mathews, Bejoy P.U

Virtual Placement of The Mandibular Buccal Shelf Bone Screw: A CBCT Evaluation

J ContempOrthod 2021;5(2): 42-48

Received on:

11-05-2021

Accepted on:

09-06-2021

Source of Support: Nil

Conflict of Interest: None

ABSTRACT

Background & objectives: Buccal shelf area of mandible is a recent addition to temporary anchorage device. The purpose of this study for the assessment of mandibular buccal shelf area for miniscrew insertion using CBCT.

Methods: 24 CBCT images were collected and analysed using ONDEMAND software. Mini screws of 2 x 10 mm, 2 x 12 mm were customised digitally in the software and virtually placed it in particular angles and positions. 4 areas considered are Buccal to the distobuccal cusp of first molar (P1), Buccal to the Interdental area of first and second molar (P2), Buccal to mesiobuccal cusp of second molar (P3), Buccal to distobuccal cusp of second molar (P4). Miniscrews are inserted in 0° (A1), 20° (A2), 30° (A3) angulation to the vertical axis of the tooth and 4mm (H1) and 6mm (H2) apical to cemento Enamel Junction of first and second molar. The cortical bone thickness, the distance from molar root and distance from digitally traced inferior alveolar nerve were measured.

Statistical analyses were performed using Statistical Package for Social Sciences software (SPSS version 26, USA). Normality was checked using the Shapiro Wilk test. As data were not normal Kruskal Wallis ANOVA test was used to compare the data between groups. Bonferroni post hoc tests were used to find out pairwise comparisons. A p-value of <0.5 was considered statistically significant.

Results and discussion: Cortical bone thickness increases as it moves distally from the first molar to the second molar. As insertion depth increases both cortical bone thickness and root clearance become greater. The implant can be placed parallel to the long axis of the tooth adjacent to it as it gives more cortical bone engagement and enough clearance from the root. There is sufficient clearance from the mandibular nerve in all sites and depth at all angulation, so implant insertion is safe at MBS. Root proximity is a limiting factor as there is no enough clearance for root at many sites. Mesiobuccal area of second molar is considered as safe place for insertion of miniscrew. Conclusion: The suitable site for miniscrew insertion for the south Indian population, considered as buccal to the mesiobuccal area of the second molar at 6mm from CEJ and parallel to the long axis of the buccal cusp of the second molar and the implant size is 2x10mm or less.

Key words: Mandibular buccal shelf; Miniscrew; Cortical bone thickness; CBCT.

INTRODUCTION

Class III malocclusion with mild to moderate skeletal discrepancy can be camouflaged by orthodontic treatment alone to achieve a good and stable result. The entire mandibular arch distalization is a viable alternative to regular camouflage treatment for correcting a Class III relationship. However, it is considered as one of the most difficult tooth movements in orthodontics. The development of temporary anchorage devices (TADs), has increased the effectiveness of

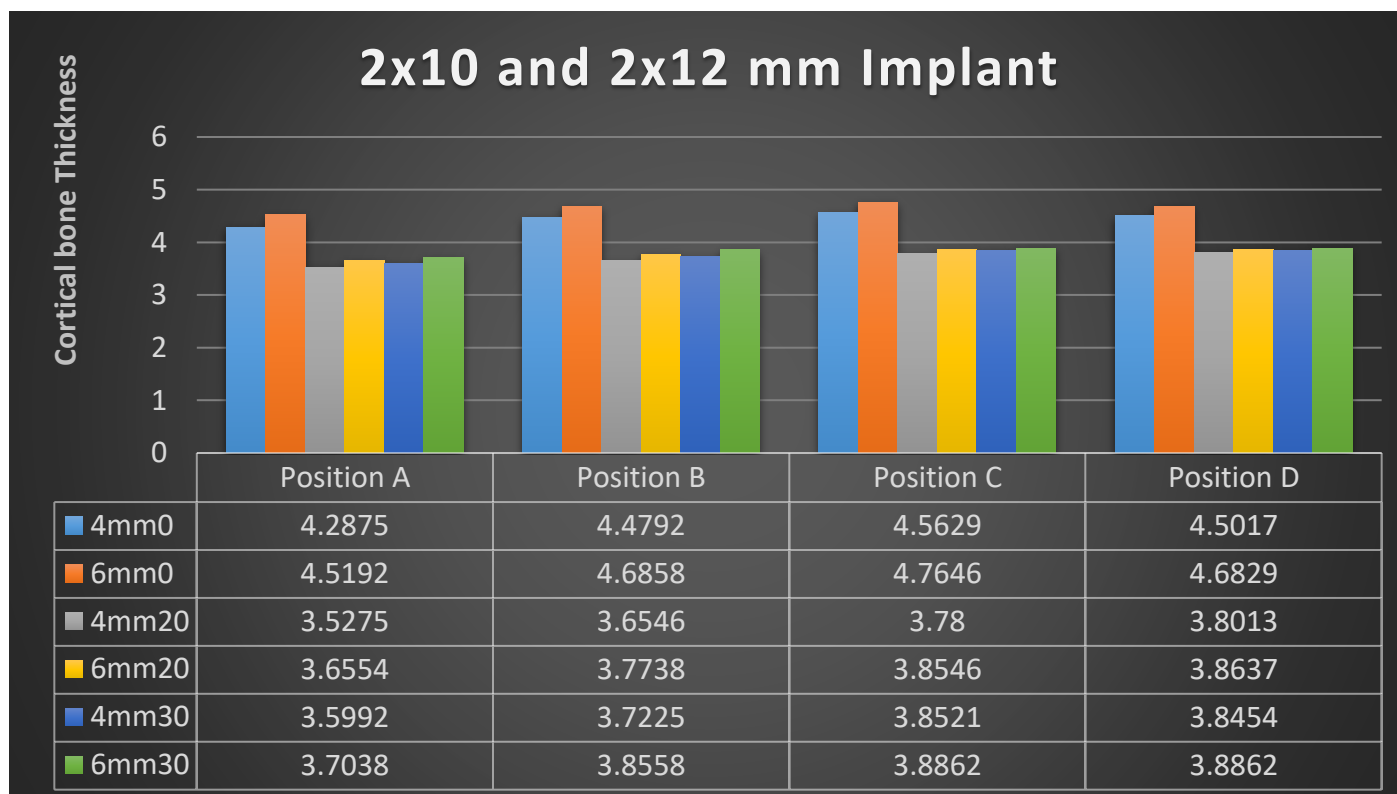
lower arch distalization. These screws can be placed at different sites, such as the retromolar area, inter radicular area, and ramus of the mandible. Chris Chang et al suggested the Buccal shelf area of the mandible (MBS) as a novel area for the insertion of TAD which is considered as effective site as compared to the other sites as the implant is placed extra radicular, which will not interfere with distalization and has got sufficient bone thickness, thus reduces the implant failure. MBS is bilaterally located buccal to the roots of the first and second mandibular molars and anterior to the oblique line of the mandibular ramus, and it is

covered with the thickest cortical bone in the mandible. Accurate knowledge about the anatomic details of the MBS area of a particular population will curtail the necessity of expensive and hazardous CBCT imaging. So a study was planned to assess the MBS area based on cortical bone thickness, nerve and root proximity.

$$n = \frac{(Z_{\alpha} + Z_{\beta})^2}{d^2} \times SD^2 = 24$$

24 CBCTs that satisfied all the inclusion criteria were selected and obtained consents from selected subjects. None of the subjects were exposed for the study purpose alone.

After the CBCT data were acquired, the images were exported



Graph 1 Comparison of Cortical Bone Thickness values based on distance from CEJ at different positions and angulations for 2x10mm implant.

MATERIALS AND METHODS

The study is an in vitro, retrospective, CBCT assessment. Ethical clearance was obtained from the Ethical Committee of Malabar Dental College & Research Centre (Ref No: IEC/05/ORTHO-A/MDC/2018).

Inclusion criteria for the selection of CBCTs were subjects in the age group of 20-40 years, south Indian origin, and completely erupted first and second molars. Subjects with any genetic syndromes or craniofacial dysmorphism, the periodontal disease which caused bone loss, missing first or second molar, crossbite or abnormal position of first or second molars, ectopic eruption, and history of facial trauma with mandibular fracture, previous orthognathic or orthodontic treatment, and lack of proper previous history are excluded from the study.

CBCTs are collected from scan centre, Malappuram, Kerala. Subjects were scanned standing upright with the head positioned in the natural head position. For all the scans the minimum field of view used was 13 x 15 cm and scan time ranged from 1.2 to 8.7 seconds, voxel size of 0.37mm pixel.

A minimum sample size of 24 will be taken so as to assess 95% power and adequate degree of freedom for the study.

into DICOM (Digital Imaging and Communications in Medicine) files and imported to ONDEMAND 3D software version 1.0.10.538 for the analysis.

The orientation is set in sagittal, coronal and axial plane through CEJ, all subsequent images are ready to be created.

Construction of sites for measurements

Four coronal sections are taken at 4 different planes by adjusting the plane in the axial view (Figure 1).

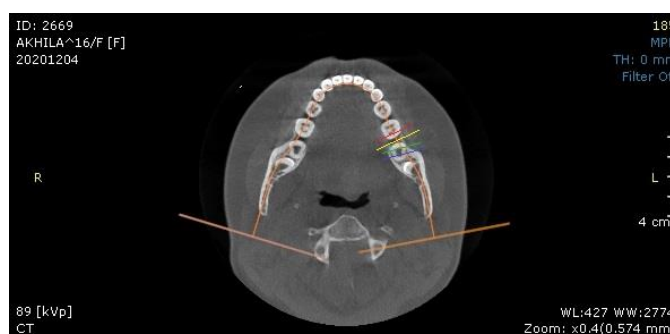
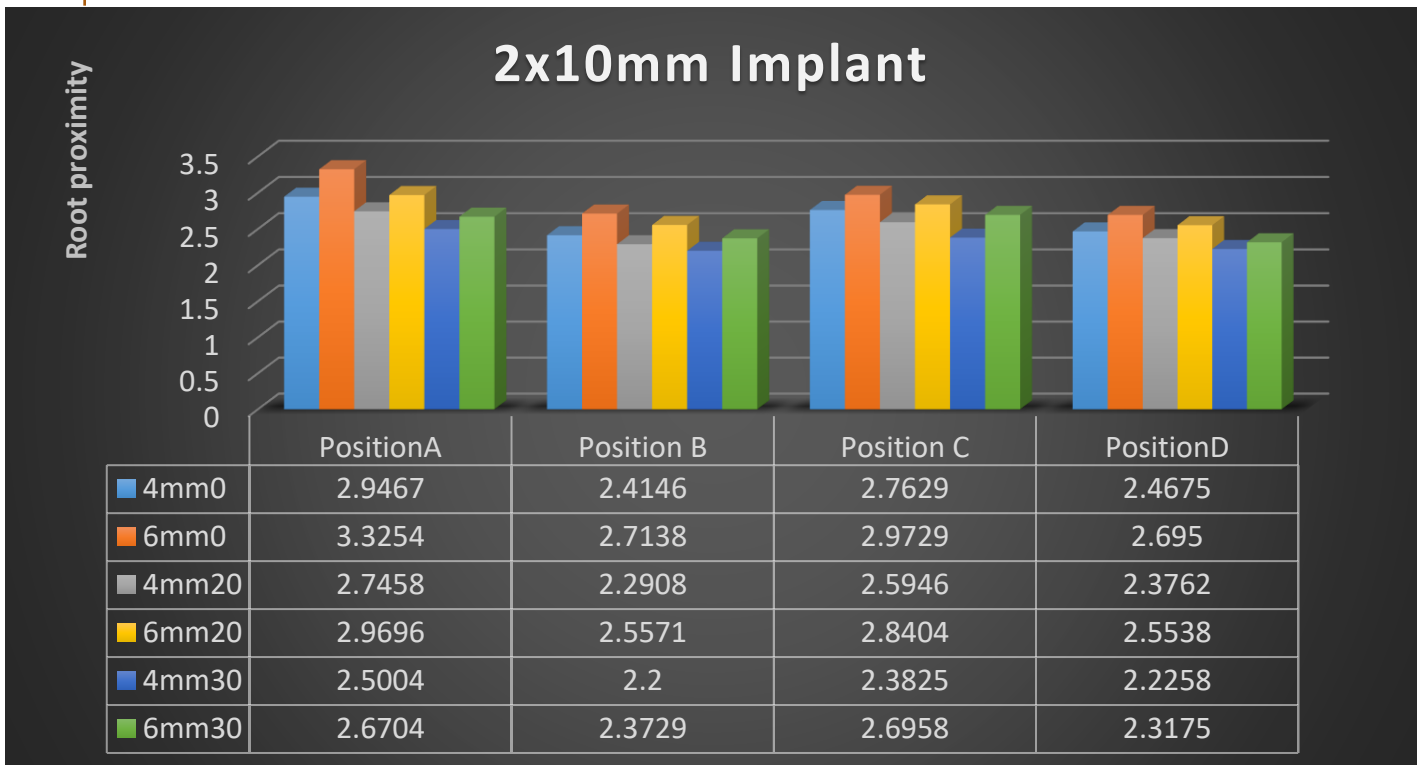


Fig. 1 The CBCT views measured corresponded to four coronal sections P1 (red); P2 (yellow); P3 (green); P4 (blue)



Graph 2 Comparison of Root Proximity From miniscrew values based on distance from CEJ at different positions and angulations for 2x10mm implant.

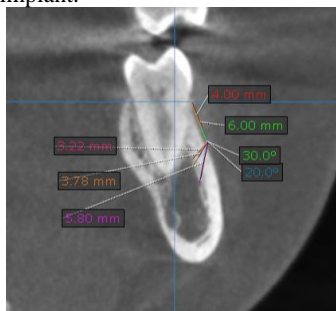


Fig. 2 Coronal slice showing measurement of the cortical bone thickness at the distal cusp of the second molar P4 at H2 in three different angulation A1, A2, A3. (Violet H2A2; orange H2A2; pink H2A3)

P1: Coronal section through the distobuccal and distolingual cusps of the first molar

P2: Coronal section through the interdental area between first and second molars through the contact points

P3: Coronal section through the mesiobuccal and mesiolingual cusp of the second molar

P4: Coronal section through the distobuccal and distolingual cusps of the second molar.

In each coronal section, two points of insertions are selected (figure 2).

H1: 4mm below cemento enamel junction

H2: 6mm below cemento enamel junction

In each point (H1 & H2) implants are inserted at three different angulation (figure 2).

A1: 0° to the long axis of tooth passing through the buccal cusp of the tooth

A2: 20° to the long axis of tooth passing through the buccal cusp of the tooth

A3: 30° to the long axis of tooth passing through the buccal cusp of the tooth

Cortical bone thickness

This measurement was made at 24 different combinations in each sample. In each coronal section (P1, P2, P3, P4) two “vertical levels” which were 4 and 6mm apical to cemento enamel junction (H1 & H2) are marked. Three “insertion angles” which were 0°, 20° and 30° (A1, A2 & A3) to the long axis are marked. After adjusting the site of insertion, vertical level, and insertion angle, the cortical bone thickness was measured from the buccal outline of the mandibular buccal shelf (MBS) to the innermost of the cortical bone along the miniscrew insertion path.

Distance from inferior alveolar nerve:

Traced inferior alveolar nerve and customized two tapered mini-implants of sizes 2x10mm and 2x12mm.

Distance from inferior alveolar nerve: shortest distance from miniscrew to digitally traced inferior alveolar nerve (figure 3).

Table 1 : Summary table with mean values

BUCCAL TO THE DISTOBUCCAL CUSP OF FIRST MOLAR (N=24)

Implant	2x 10 mm Implant						2x 12 mm Implant					
	4 mm from CEJ			6 mm from CEJ			4 mm from CEJ			6 mm from CEJ		
	0	20	30	0	20	30	0	20	30	0	20	30
Cortical bone thickness	4.2875	3.5275	3.5992	4.5192	3.6554	3.7038	4.2875	3.5275	3.5992	4.5192	3.6554	3.7038
Distance from mandibular canal	7.7079	7.7350	7.7804	7.1529	7.1958	7.2375	6.8750	6.8992	6.9483	6.4529	6.4717	6.4988
Root proximity from apex of implant	2.9467	2.7458	2.5004	3.3254	2.9696	2.6704	2.1971	1.9696	1.7850	2.4258	2.1254	1.8421

Root proximity:

Root proximity: distance from implant to the closest molar root is measured in every 2mm vertical slices and select the

irrespective of size, position or distance from CEJ. So the maximum value of cortical bone thickness was obtained at 0° angulation and minimum at 20° angulation for both 4mm and 6mm from CEJ, at all 4 positions examined (graph 1).

Table 2: Summary table with mean values

Buccal To The Interdental Area Of First And Second Molar (N=24)

Implant	2x 10 mm Implant						2x 12 mm Implant					
	4 mm from CEJ			6 mm from CEJ			4 mm from CEJ			6 mm from CEJ		
	0	20	30	0	20	30	0	20	30	0	20	30
Cortical bone thickness	4.4792	3.6546	3.7225	4.6858	3.7738	3.8558	4.4792	3.6546	3.7225	4.6858	3.7738	3.8558
Distance from mandibular canal	7.4275	7.4579	7.3921	6.9113	6.9363	6.9600	6.5883	6.6250	6.6583	6.1046	6.1088	6.1221
Root proximity from apex of implant	2.4146	2.2908	2.2000	2.7138	2.5571	2.3729	2.1404	2.0408	1.8417	2.4463	2.2000	1.9867

shortest measurement in the axial plane (figure 3).

All the measurements were repeated in P2, P3 & P4 planes also.

The inter-examiner and intra-examiner reliability is analysed by kappa statistics and values obtained were 0.82 and 0.87 respectively.

STATISTICAL ANALYSES

Statistical analyses were performed using Statistical Package for Social Sciences software (SPSS version 26, USA). Normality was checked using the Shapiro Wilk test. As data were not normal Kruskal Wallis ANOVA test was used to compare the data between groups.

Bonferroni post hoc tests were used to find out pairwise comparisons. A p-value of <0.5 was considered statistically significant.

RESULTS

Considering the overall summary tables for mean values (Tables 1-4), it was observed that the mean cortical bone thickness reduced as the angulation changed from 0° to 20° .but thereafter increased with increase in angulation to 30°

Meanwhile the distance from mandibular canal increased with increase in angulation thereby having maximum value at 30° angulation for 2x10mm and 2x12mm miniscrew at all 4 positions for both 4mm and 6mm distance from CEJ, except for 2x10mm miniscrew at 4mm from CEJ at position B which showed a downward trend as angulation changed from 20° to 30°.

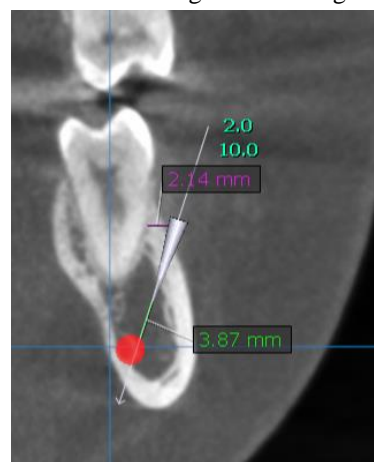


Fig. 3 Coronal section with traced inferior alveolar nerve, virtually placed miniscrew, and measurements of distance to root and nerve.

second molar, at two vertical levels and on three angulations.

On contrary mean value for root proximity from miniscrew Our results indicates cortical bone thickness is thinnest at the

Table 3: Summary table with mean values
Buccal To The Mesiobuccal Cusp Of Second Molar (N=24)

Implant	2x 10 mm Implant						2x 12 mm Implant					
	4 mm from CEJ			6 mm from CEJ			4 mm from CEJ			6 mm from CEJ		
	0	20	30	0	20	30	0	20	30	0	20	30
Cortical bone thickness	4.5629	3.7800	3.8521	4.7646	3.8546	3.8862	4.5629	3.7800	3.8521	4.7646	3.8546	3.8862
Distance from mandibular canal	7.0658	7.1129	7.1129	6.5379	6.5671	6.6008	6.2675	6.2979	6.3500	5.7588	5.7879	5.8300
Root proximity from apex of implant	2.7629	2.5946	2.3825	2.9729	2.8404	2.6958	2.3558	2.2179	2.0042	2.5242	2.3950	2.2221

decreased consistently with increase in angulation from 0⁰ to 30⁰, at all 4 positions, at 4mm and 6mm from CEJ for both the miniscrew sizes. So maximum values were observed at 0⁰ angulation and minimum at 30⁰ angulation(graph 2,3).

DISCUSSION

Cortical bone thickness is the most important factor determining primary stability. Inaba and Park et al. suggest placing the TAD at an angle to the bone surface to increase bone contact.^{1,2} At MBS miniscrew can be placed in different angulation as it is an extra alveolar site so decided to take three angulations as 0⁰, 20⁰,30⁰ to the long axis of the buccal cusp of the adjacent teeth. Beyond this angulation, there is an increased chance for the implant to contact the root surface.

distobuccal cusp of the first molar and thickest at the distobuccal cusp of the second molar. Even though the maximum thickness is seen at the distobuccal area of the second molar, the mesiobuccal area of second molar is not exhibiting significant variation. There is a significant increase in the cortical bone thickness at 6mm than 4mm from CEJ. These are in agreement with previous studies as the cortical bone thickness increases as moves distally and apically.

When considering the insertion angulation there is a statistically significant increase in cortical bone thickness when it is parallel to the long axis of the molar. An increase of 0.66 – 1.00 mm while comparing 0⁰ and 30⁰.

Chang et.al and Trivedi et.al who have taken 90⁰ and 30⁰ to the slope of MBS and found an increase of 0.56-1.24 mm when

Table 4: Summary table with mean values
Buccal To Distobuccal Cusp Of Second Molar (N=24)

implant	2x 10 mm implant						2x 12 mm implant					
	4 mm from CEJ			6 mm from CEJ			4 mm from CEJ			6 mm from CEJ		
	0	20	30	0	20	30	0	20	30	0	20	30
Cortical bone thickness	4.5017	3.8013	3.8454	4.6829	3.8637	3.9129	4.4967	3.7971	3.8417	4.6775	3.8575	3.9071
Distance from mandibular canal	6.6446	6.6763	6.6971	6.0283	6.0650	6.0792	5.8142	5.8313	5.8696	5.2513	5.2717	5.3438
Root proximity from apex of implant	2.4675	2.3762	2.2258	2.6950	2.5538	2.3175	1.6983	1.5504	1.3971	1.9500	1.7863	1.5858

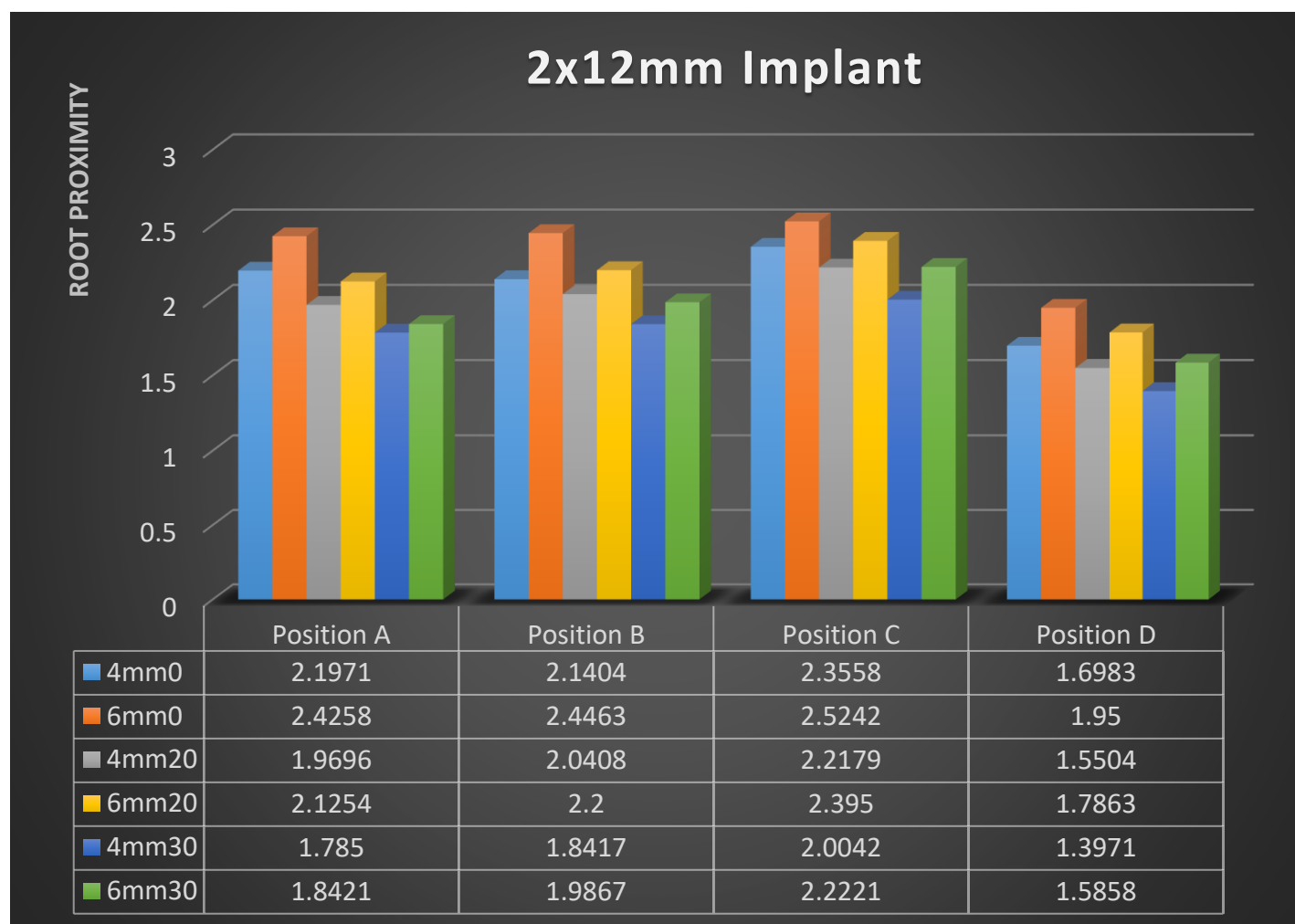
Kolge et.al and Ono et.al showed that the cortical bone thickness significantly increased in more apical areas.³ However, Deguchi et.al angulated the TAD at 45⁰ and did not find a significant difference in the buccal cortical bone thickness at the occlusal level and apical level.⁴ So a study we planned to assess the cortical bone thickness at four locations from distobuccal cusp of first molar to distobuccal cusp of

angulated 30⁰ which is almost parallel to the long axis of the adjacent molar.^{5,6} Parinyachaiphun et.al also shown that when the minisrews are placed parallel to long axis of teeth, we have more cortical bone thickness and more favourable considering primary stability.⁷ Our result also showed similar values.

Contact of miniscrew with root is considered one of the most frequent causes of failure. The placement technique focuses on minimal root damage during screw placement. Park et.al. suggested placing the screws at an obtuse angle to the bone surface to increase bone contact and lower the risk of root damage.² Placing the devices in an extra alveolar site like the MBS permits the use of larger-diameter screws that can be

mesiobuccal cusp of the second molar. When it moves apically and in 0° angulation, the clearance is more. The only previous study evaluating root

proximity is by Parinyachaiphum et.al gives a similar result as buccal to the second molar is safer and in more vertical angulation and at the more apical position and he is only comparing two positions that are the interdental area between



Graph 3 Comparison of Root Proximity From miniscrew values based on distance from CEJ at different positions and angulations for 2x12mm implant.

inserted parallel to the axial inclination of molars and not interfere with tooth roots. Therefore, to avoid root contact with miniscrew during insertion or distalization, a distance of at least half of the diameter of TAD plus the periodontal ligament space width, which was 1.21mm (rounded up to 1.5mm), should be available.⁷

As the position, depth, insertion angles, and implant size can influence root proximity we decided to compare each factor to have more clarity, which will help the clinician during MBS miniscrew insertion.

When comparing root proximity, maximum clearance is seen buccal to the distobuccal cusp of the first molar and

two molars and the mesiobuccal area of the second molar.⁷

As the anatomical structures associated with the buccal shelf, the relationship of the inferior alveolar nerve to the miniscrew evaluated. The ability to digitally trace the nerve will help the clinician to determine the insertion path and decrease the probability of violating the nerve. According to Greenstein et.al a clearance of 2mm from the nerve is considered safe for the insertion of implants.⁸ Elshebiny et.al found that the screws had the greatest proximity to the nerve at the distal aspect of the second molar in the MBS site and there also ample safe distance was present.⁹

Here we have assessed nerve proximity using two implant sizes of 2x10 mm and 2x12 mm and sites with enough clearance only taken as a suitable site for miniscrew insertion.

Proximity to the mandibular canal is maximum at buccal to the distobuccal cusp of the second molar and minimum at the distobuccal cusp of the first molar. There is a statistically significant changes seen as it moves distally. When it moves apically implant is closer to the nerve and the same tendency seen as implant length increases. When comparing angulations implant is closer when place at 0°, as it places more angulated clearance is more. Our results are in agreement with previous studies conducted by Kolge and Elshebiny.^{3,9} There is enough clearance for the mandibular nerve in all the sites and angulations so that any site is safer for implant placement concerning nerve proximity.

LIMITATIONS

The gender and skeletal pattern of individuals also have influence on bone anatomy, so a study with large sample size and considering gender and skeletal patterns provide more light into these aspects. The clinician should be cautioned about the individual variation in the anatomy.

When considering all the parameters studied at different site and angulations, the most suitable position for implant insertion can be buccal to the mesial cusp of the second molar as there is enough cortical bone thickness for the stability of the implant. And maximum clearance for root proximity consideration, area buccal to mesiobuccal cusp of the second molar will be the safest position. Depth for the insertion can be 6mm below cemento-enamel junction which has more bone thickness as well as clearance from roots also. Implant angulation can be parallel to the long axis of the molar to engage more cortical bone and to have considerable root clearance. The size of the implant can be taken 2x10mm or less, which are safe and it can give enough cortical bone engagement and safe for insertion without the necessity for CBCT.

CONCLUSION

- Cortical bone thickness increases as it moves distally from the first molar to the second molar. So area buccal to the second molar can be considered as suitable for miniscrew insertion.
- As insertion depth increases both cortical bone thickness and root clearance are increases. So 6 mm from CEJ can be considered as the depth of insertion for miniscrew.
- The implant can be placed parallel to the long axis of the tooth adjacent to it as it gives more cortical bone engagement and enough clearance from the root.
- There is sufficient clearance from the mandibular nerve in all sites and depth at all angulation, so implant insertion is safe at MBS.

- Root proximity is a limiting factor as there is no enough clearance for root at many sites. Mesiobuccal area of second molar is considered as safe place for insertion of miniscrew. Considering the vertical depth, 6 mm from CEJ provide enough clearance if implant place at 0° angulation.
- To conclude, suitable site for miniscrew insertion for the south Indian population, can be buccal to the mesiobuccal area of the second molar at 6mm from CEJ and should insert parallel to the long axis of the buccal cusp of the second molar and the implant size can be 2x10mm or less.

REFERENCES

1. Inaba M. Evaluation of primary stability of inclined orthodontic mini-implants. *J Oral Sci.* 2009 Sep;51(3):347-53. doi: 10.2334/josn.51.347. PMID: 19776501.
2. Park HS, Jeong SH, Kwon OW. Factors affecting the clinical success of screw implants used as orthodontic anchorage. *Am J Orthod Dentofacial Orthop.* 2006 Jul;130(1):18-25. doi: 10.1016/j.ajodo.2004.11.032. PMID: 16849067.
3. Kolge NE, Patni VJ, Potnis SS. Tomographic mapping of buccal shelf area for optimum placement of bone screws: A three-dimensional cone-beam computed tomography evaluation. *APOS Trends in Orthodontics.* 2019;9:241-5.
4. Deguchi T, Nasu M, Murakami K, Yabuuchi T, Kamioka H, Takano-Yamamoto T. Quantitative evaluation of cortical bone thickness with computed tomographic scanning for orthodontic implants. *Am J Orthod Dentofacial Orthop.* 2006 Jun;129(6):721.e7-12. doi: 10.1016/j.ajodo.2006.02.026. PMID: 16769488
5. Chang CH, Huang, C, Roberts WE., 3D Cortical Bone Anatomy of the Mandibular Buccal Shelf: a CBCT study to define sites for extra alveolar bone screws to treat Class III malocclusion. *International Journal of Orthodontics & Implantology.* 2016;41:74-82.
6. Trivedi K, Jani BK, Hirani S, Radia MV. Comparative Evaluation of Cortical Bone Anatomy of Mandibular Buccal Shelf for Mini Implant Placement in Different Facial Divergence: A Cone Beam Computed Tomography Study. *Journal of Indian Orthodontic Society.* 2020;54(4):325-31.
7. Parinyachaphun S, Petdachai S, Chuenchompoonut V. Considerations for placement of mandibular buccal shelf orthodontic anchoring screw in Class III hyperdivergent and normodivergent subjects – A cone beam computed tomography study. *Orthodontic Waves.* 2018;77(1):44-56.
8. Greenstein G, Tarnow D. The mental foramen and nerve: clinical and anatomical factors related to dental implant placement: a literature review. *J Periodontol.* 2006 Dec;77(12):1933-43. doi: 10.1902/jop.2006.060197. PMID: 17209776.
9. Elshebiny T, Palomo JM, Baumgaertel S. Anatomic assessment of the mandibular buccal shelf for miniscrew insertion in white patients. *Am J Orthod Dentofacial Orthop.* 2018 Apr;153(4):505-511. doi: 10.1016/j.ajodo.2017.08.014. PMID: 29602342.