



Case Report

Extraction followed by micro-osteoperforation: A simple, efficient and rapid approach for treatment of anterior open-bite in a growing patient - A case report

Gaurav Sharma^{1*}, Rajan Nikumbh¹, Ashish Gupta¹, Thokchom Joshitra¹,
Rashmi Puri¹

¹Dept. of Orthodontics, Vyas Dental College and Hospital (Affiliated To. Rajasthan University of Health Sciences), Jodhpur, Rajasthan, India



ARTICLE INFO

Article history:

Received 05-03-2022

Accepted 22-04-2022

Available online 04-06-2022

Keywords:

Temporomandibular

Crimpable

Mesoprosopic

ABSTRACT

This case report discusses orthodontic treatment combined with extraction followed by micro-osteoperforation to accelerate tooth movement and shorten the treatment time in 13-year-old female patient with an Angle's Class I malocclusion with anterior open-bite, proclined upper and lower anterior teeth, posterior-crossbite. Fixed orthodontic appliances (MBT 0.022" pre-adjusted edgewise brackets) were bonded, Begg's brackets were bonded on lower anterior lingually and lingual buttons with upper central incisors palatally for breaking tongue-trusting-habit, 4-months later extraction of first premolar in all the four quadrants was carried out, and after-2-months micro-osteoperforation in the extraction space region was performed. Orthodontic therapy continued with frequent activation of the appliances to retract the anterior teeth every-20-days. Total treatment time was 21-months with an active period of 15-months and no adverse effect were observed at the end of active period. Successful closure of the anterior open-bite and correction of posterior-crossbite with adequate overbite and interdigitation of the teeth was achieved.

This is an Open Access (OA) journal, and articles are distributed under the terms of the [Creative Commons Attribution-NonCommercial 4.0 International](https://creativecommons.org/licenses/by-nc/4.0/), which allows others to remix, and build upon the work non-commercially, as long as appropriate credit is given and the new creations are licensed under the identical terms.

For reprints contact: reprint@ipinnovative.com

1. Introduction

Patients in young age group now-a-days are very concerned about orthodontic treatment and the time needed to correct, being their prime priority.¹ Four primary factors of open bite are Thumb or pacifier sucking, Tongue thrusting, Temporomandibular joint disorder, Skeletal problem. In orthodontics, one of the challenging and difficult cases to treat is anterior open-bite. Some main morphological characteristics of this type of malocclusion are; increased lower facial height and steep mandibular plane which mostly leads to over-erupted maxillary posterior dentition.²⁻⁵ Conventional fixed orthodontic treatment requires 2-3 years to get completed which indirectly leads to high risk of caries, root resorption,

and reduced patient compliance,⁶⁻¹² To reduce the treatment time different methods such as low-level laser therapy, orthodontic camouflage with premolars or first molars extraction, pulsed electromagnetic fields, electrical currents, micro-osteoperforation, corticotomy, distraction osteogenesis, and mechanical vibration can be used combined with conventional orthodontics.¹³⁻²² Studies have shown that open bite treated with extraction has greater stability of the overbite than open-bite non-extraction treatment.²³ In orthodontics, micro-osteoperforation (MOP) can be done to perforate the bone around the teeth with small-pinhole perforation to accelerate the rate of tooth movement during orthodontic treatment. This procedure activates the release of cytokines that in turn recruit osteoclasts to the area to increase the rate of bone resorption.²⁴ Tongue thrusting is one of the commonest causes of anterior open bite. Anterior tongue posture or

* Corresponding author.

E-mail address: drgouravs1983@gmail.com (G. Sharma).

macroglossia are the two main reasons of tongue thrusting habit. Habit breaking appliances such as tongue crib or lingual tongue restraining spikes can be given in growing age to correct anterior tongue thrusting. This gives a negative reinforcement to the tongue and which results in new corrected tongue posture. Once the growth ceases, the new corrected tongue posture is very difficult to develop and hence posttreatment retention is one of the major concerns for an orthodontist.²⁵ The goal of this case report is to correct anterior open-bite due to tongue thrusting with rapid and effective method of extraction and micro-osteoperforation facilitated orthodontic treatment of a young patient.

2. Case Report

A 13-year-old female patient reported with the chief complaint of inability to close the mouth and forwardly placed teeth in front region of the jaw. She had no relevant medical history, good oral hygiene and periodontal health, with a restoration done 1-year-ago.

2.1. Etiology

The patient had a habit of mouth breathing with anterior tongue thrust. The habit of tongue thrust was due to enlarged tongue size (macroglossia) with no abnormality in speech.

2.2. Extraoral examination

No gross facial asymmetry with mesoprosopic face form. On profile examination, patient had convex facial profile with symmetric and flat smile and incompetent lips with 100% maxillary incisor display while smiling (Figure 1).

2.3. Intraoral examination

All teeth in the upper and lower arch were present except for the third molars. Ovoid shaped, upper and lower arches. Mucogingival frenal attachment, satisfactory gingival health and low caries risk. proclined upper and lower anterior teeth. Angle's Class I malocclusion with anterior open bite and posterior crossbite due to narrow maxilla and canine relation is Class I on right side and not recordable on left side (Figure 1).

2.4. Functional examination

The patient showed oronasal breathing which was confirmed and tested by water holding test, and due to macroglossia a typical swallowing pattern was observed. Path of mandibular closure was normal with maximum mouth opening was 47mm. Increased overjet of 4mm and 8mm of anterior open bite. According to cephalometric analysis, patient had Class I skeletal bases, average growth pattern. The soft tissue analysis revealed both upper and lower lip protrusion. Nasolabial angle was acute and deep

mentolabial angle (Figures 1 and 4; Table 1).

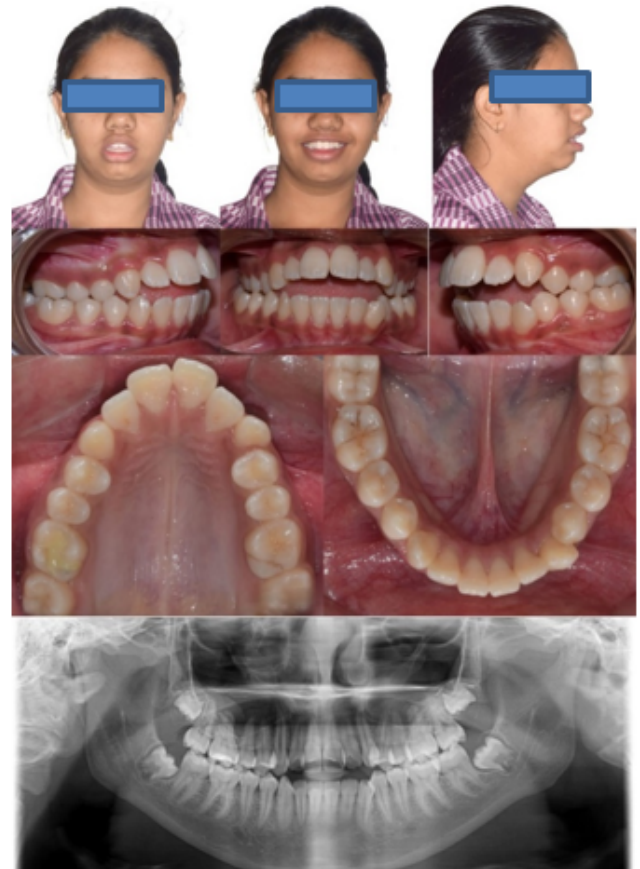

Figure 1: Pre-treatment extra-oral, intra-oral photographs and Panoramic radiograph.

2.5. Treatment objectives

To eliminate the tongue-thrusting habit, improve facial profile and dental aesthetics, close anterior open-bite, correct proclination of upper and lower arch, establish interdigitation of both arch, achieve competence of lips with normal overjet and overbite.

2.6. Treatment plan

The treatment plan advised included comprehensive orthodontic treatment with fixed mechanotherapy to level and align maxillary and mandibular arch by eliminating crowding in both arch, correcting posterior crossbite along with closure of anterior open-bite. Extraction of all four first premolar to attain stability and to accelerate the tooth movement, micro-osteoperforation was carried out. To avoid mesialization of all first molars, second molars were also banded and compound anchorage was achieved.

Table 1: Cephalometric changes

Variable	Pre-treatment	Post-treatment
SNA (°)	87°	87°
SNB (°)	82°	82.5°
ANB (°)	5°	5.5°
Go-Gn to SN (°)	35°	35°
FMA (°)	32°	36°
U1-NA (°)	36°	27°
U1-NA (mm)	16mm	4mm
U1-SN (°)	136°	114°
U1-Palatal plane (°)	125°	112°
U1-NF (mm)	26mm	27mm
L1-NB (°)	40°	30.5°
L1-NB (mm)	10mm	8mm
IMPA (°)	100°	93.5°
L1-MP (mm)	2mm	1.5mm
U6-NF	7°	12.5°
L6-MP	26°	26.5°
Occlusal plane-SN	7.5°	11°
Nasolabial angle	95°	100°
E line: U/L lip	1/-4mm	1/-3mm
U-lip prominence	3mm	2mm
L-lip prominence	5.5mm	4mm

2.7. Treatment progress

Begg's bracket were bonded on lingual surface of 31, 32, 41, 42, 43 and lingual button on 11,21 respectively for correction of tongue thrusting habit. Quad helix was given to correct posterior crossbite with raised posterior bite with Glass Ionomer Cement (Figure 2.a, b), then 0.022" x 0.025" slot dimension preadjusted edgewise orthodontic fixed appliance of MBT prescription metal brackets were bonded in both the arches. Following wires were used during treatment sequentially 0.014", 0.016", 0.018", 0.017" x 0.025" NiTi, 0.019" x 0.025" SS wire. After 4 months of full slot expression of wire and initial levelling and alignment, all first premolars were extracted, and after extraction, within 1 week retraction started and 2mm space were covered up during this 2 months of post extraction. Retraction speed decreased after healing of socket therefore planned for micro-osteoperforation was carried out on the distal aspect of all four canines to fastened up the retraction process (Figure 3).

2.8. Surgical procedure

Under local anaesthesia, 14, 44 were extracted and after 2 weeks 24, 34 were extracted. Immediately after extraction, canine to canine were consolidated and 0.019" x 0.025" SS arch wire was placed in both the arches. Within 1 week, crimpable hooks were placed between lateral incisor and canine in all the four quadrants; and a long elastomeric chain was placed from crimpable hook to molar hook for 2 months with replacement in every 20 days (Figure 3).

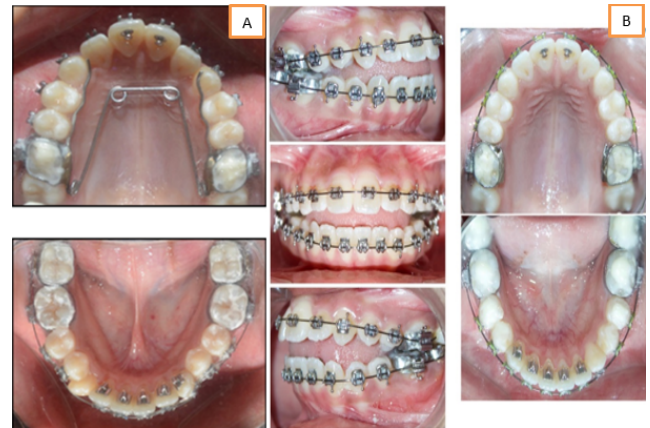

Figure 2: Posteriorcrossbite correction with quad helix. b: Posterior bite raised with glass ionomer cement.

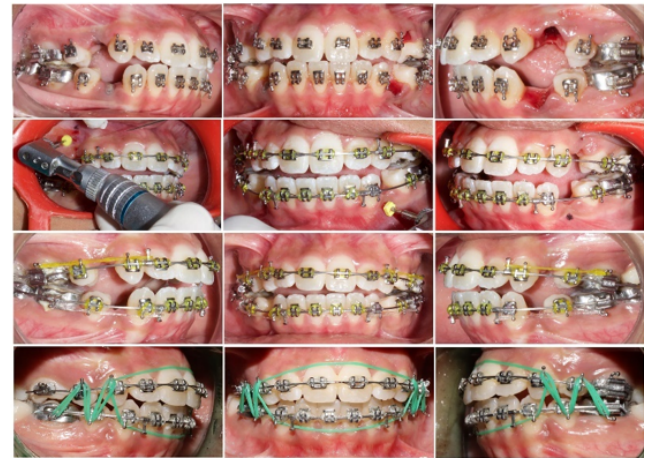

Figure 3: Intraoral photographs after extraction, micro-osteoperforation procedure, Retraction period, settling stage.

With the help of radiographs which were taken prior to micro-osteoperforation, along with the assessment of length and thickness of the attached gingiva, health of periodontium, closeness of the frenum, accessibility of the area of interest; micro-osteoperforation procedure was carried out to the distal aspect of all four canines under topical application of anaesthesia and local anaesthesia.

Approximately 5-6 mm penetration into the alveolar bone was done. The patient was prescribed antibiotic for 5 days after the procedure and advised to gargle with Betadine mouthwash for 1 week to prevent infection and inflammation. Immediately after micro-osteoperforation procedure, canine-to-canine consolidated 0.019" x 0.025" SS arch wire were placed in both the arches, and for next 7 months for retraction with active tie back and replaced every 20 days subsequently to utilize regional accelerated phenomena [RAP] (Figure 3).

2.9. Finishing procedure

The total active treatment period was only 9 months. With the help of N-shaped elastics posteriorly and anterior box elastic were given for the next 2 months and proper interdigitation was achieved. Fixed appliances were removed and fixed retainers were placed in both the arches (Figure 3).

2.10. Treatment outcome

At the end of treatment, facial profile, dental aesthetics, vertical and sagittal relationship were improved and the anterior open-bite was corrected (Figures 4 and 5). Angle's Class I molar and canine relation with normal overbite and overjet were achieved (Figures 5 and 8).

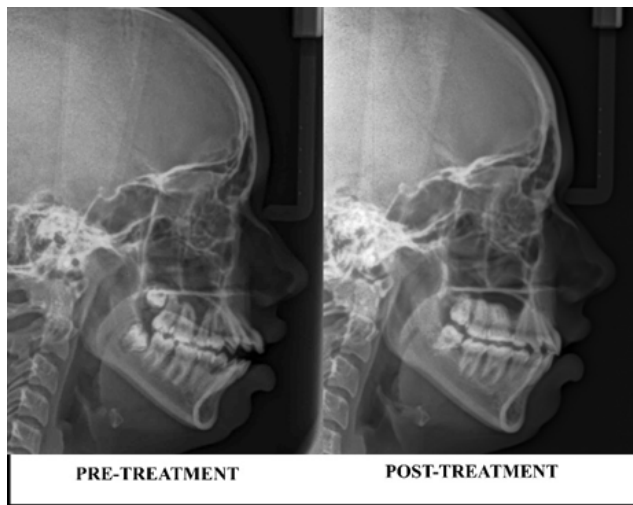


Figure 4: Comparative lateral cephalogram.

Posterior crossbite was corrected. Pleasing smile in the posttreatment extraoral and intraoral photographs. Posttreatment lateral cephalometric analysis and superimpositions showed the difference between pre-and-post treatment changes in both skeletal and dental discrepancies (Figures 1, 4, 5 and 8 and Table 1). In the posttreatment panoramic radiograph, slight apical root resorption was seen in maxillary anterior and erupted maxillary and mandibular third molars as well.

3. Retention

Glossectomy was advised to the patient to correct the etiology of macroglossia of the anterior open-bite after treatment but the patient was not willing for any further surgical intervention. Fixed lingual retainers were bonded from second premolar to second premolar in both arches along with removable Begg's wrap around retainer to reduce the chances of relapse (Figure 6).

Follow up after one-year, showed stable post-retention results (Figure 7).

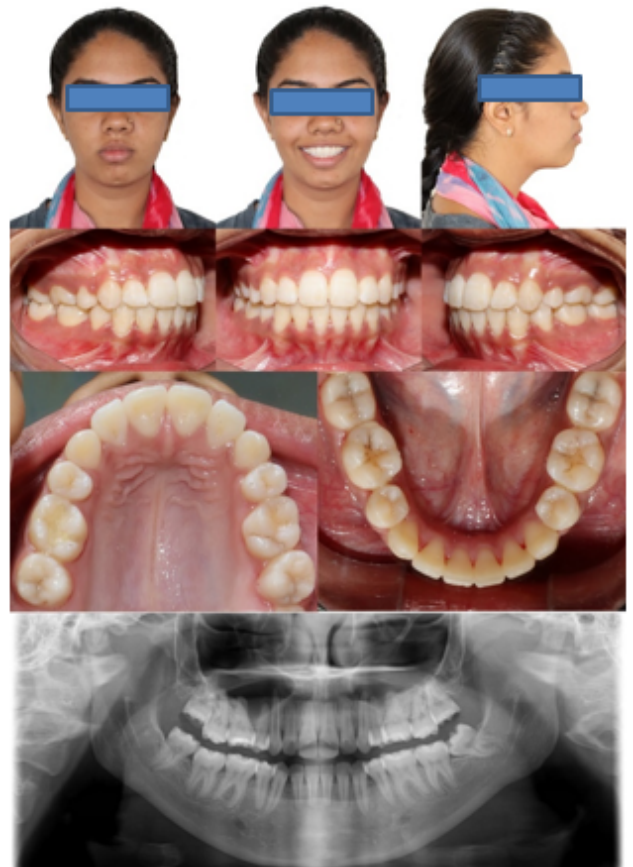


Figure 5: Posttreatment extraoral, Posttreatment intraoral, posttreatment Orthopantomogram.

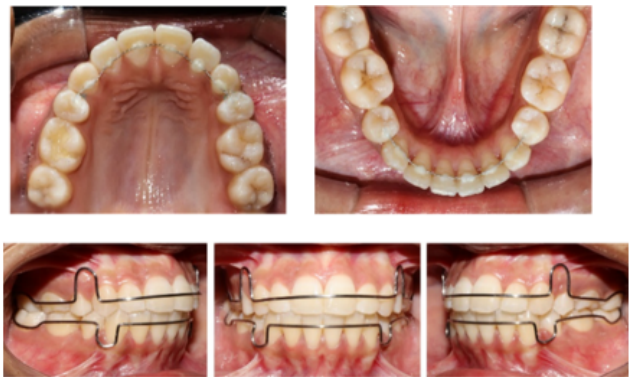

Figure 6: Begg's Wrap around Retainer.

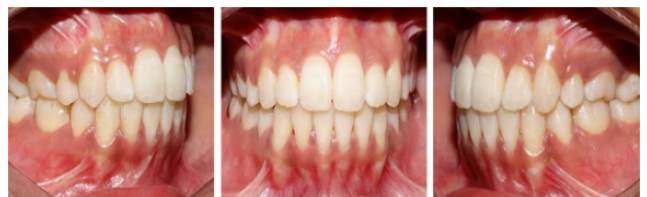

Figure 7: One year follow up photographs.

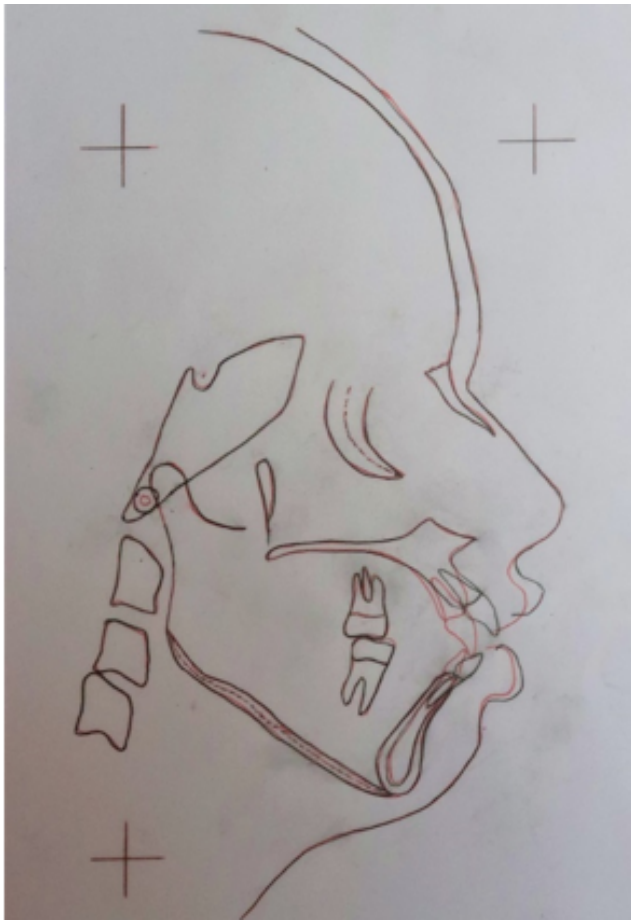


Figure 8: Cephalometric superimposition.

4. Discussion

Dento-alveolar anterior open bite is mostly characterised by macroglossia which leads to anterior tongue thrusting habit.²⁵ Henceforth, a habit breaking appliance is given, as in our case we had given Begg's brackets in lower anteriors and lingual buttons in upper central incisors. It is known that the orthodontic therapy with all four first premolar extraction along with micro-osteoperforation reduces the period of conventional orthodontic treatment. As studies reported in literature, the stability of anterior open-bite in extraction cases is more as compared to non-extraction cases and the rate of tooth movement is rapid in cases of micro-osteoperforation.^{23,24} The total treatment time was only almost half as compared to routine orthodontic therapies.²⁶ Bone mineral density is related to the rate of orthodontic tooth movement. Tooth movement in young patients is faster than in adults.²⁷

The micro-osteoperforation is minimally invasive flapless surgical interventions which increased bone remodelling, osteoclastic activity and induced faster orthodontic tooth movement.²⁸ According to many researchers, there was no significant differences in terms

of pain severity levels after micro-osteoperforation.²⁹ As advocated by Wilcko et al. the conventional orthodontic forces explained the rapid tooth movement due to Regional Acceleratory Phenomenon.^{30,31}

5. Conclusion

Extraction of all four first premolars along with Micro-osteoperforation assisted orthodontics is an effective method in patients with severe malocclusion whose priority is reduced treatment time.

It is important to carefully monitor teeth and surrounding periodontium to avoid risk of devitalization of the teeth and periodontal damage.

5.1. Declaration of patient consent

It is certified by the authors, that all the appropriate patient consent forms have been obtained. The patient has given her consent about her photos and other clinical information to be reported in the journal. The patients have been assured that their names and initials will not be published and all the essential efforts will be made to conceal their identity, but anonymity cannot be guaranteed.

6. Source of Funding

None.

7. Conflict of Interest

None.

References

1. Miyawaki S, Koh Y, Kim R, Kobayasi M, Sugimura M. Survey of young adults women regarding men's orofacial features. *J Clin Orthod.* 2000;34(2):367–70.
2. Survey of young adult women regarding men's orofacial features; 2000. Available from: <https://ci.nii.ac.jp/naid/10010525616/#cit>.
3. Buschang PH, Sankey W, English JP. Early treatment of hyperdivergent open-bite malocclusions. *Semin Orthod.* 2002;8(3):130–40.
4. Buschang H, Sankeyabc MSW. Early treatment of hyperdivergent open-bitemalocclusions. *Seminars Orthod.* 2002;8(3):130–40.
5. Gavito GL, Wallen TR, Little RM, Joondeph DR. Anterior open-bite malocclusion: A longitudinal 10-year postretention evaluation of orthodontically treated patients. *Am J Orthod.* 1985;87(3):175–86.
6. Gavito DDS, Terry R. Anterior open-bite malocclusion: A longitudinal 10-year postretention evaluation of orthodontically treated patients. *Am J Orthod.* 1985;87(3):175–86.
7. Sassouni V. A classification of skeletal facial types. *Am J Orthod.* 1969;55(2):109–23.
8. Sassouni V. A classification of skeletal facial types. *Am J Orthod.* 1969;55(2):109–23.
9. Schudy FF. *Angle Orthod.* 1965;35(1):36–50.
10. Schudy FF. The Rotation Of The Mandible Resulting From Growth: Its Implications In Orthodontic Treatment. *Angle Orthod.* 1965;35(1):36–50.
11. Fink DF, Smith RJ. The duration of orthodontic treatment. *Am J Orthod Dentofac Orthop.* 1992;102(1):45–51.
12. Fin MSF. The duration of orthodontic treatment. *Am J Orthod Dentofac Orthop.* 1992;102(1):45–51.

13. Fisher MA, Wenger RM, Hans MG. Pretreatment characteristics associated with orthodontic treatment duration. *Am J Orthod Dentofac Orthop.* 2010;137(2):178–86.
14. Fisher MA, Wenger RM, Hans MG. Pretreatment characteristics associated with orthodontic treatment duration. *Am J Orthod Dentofac Orthop.* 2010;137(2):178–86.
15. Geiger AM, Gorelick L, Gwinnett AJ, Benson BJ. Reducing white spot lesions in orthodontic populations with fluoride rinsing. *Am J Orthod Dentofac Orthop.* 1992;101(5):403–10.
16. Geiger AM, Gorelick L, Gwinnett A. Reducing white spot lesions in orthodontic populations with fluoride rinsing. *Am J Orthod Dentofac Orthop.* 1992;105(5):403–7.
17. Bishara SE, Ostby AW. White spot lesions: Formation, prevention, and treatment. *Semin Orthod.* 2008;14(3):174–82.
18. Bishara SE. White Spot Lesions: Formation, Prevention, and Treatment. *Semin Orthod.* 2008;14(3):174–82.
19. Segal GR, Schiffman PH, Tuncay OC. Meta-analysis of the treatment-related factors of external apical root resorption. *Orthod Craniofac Res.* 2004;7(2):71–9.
20. Segal GR. Meta analysis of the treatment-related factors of external apical root resorption. *Orthod Craniofacial.* 2004;7(2):71–8.
21. Pandis N, Nasika M, Polychronopoulou A, Eliades T. External apical root resorption in patients treated with conventional and self-ligating brackets. *Am J Orthod Dentofac Orthop.* 2008;134(5):646–51.
22. Pandis N, Nasika M, Polychronopoulou A. American Journal of Orthodontics and Dentofacial Orthopedics. *Am J Orthod Dentofac Orthoped.* 2008;134(5):646–51.
23. Roykó A, Dénes Z, Razouk G. The relationship between the length of orthodontic treatment and patient compliance. *Fogorv Sz.* 1999;92(11):79–86.
24. Roykó A, Dénes Z. The relationship between the length of orthodontic treatment and patient compliance. *Europe PMC.* 1999;92(3):79–86.
25. Cruz DR, Kohara EK, Ribeiro MS, Wetter NU. Effects of low-intensity laser therapy on the orthodontic movement velocity of human teeth: A preliminary study. *Lasers Surg Med.* 2004;35(2):117–37.
26. Cruz DR, Eduardo K, Kohar DD. Effects of low-intensity laser therapy on the orthodontic movement velocity of human teeth: A preliminary study. 2004;35(2):117–20.
27. Yamaguchi M, Hayashi M, Fujita S, Yoshida T, Utsunomiya T, Yamamoto H. Low-energy laser irradiation facilitates the velocity of tooth movement and the expressions of matrix metalloproteinase-9, cathepsin K, and alpha v beta 3 integrin in rats. *Eur J Orthod.* 2010;32(2):131–40.
28. Yamaguchi M, Hayashi M, Fujita S, Yoshida T. Low-energy laser irradiation facilitates the velocity of tooth movement and the expressions of matrix metalloproteinase-9, cathepsin K, and alpha(v) beta(3) integrin in rats. *Eur J Orthod.* 2010;32(2):131–9.
29. Showkatbakhsh R, Jamilian A, Showkatbakhsh M. The effect of pulsed electromagnetic fields on the acceleration of tooth movement. *World J Orthod.* 2010;11(4):52–8.
30. Kim DH, Park YG. The effects of electrical current from a micro-electrical device on tooth movement. *Korean J Orthod.* 2008;38(5):337–46.
31. Kim DH, Park YG, Kang SG. The effects of electrical current from a micro-electrical device on tooth movement. *Korean J Orthod.* 2008;38(5):337–83.

Author biography

Gaurav Sharma, Professor

Rajan Nikumbh, Post Graduate Student

Ashish Gupta, Head of Department

Thokchom Joshitra, Post Graduate Student

Rashmi Puri, Senior Lecturer

Cite this article: Sharma G, Nikumbh R, Gupta A, Joshitra T, Puri R. Extraction followed by micro-osteoperforation: A simple, efficient and rapid approach for treatment of anterior open-bite in a growing patient - A case report. *J Contemp Orthod* 2022;6(2):85-90.