



Clinical Tip

Transpalatal arch modification for posterior unilateral crossbite correction

Madhulika Gupta^{1*}, Aftab Azam¹, Ashish Chauhan¹, Ragni Tandon¹,
Mrinalini Bansal¹

¹Dept. of Orthodontics and Dentofacial Orthopaedics, Saraswati Dental College, Lucknow, Uttar Pradesh, India



ARTICLE INFO

Article history:

Received 25-04-2022

Accepted 19-05-2022

Available online 04-06-2022

Keywords:

Unilateral crossbite

Modified transpalatal arch

Premolar correction

ABSTRACT

Objective: Trans palatal Arch is commonly used as an anchorage device for maintaining the position of molars in the maxillary arch. The constriction of premolars and canines could be corrected with appliances which can be fixed or removable.

Results: The correction was observed within 3 weeks.

Conclusion: The modified Trans palatal Arch is easy to fabricate and gives better treatment outcome in a short span. In this present article we have explained the modification of Trans palatal Arch for unilateral correction of cross bite.

This is an Open Access (OA) journal, and articles are distributed under the terms of the [Creative Commons Attribution-NonCommercial 4.0 International](https://creativecommons.org/licenses/by-nc/4.0/), which allows others to remix, and build upon the work non-commercially, as long as appropriate credit is given and the new creations are licensed under the identical terms.

For reprints contact: reprint@ipinnovative.com

1. Introduction

Crossbite is a frequently encountered malocclusion in an orthodontic practice. Posterior crossbite can be unilateral or bilateral with predominance for unilateral crossbite. Unilateral crossbite involves single or multiple maxillary teeth positioned lingually with respect to the buccal cusp of the mandibular teeth on one side. In maximum cases, the interarch width between the maxillary and mandibular dentition is relied upon the narrow width of the maxillary dentition. Such cases require expansion oriented treatment plan. The expansion of the arch is possible with fixed orthodontic appliances as well as removable appliances depending upon the treatment need. In true unilateral posterior crossbite, selected teeth are corrected to eliminate the maxillary arch constriction.

Transpalatal Arch (TPA) has been used in orthodontics as

an adjunct for the correction of rotated molars, as an anchorage unit, vertical molar control, molar expansion.^{1,2}

Modification of TPA has been a budget friendly resource for various dental corrections during an orthodontic treatment.³

2. Material and Methods

A removable TPA was fabricated with 0.032" stainless steel wire on the patient's working cast. A helix with a diameter of 3–4 mm was constructed in front of the palatal sheath stub with an extended arm upto the affected teeth i.e premolar on the crossbite side (Figure 2).

The activation was done with a bird beak by opening the helix and cross checked on the working cast prior insertion. Once the molar bands were cemented, the appliance could be readily inserted into the palatal sheath stubs. The fixed orthodontic treatment could be carried out simultaneously. The patient could be recalled for the assessment of the treatment outcome in 3–4 weeks. Clinical evaluation for crossbite correction could be checked upon regular orthodontic visits and re activation could be done if required by removing the appliance and then can be religated. The appliance could work as a regular TPA for molar anchorage once the required correction has been achieved.

* Corresponding author.

E-mail address: madhulika.310@gmail.com (M. Gupta).

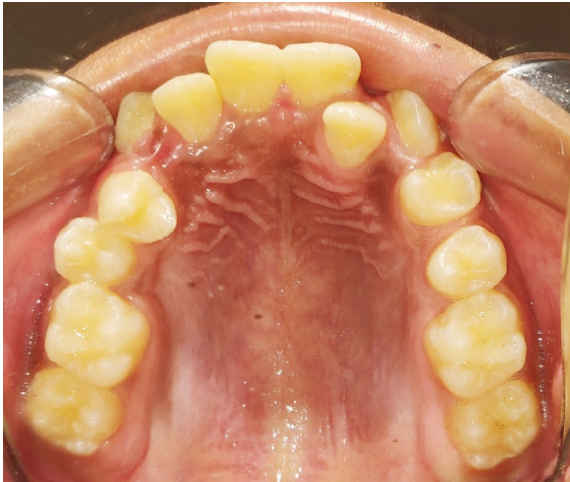

Figure 1: Pre treatment

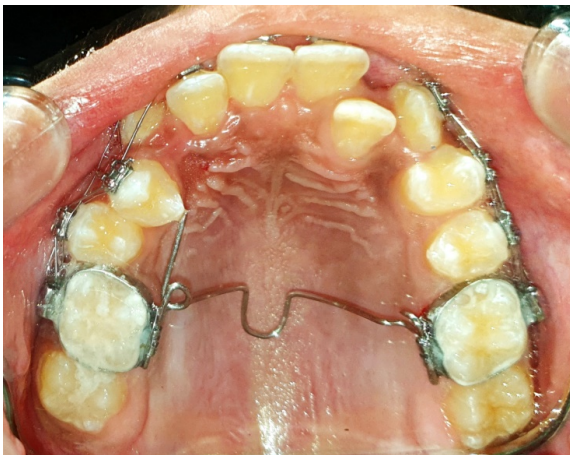

Figure 2: Modified transpalatal arch inserted with first maxillary wire.

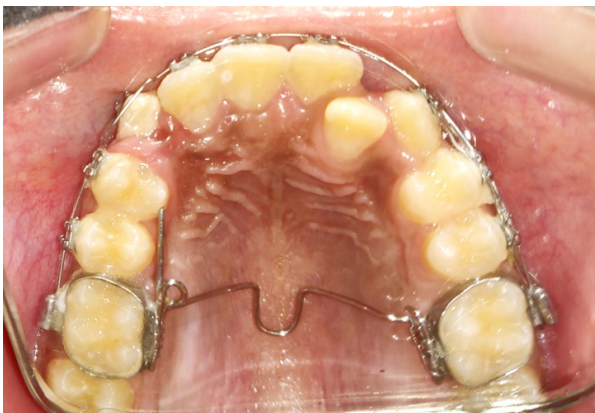

Figure 3: Progress after 3 weeks

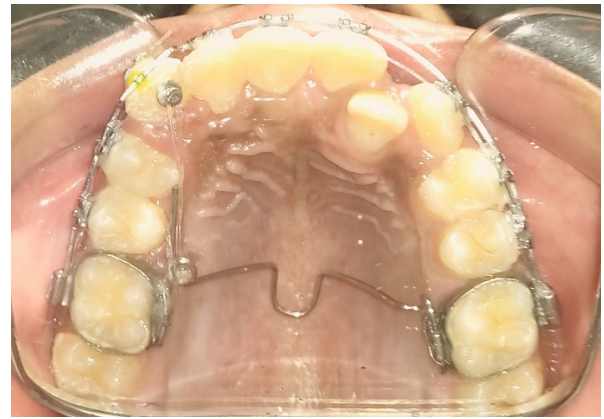


Figure 4: After 2 months

3. Case Report

The following case report highlights the advantage of the appliance for the correction of unilateral posterior crossbite in the pre molar region. A 13 year old male patient reported with a chief complaint of irregularly placed teeth in upper arch. Upon the second orthodontic visit (Figure 3) maximum correction was observed and the appliance was left in the arch as a maxillary anchorage unit like the regular TPA.

4. Results

Maximum rotational and alignment corrections were seen on the patients second visit after placement of the appliance. The correction was observed within 3 weeks. Treatment progress could be seen in Figures 3 and 4.

5. Discussion

Transpalatal arch has been considered effective for conservation of anchorage from time to time and various innovations have made it an appliance for multiple use. TPA for derotation of molars has been widely used whereas in cases where absolute anchorage is considered, TPA has not been advised. Simultaneous expansion and correction of unilateral crossbite could be easily practiced by this modified TPA and it could be significant for regular use as it reduces patient discomfort.

6. Conclusion

Advantages for this modified TPA are:

1. Economical and easy to fabricate
2. Easy chair side fabrication
3. Patient friendly
4. Easy to remove and ligate
5. Post correction the appliance could work as a regular TPA

7. Source of Funding

None.


8. Conflict of Interest

None.

References

1. Wise JB, Magness WB, Powers JM. Maxillary molar vertical control with the use of transpalatal arches. *Am J Orthod Dentofac Orthop.* 1994;106(4):403–11. doi:10.1016/S0889-5406(94)70062-1.
2. Tsibel G, Kufnec MM. A bonded transpalatal arch. *J Clin orthod.* 2004;38(9):513–5.
3. Thomas A, Afshan T, Deru T. Modification of transpalatal arch for expansion. *J Indian Orthod Soc.* 2017;51(4):289–90. doi:10.4103/0301-5742.216644.

Author biography

Madhulika Gupta, Post Graduate Student  <https://orcid.org/0000-0003-1777-7724>

Aftab Azam, Professor

Ashish Chauhan, Reader

Ragni Tandon, Professor and Head

Mrinalini Bansal, Post Graduate Student

Cite this article: Gupta M, Azam A, Chauhan A, Tandon R, Bansal M. Transpalatal arch modification for posterior unilateral crossbite correction. *J Contemp Orthod* 2022;6(2):91-93.