



## Case Series

## Distalization, A unique weapon in an orthodontist's armoury: A case series

Ashish Kamboj<sup>1\*</sup>, S. S. Chopra<sup>2</sup>, Atul Bali<sup>3</sup>, Mohit Sharma<sup>3</sup>, Prateek Mathur<sup>4</sup>, Paras Angrish<sup>3</sup>

<sup>1</sup>Government Dental Centre, Leh, (UT of Ladakh), India

<sup>2</sup>Army Dental Centre, Delhi Cantt, India

<sup>3</sup>Army Dental Corps, India

<sup>4</sup>Government Dental Centre, Pathankot, Punjab, India



## ARTICLE INFO

## Article history:

Received 18-12-2022

Accepted 12-01-2023

Available online 29-03-2023

## Keywords:

Distalization

Pendulum Appliance

Gaining space

## ABSTRACT

Distalization is widely used as an effective method of gaining space with or without the need of extractions. Various Extra-oral and intra-oral appliances have been introduced over the years. The pendulum appliance and its modifications are specifically very popular among clinicians owing to their effectiveness. The present case series comprises of two cases that have been effectively treated using the pendulum appliance ensuing in aesthetically pleasing outcomes.

This is an Open Access (OA) journal, and articles are distributed under the terms of the [Creative Commons Attribution-NonCommercial 4.0 International](https://creativecommons.org/licenses/by-nc/4.0/), which allows others to remix, and build upon the work non-commercially, as long as appropriate credit is given and the new creations are licensed under the identical terms.

For reprints contact: [reprint@ipinnovative.com](mailto:reprint@ipinnovative.com)

## 1. Introduction

Distalization is a well-documented technique employed to increase arch length. It is a conservative method of gaining space without sacrificing the dental units.<sup>1</sup> The process of molar distalization has been in practice for over a century and has evolved leaps and bound ever since. Numerous methods have been proposed over the years using both intra-oral and extra-oral appliances.<sup>2,3</sup>

Traditionally, headgears were used as an extra-oral method of molar distalization. Though effective, headgears are highly dependent on patient compliance and therefore, intra-oral fixed appliances gained popularity. One such appliance that is widely used even today is known as the Pendulum appliance introduced by Hilgers in the year 1992.<sup>4,5</sup> Anchorage planning and appliance design are the keys to a successful treatment outcome using the appliance. Certain adverse effects such as distal tipping of molars, an undesired increase in lower anterior facial height

and mandibular clockwise rotation have been reported in literature.<sup>6</sup>

Temporary anchorage devices (TADs) have revolutionised the way anchorage is managed in contemporary orthodontics. TADs have been utilised in distalization as well and literature has suggested effective distalization with minimal tipping using the same. However, recent systematic reviews suggest that effective distalization can be achieved with both conventional and TAD mechanics without much clinically significant differences.<sup>7</sup> TADs have certain disadvantages like screw failures, approximation to root surfaces and associated pain.<sup>8</sup> Thus, TADs may be specifically employed in critical anchorage cases.

The present article describes two such cases which have been effectively treated using the conventional pendulum appliance with TADs along with aesthetically pleasing outcomes.

\* Corresponding author.

E-mail address: [aashishkamboj@gmail.com](mailto:aashishkamboj@gmail.com) (A. Kamboj).

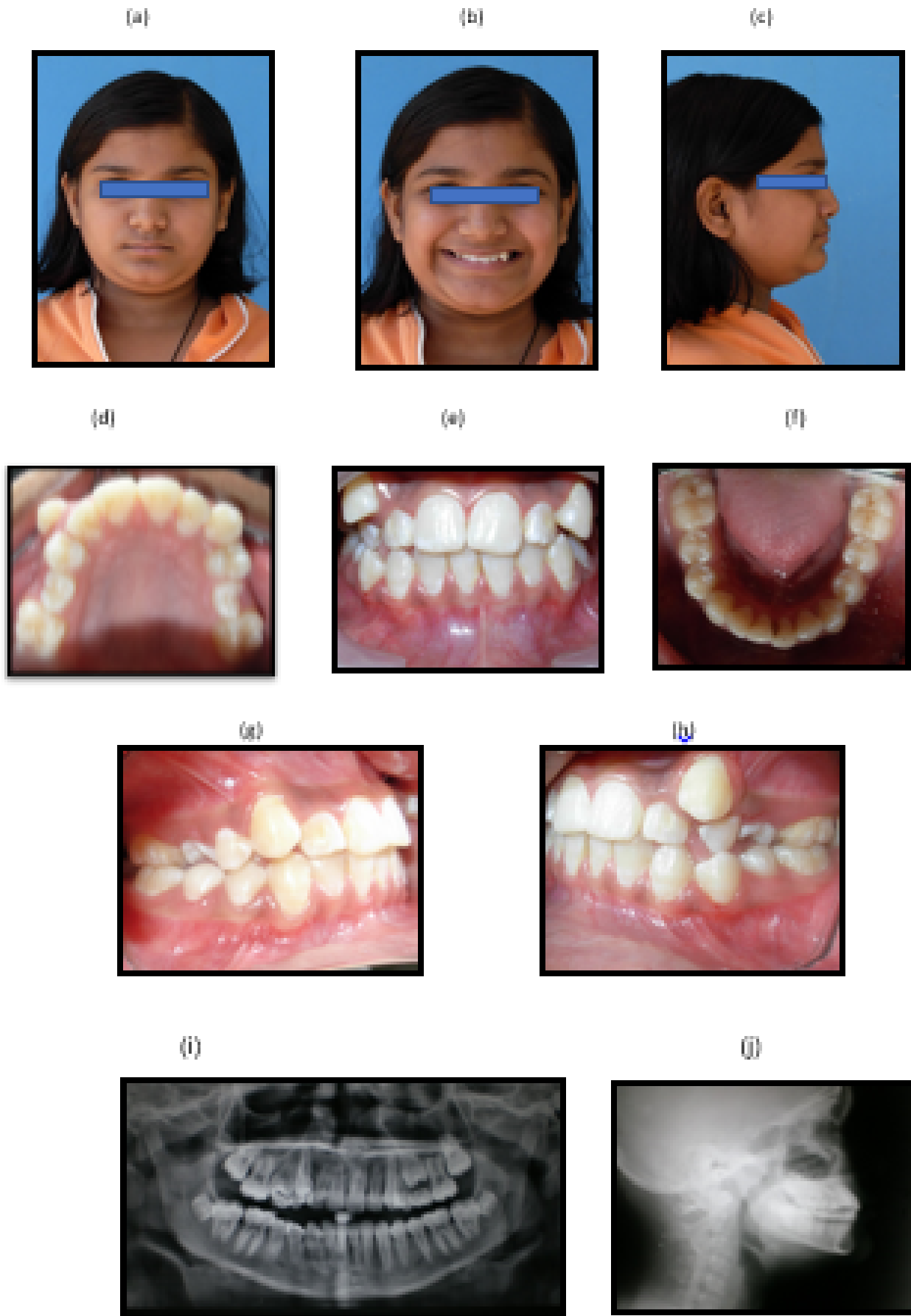


Figure 1: Pr-treatment records case-1

**2. Case 1**

A 11 years old female patient reported to a tertiary care dental centre with the chief complaint of Irregular upper front teeth. The patient started noticing the problem since the eruption of permanent teeth and desired correction of the same. The medical and dental history of the patient was non-contributory. The growth history revealed that the patient had not achieved menarche.

**2.1. Clinical examination**

1. *Extra Oral:* Patient’s face was proportional in the horizontal fifths and vertical thirds. The patient had a non-consonant smile arc and wide buccal corridors. The profile was straight with a deep mentolabial sulcus and an obtuse chin-throat angle. [Figure 1 (a-c).
2. *Intra Oral:* Intra oral examination revealed severe crowding in the upper arch, rotated 15 and 25, blocked out 13, labially displaced 23, upper midline deviated to right by 2 mm, mild lower arch crowding end on molar relation and a non-specific canine relation. (Figure 1 d-h).

**2.2. Radiographic assessment**

1. *Orthopantomogram:* revealed permanent dentition with the 3<sup>rd</sup> molars in various stages of eruption. No abnormality was detected. (Figure 1 i)
2. *Lateral Cephalogram:* revealed mild class III skeletal bases with an average growth pattern. Proclination of the maxillary anteriors and a normal lower anterior facial height. Adequate molar-Ptv value (Table 1 & Figure 1 j).

**Table 1:**

Parameter	Value
SNA	77
SNB	80
ANB	-3
Upper 1 to NA	35° (9mm)
Lower 1 to NB	28° (4mm)
LAFH: AFH	54.4%
Molar-Ptv	16mm

**2.3. Problem list**

Based on the clinical examination and radiographic assessment the following problem list was formulated:

1. Straight profile
2. Deep mentolabial sulcus
3. Severe crowding upper arch

4. Rotated 15 and 25
5. Blocked out 13
6. Labially displaced 23
7. Upper midline deviated to right by 2 mm
8. Molar relation end on and non-specific canine relation

**2.4. Treatment objectives**

1. Improvement of profile.
2. To improve smile aesthetics
3. Leveling and alignment of teeth.
4. Correction of midline
5. Achieve class I molar and canine relation bilaterally
6. Establishment of adequate overjet and overbite

**2.5. Treatment plan**

1. *Phase I:* Molar distalization with pendulum appliance. To achieve super class I relationship and correction of premolar rotation. TADs to retain molar correction.
2. *Phase II:* Leveling and alignment of arches and retraction of buccal segments into the space created. Bring canines into arch.

**2.6. Treatment progress**

Molar distalization using the pendulum appliance [Figure 2 (a-b)]. Distalization was achieved in four months and E chains were employed for derotation of premolars [Figure 2 (c & d)]

Bonding was done using 0.022” MBT pre-adjusted edgewise appliance and levelling and alignment was carried out [Figure 2 (e & f)].

**2.7. Post treatment status**

1. At the end of treatment all objectives which included an aesthetically pleasing smile along with correction of canine and molar relations were achieved.[Figure 3 (a-h)].
2. Radiographic comparison revealed an improvement in inclination of the maxillary anteriors [Figure 3 (i-j)].

**Table 2:**

Parameter	Pre-Treatment Value	Post-Treatment Value
SNA	77	79
SNB	80	81
ANB	-3	-2
Upper 1 to NA	35° (9mm)	28° (4mm)
Lower 1 to NB	28° (4mm)	20° (4mm)
LAFH: AFH	54.4%	55.2%
AFH		

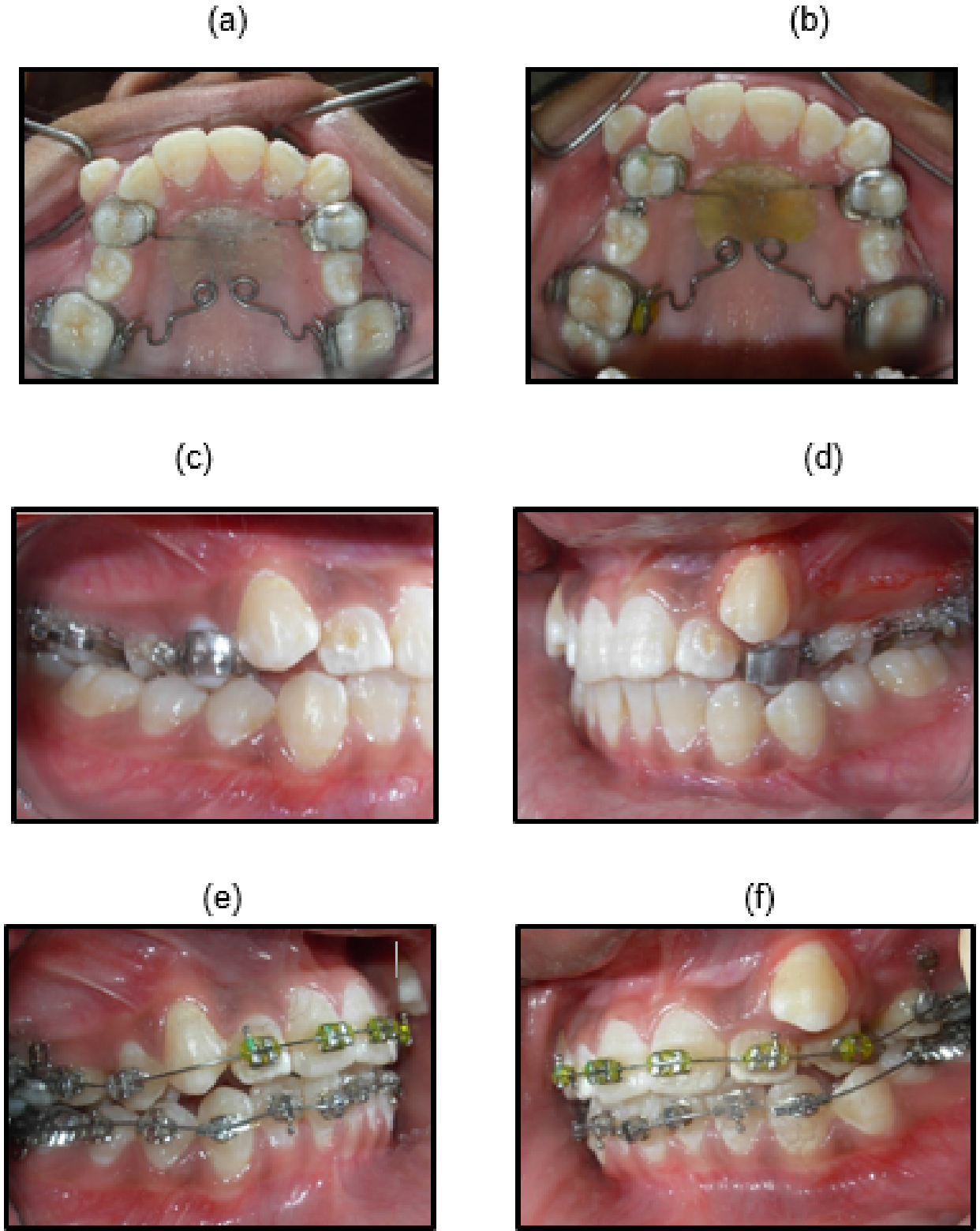


Figure 2: Treatment progress case-1

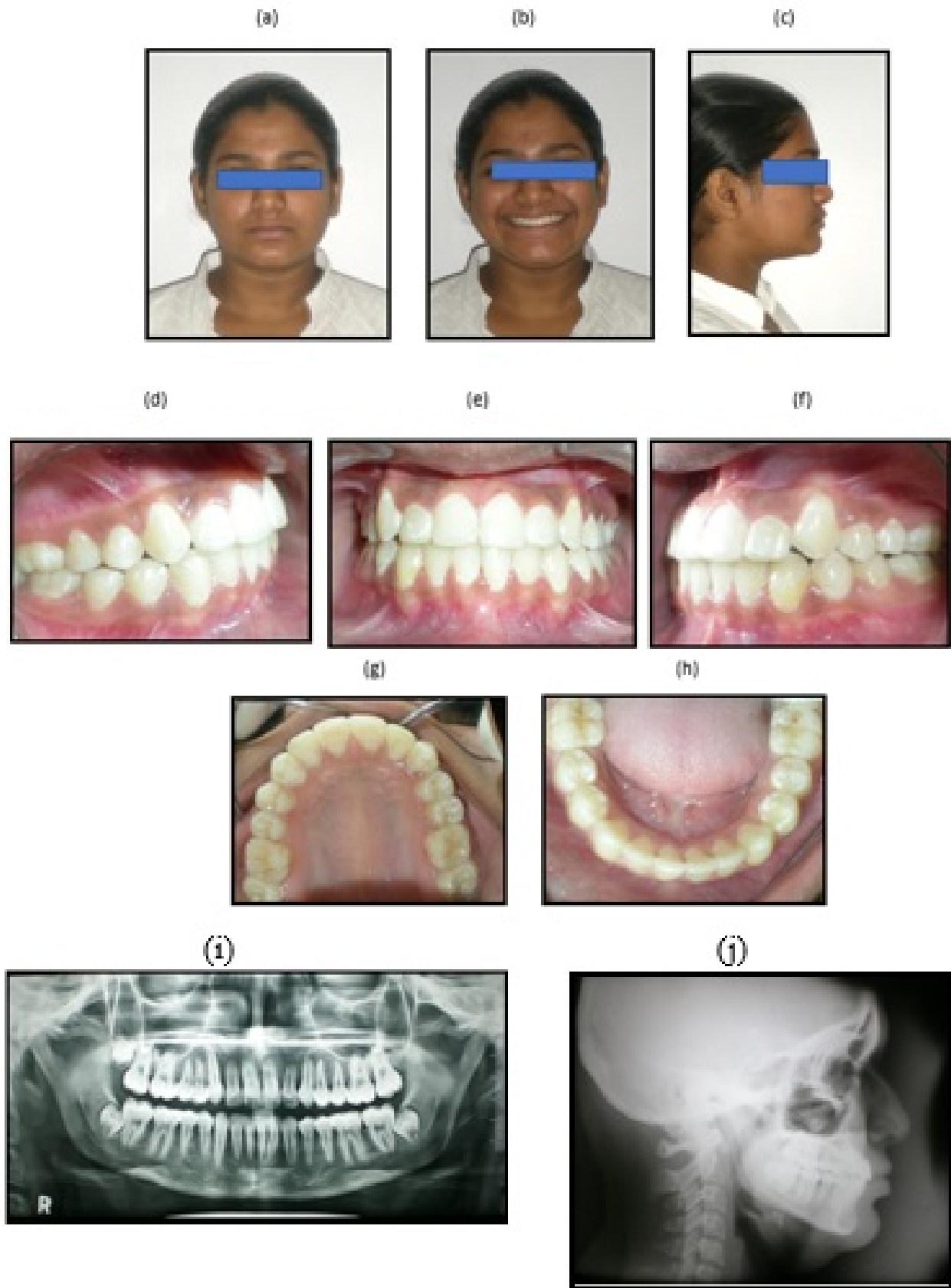


Figure 3: Post-treatment records case-1

### 3. Case 2

A 19 years old female patient reported to a tertiary care dental centre with the chief complaint of Irregular upper front teeth. The medical and dental history of the patient was non-contributory.

#### 3.1. Clinical examination

1. *Extra Oral:* Patient's face was proportional in the horizontal fifths and vertical thirds. The patient had a non-consonant smile arc and wide buccal corridors. The profile was convex with an increased nasolabial angle. [Figure 4 (a-c)]
2. *Intra Oral:* Intra oral examination revealed moderate crowding in the maxillary arch, mild crowding in the mandibular arch and end on molar and canine relations on the left and class II on the right side. (Figure 4 (d-h)).

**Table 3:**

Parameter	Value
SNA	83
SNB	80
ANB	3
Upper 1 to NA	27° (6mm)
Lower 1 to NB	27° (5mm)
LAFH: AFH	56.2%
Molar-Ptv	17 mm

**Table 4:**

Parameter	Pre-Treatment Value	Post-Treatment Value
SNA	83	82
SNB	80	80
ANB	3	2
Upper 1 to NA	27° (6mm)	20° (4mm)
Lower 1 to NB	27° (5mm)	31° (6mm)
LAFH: AFH	56.2%	57%

#### 3.2. Radiographic assessment

1. Orthopantomogram: revealed permanent dentition with the 3rd molars in various stages of eruption. Missing 38. No other abnormality was detected.[Figure 4 i].

2.Lateral Cephalogram: revealed class I skeletal bases with an average growth pattern. Proclination of the maxillary anteriors and a normal lower anterior facial

height. (Table 3 &Figure 4 j)

#### 3.3. Problem list

Based on the clinical examination and radiographic assessment the following problem list was formulated:

1. Moderate crowding upper anteriors.
2. End on molar right side class II on left.
3. End on canine right side Class II on left.

#### 3.4. Treatment objectives

1. To improve smile aesthetics.
2. Leveling and alignment of teeth.
3. Achieve class I molar and canine relation bilaterally.
4. Establishment of adequate over jet and overbite.

#### 3.5. Treatment plan

1. Therapeutic extraction of 17 and 27.
2. Space gain in maxillary arch by bilateral molar distalisation.
3. Sequential canine and premolar retraction.
4. Leveling and alignment of arches and correction of rotations.

#### 3.6. Treatment progress

Bonding was done using 0.022" MBT pre-adjusted edgewise appliance and levelling and alignment was carried out [Figure 5 d-f].

### 4. Conclusion

Distalization is one of the most widely accepted modalities of gaining space. Case selection is vital in such cases as distalization may affect the lower anterior facial height adversely. A thorough clinical and radiographic assessment form the basic tenets of a successful treatment outcome. The intra-oral appliances are used popularly as these do not require patient compliance. With the recent advances in technology numerous distalization appliances have been introduced over the years.<sup>9</sup> However, the conventional appliances still remain as effective when utilized in the correct way and modified as per the specific requirement of

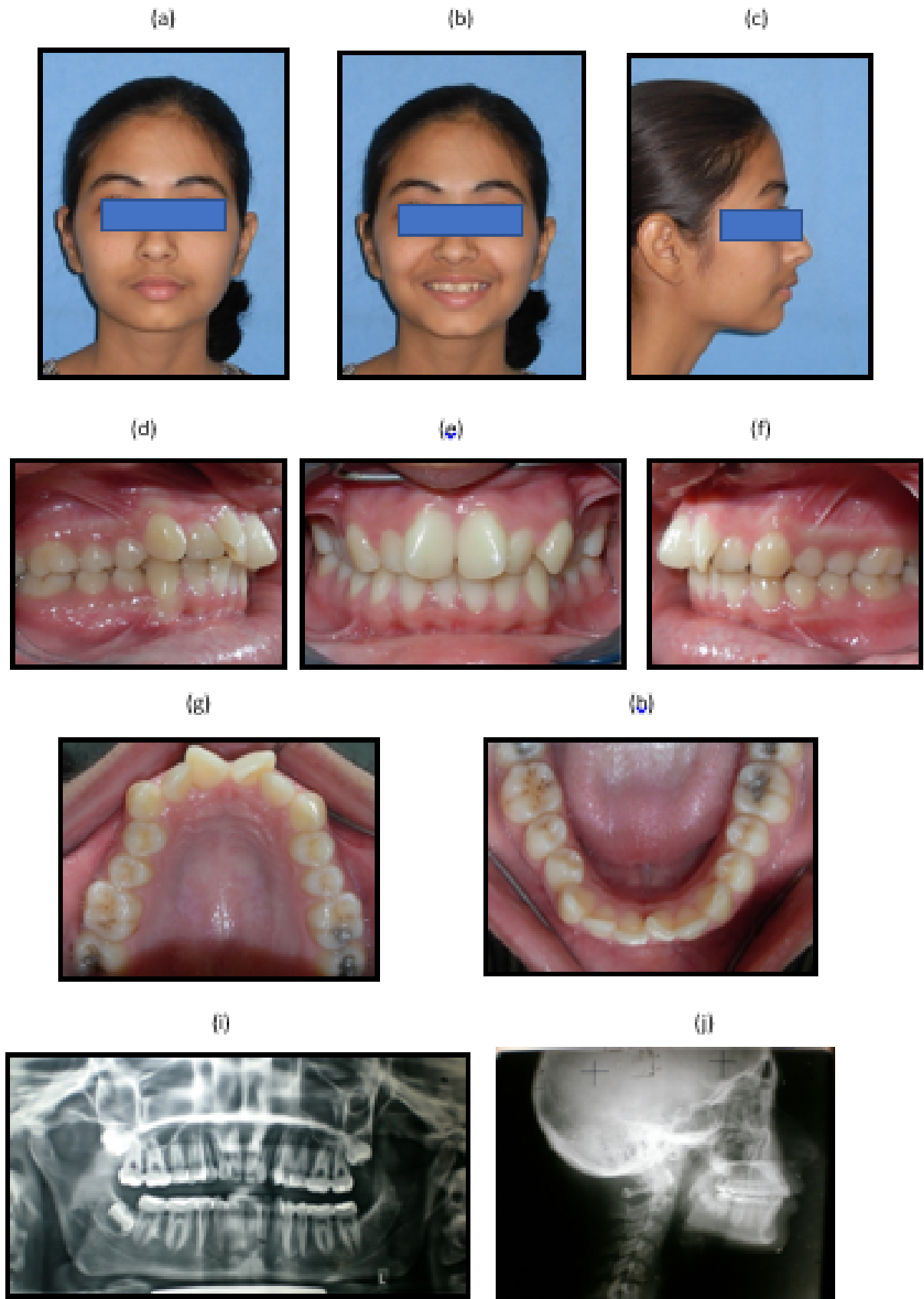


Figure 4: Pre-treatment records case-2

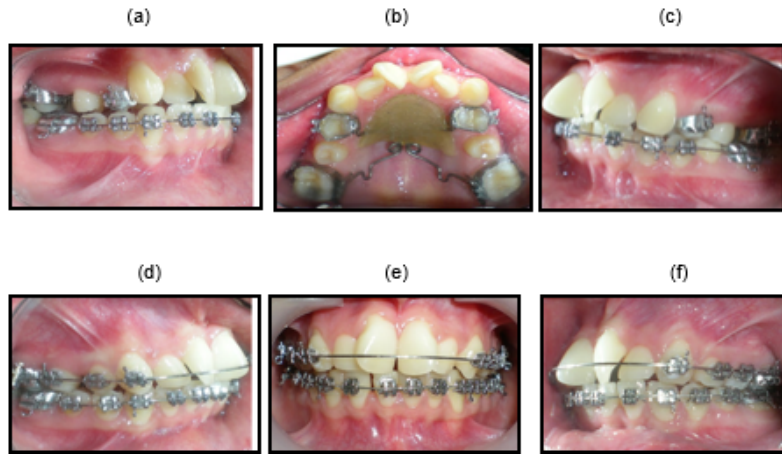


Figure 5: Treatment progress case-2

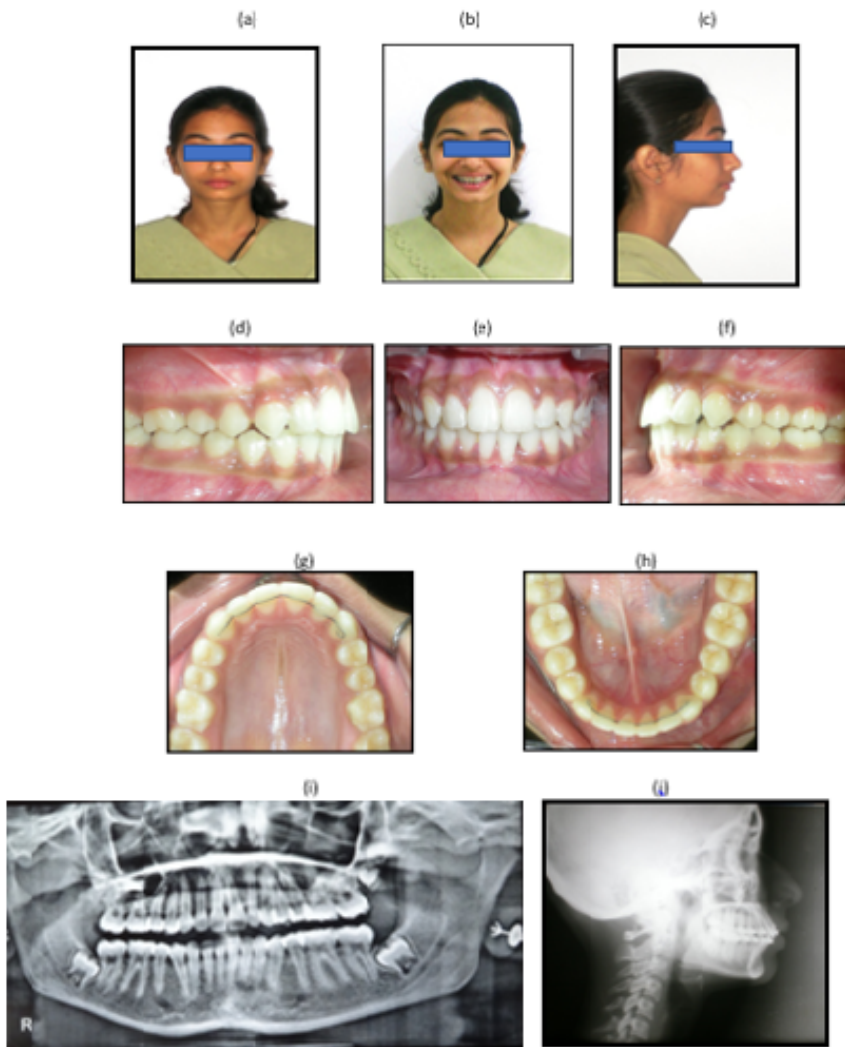


Figure 6: Post-treatment records case-2



a particular case.

## 5. Source of Funding

None.


## 6. Conflict of Interest

None.

## References

1. Proffit WR, Fields HW, Larson BE, Sarver DM. Contemporary Orthodontics. 6th ed. Philadelphia: Elsevier; 2019. p. 462–3.
2. Haas AJ. Headgear therapy: the most efficient way to distalize molars. *Semin Orthod.* 2000;6(2):79–90.
3. Fontana M, Cozzani M, Caprioglio A. Noncompliance maxillary molar distalizing appliances: an overview of the last decade. *Prog Orthod.* 2012;13(2):173–84.
4. Cambiano AO, Janson G, Fuziy A, Garib DG, Lorenzoni DC. Changes consequent to maxillary molar distalization with the bone-anchored pendulum appliance. *J Orthod Sci.* 2017;6(4):141–6.
5. Hilgers J. The pendulum appliance: an update. *Clin Impressions.* 1993;61(2):15–7.
6. Caprioglio A, Fontana M, Longoni E, Cozzani M. Long-term evaluation of the molar movements following Pendulum and fixed appliances. *Angle Orthod.* 2013;83(3):447–54.
7. Soheilifar S. Maxillary molar distalization using conventional versus skeletal anchorage devices: A systematic review and meta-analysis. *Int Orthod.* 2019;17(3):415–24.
8. Cozzani M, Fontana M, Maino G, Maino G, Palpacelli L, Caprioglio A. Comparison between direct vs. indirect anchorage in two miniscrew-supported distalizing devices. *Angle Orthod.* 2016;86(3):399–406.
9. Antonarakis GS, Kiliaridis S. Maxillary molar distalization with noncompliance intramaxillary appliances in class II malocclusion: a systematic review. *Angle Orthod.* 2008;78(6):1133–40.

## Author biography

**Ashish Kamboj**, Orthodontist  <https://orcid.org/0000-0002-1836-6786>

**S. S. Chopra**, Professor and HOD

**Atul Bali**, Orthodontist

**Mohit Sharma**, Orthodontist

**Prateek Mathur**, Orthodontist

**Paras Angrish**, Pedodontist

**Cite this article:** Kamboj A, Chopra SS, Bali A, Sharma M, Mathur P, Angrish P. Distalization, A unique weapon in an orthodontist's armoury: A case series. *J Contemp Orthod* 2023;7(1):61-69.