



## Original Research Article

# Is PowerScope™ 2 an effective Class II corrector ? A prospective cephalometric study

Dhruv Jain<sup>1\*</sup>, Sanjeev Datana<sup>2</sup>, Sukhbir Singh Chopra<sup>1</sup>

<sup>1</sup>Dept. of Orthodontics & Dentofacial Orthopedics, Army Dental Centre (Research & Referral), New Delhi, India

<sup>2</sup>Dept. of Orthodontics & Dentofacial Orthopedics, Armed Forces Medical College, Pune, Maharashtra, India



## ARTICLE INFO

## Article history:

Received 13-01-2023

Accepted 11-04-2023

Available online 16-06-2023

## Keywords:

Skeletal Class II malocclusion

Fixed functional appliance

PowerScope™ 2

Cephalometrics

## ABSTRACT

**Objectives:** The study was carried out to evaluate skeletal, dental and soft tissue effects produced by PowerScope™ 2 appliance following the correction of skeletal Class II malocclusion.

**Materials and Methods:** A total of 10 patients (3 males and 7 females with mean age of  $14.40 \pm 0.70$  yrs) diagnosed with skeletal Class II malocclusion and indicated for fixed functional appliance were treated using Power Scope™ 2 appliance. Paired t-test was used to assess skeletal, dental and soft tissue changes evaluated on lateral cephalograms taken at pre-functional (T1) and post-functional (T2) stages.

**Results:** Maxillomandibular sagittal relation was markedly improved with a significant gain in the length of the mandible along with a restraining effect on the maxillary dentition. The improvement in molar relation was mainly contributed by dentoalveolar effects (72.3 %) and secondarily by skeletal effects (27.7 %) while the reduction in overjet was contributed by 22.4% skeletal and 77.6% dental effects. Vertical changes were non-significant. Following PowerScope™ 2 therapy there was an overall improvement in facial esthetics.

**Conclusion:** Power Scope™ 2 serves as an effective skeletal Class II corrector with primarily dentoalveolar and secondary skeletal effects.

This is an Open Access (OA) journal, and articles are distributed under the terms of the [Creative Commons Attribution-NonCommercial 4.0 International](https://creativecommons.org/licenses/by-nc/4.0/), which allows others to remix, and build upon the work non-commercially, as long as appropriate credit is given and the new creations are licensed under the identical terms.

For reprints contact: [reprint@ipinnovative.com](mailto:reprint@ipinnovative.com)

## 1. Introduction

Class II malocclusion is a common dentofacial deformity, among Caucasians, the prevalence being estimated to be 23% in permanent dentition and 26% in mixed dentition,<sup>1</sup> 21.5% in boys and 19.8% in girls in the Indian school-going population.<sup>2</sup> Among various combinations, mandibular retrusion has been considered as the single most common characteristic of Class II malocclusion.<sup>3</sup>

Among growing patients, mandibular advancement can be carried out with numerous functional appliances however patient compliance poses a great challenge to an orthodontist thereby affecting treatment outcome.<sup>4</sup> To reduce the dependency on patient compliance along

with enhancement in patient comfort and treatment satisfaction, various modifications have been made in existing appliance designs as well as techniques which have led to the introduction of newer fixed functional appliances (FFA) that have gained massive popularity in recent years with their better results in non-compliant patients. PowerScope™ (American Orthodontics, Sheboygan Wis) introduced by Dr Andy Hayes in conjunction with American Orthodontics is one such addition to the orthodontist's armamentarium.<sup>5</sup>

A plethora of literature exists regarding the treatment effects of various FFA however, there have been limited studies which have evaluated the dentoskeletal changes brought about by the recently introduced latest generation PowerScope™ 2 appliance. Hence, the present study was carried out to provide comprehensive data regarding

\* Corresponding author.

E-mail address: [drdhruvjain08@gmail.com](mailto:drdhruvjain08@gmail.com) (D. Jain).

skeletal, dental and soft tissue effects produced by PowerScope™ 2 appliance following the correction of skeletal Class II malocclusion

The null hypothesis for the study was “There are no changes in the skeletal, dental and soft tissue parameters following treatment of skeletal Class II malocclusion with PowerScope™ 2 fixed functional appliance”.

## 2. Materials and Methods

This prospective study was conducted at the Department of Orthodontics and Dentofacial Orthopaedics of a tertiary care government hospital following ethical clearance obtained by the Institutional Ethical Committee (IEC/Oct/2019). Inclusion criteria were (a) Patients with mandibular hypoplasia as a cause of skeletal Class II malocclusion (ANB >4 degrees), (b) Molar relation Class II/Half cusp Class II, (c) Overjet > 4mm (c) Positive VTO (d) CVMI stage 3-5 (e) Minimal crowding (< 3mm). Exclusion criteria comprised of (a) History of previous orthodontic treatment/trauma to jawbones/ systemic diseases affecting bone metabolism (b) Patients with neuromuscular disorders or TMJ pathology (c) Syndromic cases including patients with cleft lip and palate (d) Facial asymmetry.

Standard orthodontic treatment records were made before the initiation of treatment (T0) (Figure 1). The lateral cephalogram and orthopantomogram (OPG) were taken using a radiographic machine manufactured by M/s Planmeca Oy Finland, Model- Planmeca Proline XC unit.

A customized treatment plan was formulated for each patient, and fixed mechanotherapy was initiated using a 0.022” MBT pre-adjusted edgewise appliance (OSL signature MBT 0.022” metal bracket, United Kingdom). The archwire sequence used for leveling and alignment was 0.016” NiTi, 0.016”x0.022” NiTi, 0.016”x0.022” SS, 0.017”x0.025” SS, and 0.019”x0.025” SS. Archwire was cinched distal to the second molar tubes and to prevent buccal inclination of the mandibular anterior an additional torque of 5° was incorporated. After levelling and alignment and before initiation of FFA, pre-functional records (T1) were taken following which PowerScope™ 2 appliance was installed exerting a forward thrust of 260 gm to reposition the mandible anteriorly. The patients were subsequently recalled at 4 weeks intervals for the evaluation of treatment effects and appliance activation (if required). The functional phase continued for a mean duration of 6 months until a well-balanced soft tissue profile of the patient was achieved along with unstrained Class I molar and Class I canine relation bilaterally.

On completion of the functional phase, post-functional treatment records (T2) were taken (Figure 2) and PowerScope™ 2 appliance was gently removed. Finishing and detailing was carried out to settle the occlusion following which fixed appliance was debonded and post-

treatment records were obtained (Figure 3).

### 2.1. Sample size calculation

The sample size was calculated for hypothesis testing with 95% level of significance and 80% power for the evaluation of skeletal, dental and soft tissue parameters. The required sample size obtained was 09 however, a minimum of 10 patients were enrolled in the study to cater for the dropouts and to achieve a significant clinical decision to test the null hypothesis.

## 3. Statistical Analysis

The data was statistically analyzed using Statistical Package for Social Sciences (SPSS ver 22.0, IBM Corporation, USA) for Microsoft Windows. The statistical significance paired data (pre-functional vs post-functional) was tested using paired t-test. The underlying normality assumption was tested before subjecting the study variables to t-test. All the hypotheses were formulated using two-tailed alternatives against each null hypothesis. To ascertain intra and inter-operator bias three randomly selected studied parameters (SNA, U1-SN, STFA) were reassessed after one week by the same and another trained operator. The intra-class correlation coefficient (ICC) for the parameters i.e., SNA, U1-SN and STFA had significantly higher values of 0.950, 0.917 and 0.913 respectively (P-value > 0.05 for all) indicating statistically significant Intra and Inter-observer agreement.

## 4. Results

Skeletal parameters i.e., SNA, A-Na Vert, SNB, Pog-Na Vert, Co-Gn, ANB, Maxillo-mandibular differential (M-M D), WITS, SN-GoGn, AFH differ significantly at T2 (P-value < 0.05 for all) while other skeletal parameters such as Co-A, PFH and J-ratio did not differ significantly at T2 (P-value > 0.05 for all) (Figure 4, Table 1). Statistically significant changes at T2 were obtained for dental parameters i.e., U1-SN, U1-PTV, U1-PP, U6-PTV, U6-PP, IMPA, L1-PTV, L1-MP, L6-PTV, overjet and overbite (P-value < 0.05 for all). However, parameters such as L6-MP and U1-L1 angle did not differ significantly at T2 (Figure 5, Table 1). Soft tissue parameters i.e., STFA, NLA, UL-E line, LL-E line, Upper lip strain and inferior sulcus depth differ significantly at T2 compared to means of corresponding soft tissue parameters at T1 (P-value < 0.05 for all) (Figure 6. Table 1).

## 5. Discussion

Functional appliances have been documented to bring about Class II correction by a combination of orthopedic and dentoalveolar effects with 30-40 % and 60-70 % contribution respectively.<sup>6</sup> FFA results in downward and

Table 1: Cephalometric parameters studied and the changes brought by PowerScope™ 2 appliance

S. No	Parameters	T1 (Mean ± SD)	T2 (Mean ± SD)	D (T2 – T1)	% Change	P-value
<b>Skeletal parameters</b>						
1	SNA (degree)	82.0 ± 1.15	81.60 ± 1.35	- 0.40	0.49%	0.037*
2	A – Na Vert (mm)	0.50 ± 0.32	0.50 ± 0.53	- 0.40	44.44%	0.037*
3	Co-A (mm)	78.90 ± 3.93	78.90 ± 3.92	0.00	0.00%	0.999NS
4	SNB (degree)	75.90 ± 0.74	76.80 ± 0.79	0.90	1.19%	0.004**
5	Pog – Na Vert (mm)	-6.70 ± 0.67	-5.60 ± 0.84	1.10	16.07%	0.003**
6	Co-Gn (mm)	98.50 ± 4.19	99.70 ± 4.22	1.20	1.22%	0.003**
7	ANB (degree)	6.10 ± 1.10	4.80 ± 1.68	- 1.30	22.37%	0.006**
8	MMD (mm)	19.60 ± 1.96	20.80 ± 1.87	1.20	6.31**	0.003**
9	WITS (mm)	4.70 ± 0.82	3.60 ± 1.51	- 1.10	25.67%	0.003**
10	SN – GoGn (degree)	30.60 ± 0.97	30.90 ± 0.87	0.30	1.00%	0.049*
11	AFH (mm)	101.10 ± 2.96	101.60 ± 2.98	0.50	0.49%	0.015*
12	PFH (mm)	64.90 ± 2.51	65.10 ± 2.51	0.20	0.31%	0.168NS
13	J-ratio (%)	64.17 ± 1.07	64.05 ± 1.13	- 0.12	0.19%	0.309NS
<b>Dental parameters</b>						
1	U1 – SN (degree)	115.00 ± 4.03	108.60 ± 2.99	-6.40	5.54%	0.001***
2	U1 – PTV (mm)	52.90 ± 2.38	49.60 ± 2.12	-3.30	6.21%	0.001***
3	U1 – PP (mm)	25.50 ± 0.71	26.60 ± 1.07	1.10	4.40%	0.032*
4	U6 – PTV (mm)	26.90 ± 2.13	26.10 ± 2.38	-0.80	3.04%	0.001***
5	U6 – PP (mm)	18.90 ± 0.99	19.40 ± 1.07	0.50	2.67%	0.015*
6	IMPA (degree)	91.00 ± 2.16	100.20 ± 3.05	9.20	10.12%	0.001***
7	L1 – PTV (mm)	45.60 ± 1.71	49.00 ± 1.49	3.40	7.51%	0.001***
8	L1 – MP (mm)	35.80 ± 2.53	35.00 ± 2.36	-0.80	2.17%	0.037*
9	L6 – PTV (mm)	26.00 ± 2.83	30.60 ± 2.67	4.60	17.95%	0.001***
10	L6 – MP (mm)	28.20 ± 2.30	28.00 ± 2.45	-0.20	0.69%	0.509NS
11	U1 – L1 Angle (degree)	113.70 ± 10.50	118.00 ± 7.74	4.30	4.14%	0.059NS
12	Overjet (mm)	9.10 ± 1.66	2.60 ± 0.52	-6.50	70.82%	0.001***
13	Overbite (mm)	6.20 ± 0.63	2.60 ± 0.52	-3.60	58.14%	0.001***
<b>Soft tissue parameters</b>						
1	STFA (degree)	87.70 ± 1.16	88.60 ± 0.70	- 0.90	2.85%	0.004**
2	NLA (degree)	103.80 ± 6.61	107.40 ± 6.45	- 3.60	3.49%	0.001***
3	UL – E line (mm)	0.70 ± 0.82	-0.70 ± 1.06	- 1.40	110.00%	0.001***
4	LL – E line (mm)	-3.22 ± 0.97	-1.78 ± 0.83	1.44	46.11%	0.001***
5	Upper lip strain (mm)	3.44 ± 0.53	0.44 ± 0.53	- 3.00	87.04%	0.001***
6	Inferior sulcus depth (mm)	5.80 ± 1.03	3.30 ± 0.48	- 2.50	42.17%	0.001***

p-value&lt;0.05, \*statistically significant, p-value&lt;0.01, \*\*statistically moderate significant, p-value&lt;0.001, \*\*\*statistically highly significant

NS: statistically non significant

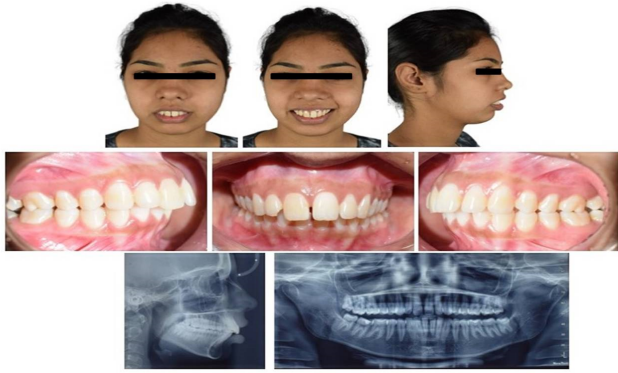


Figure 1: Pre treatment records

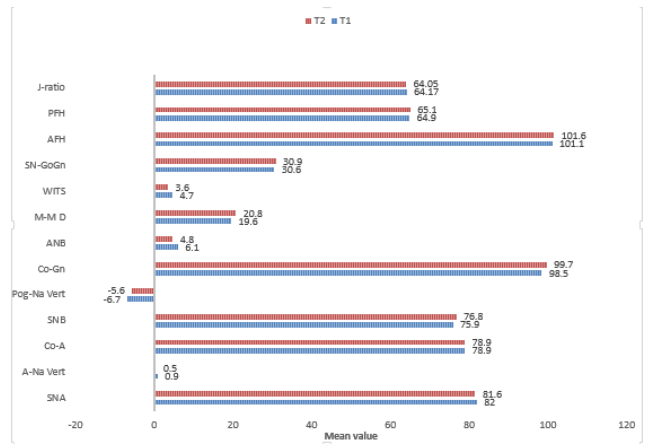


Figure 4: Distribution of mean skeletal cephalometric parameters studied

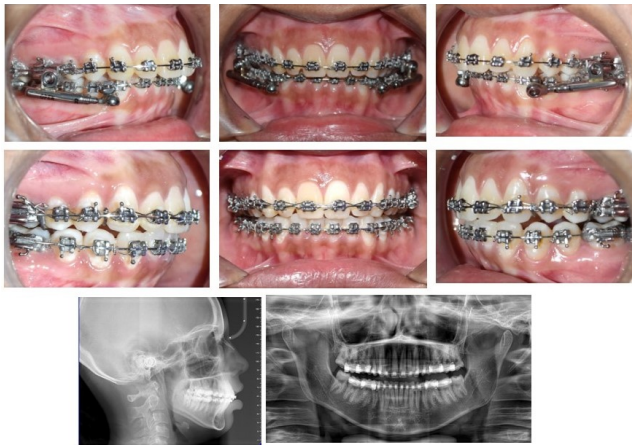


Figure 2: Power Scope™ 2 appliance insitu and post functional records

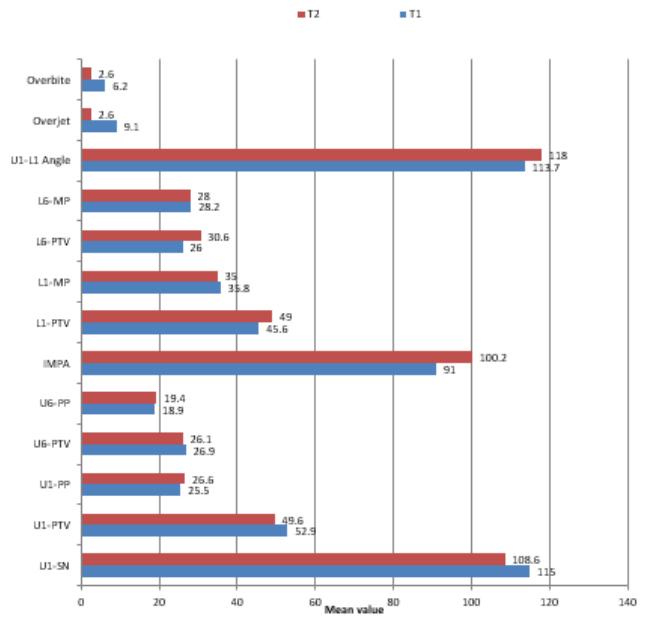


Figure 5: Distribution of mean dental cephalometric parameters studied

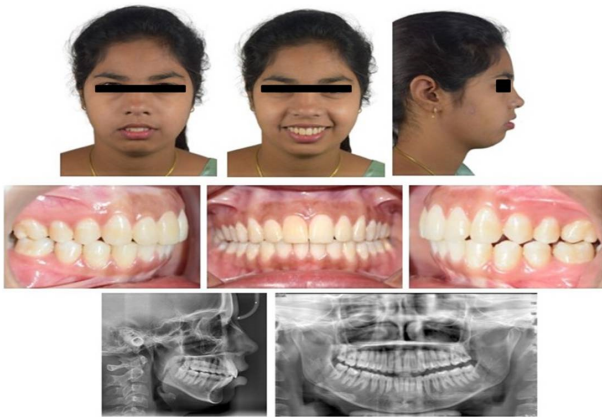

Figure 3: Post treatment records

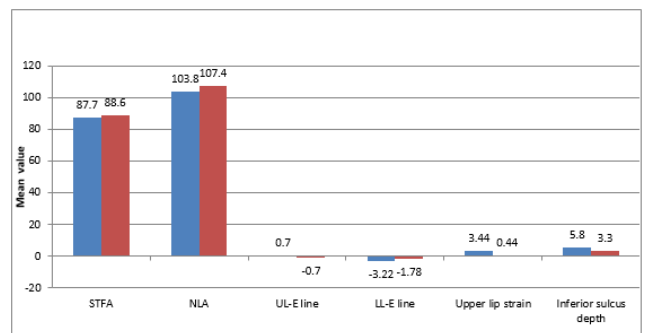
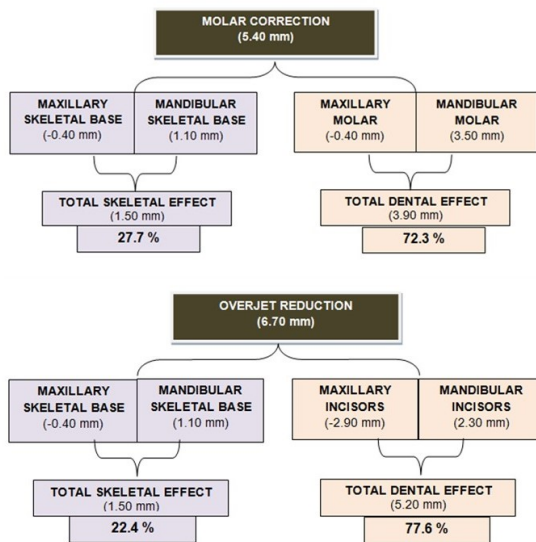


Figure 6: Distribution of mean soft tissue cephalometric parameters studied



**Figure 7:** Skeletal and dentoalveolar contribution in effecting molar relation and overjet correction

forward displacement of mandible along with posterior and superior displacement of pterygoid plate and maxillary dentition, known as “telescopic effect” or “headgear effect”. These effects are predominantly dentoalveolar in nature with forward and downward displacement of mandibular incisors being the most pronounced dentoalveolar effect followed by mandibular molar displacement.<sup>7</sup>

### 5.1. Skeletal changes

In the present study, maxillary skeletal base was distalized by 0.40 mm with a reduction in SNA of  $0.40^\circ$  expressing the restraining effect of PowerScope™ 2 on forward maxillary growth. Similar results were concluded by Zymperdikas et al.<sup>8</sup> and Perinetti et al.<sup>9</sup> The skeletal correction was mostly contributed by forward displacement of the mandible as evidenced by an increase in SNB ( $0.90^\circ$ ), reduction in Pog–Na Vert (1.10 mm) and increase in effective length of mandible (Co–Gn) by 1.20 mm which were statistically significant. Zymperdikas et al.<sup>8</sup> reported an increase in SNB angle of  $0.87^\circ$  while Perinetti et al.<sup>9</sup> reported supplementary mandibular elongation of 0.44 mm ( $-0.78$  to 1.66 mm) with FFA which was similar to the present study. Malhotra et al.<sup>10</sup> reported an increase in SNB angle of  $1.067^\circ$  with 1.6 mm increase in mandibular length which was statistically significant with PowerScope™ therapy supporting the results of the present study. Growth relativity hypothesis<sup>11</sup> could provide a scientific explanation for the above-obtained results, according to which the forward displacement of mandible causes stretching of posterior viscoelastic tissues (tendons of TMJ, fibrocapsule and retrodiscal tissue) between condyle and glenoid fossa

leading to bone remodeling and condylar growth. These findings are also supported by previous FEM studies which reported increased tensile stress in the posterior condylar region following mandibular.

### 5.2. Protraction<sup>7,12,13</sup>

The post-functional cephalometric measurements revealed favourable sagittal skeletal changes as revealed by the reduction in ANB angle ( $1.30^\circ$ ), increase in maxilla-mandibular differential (1.20 mm) and reduction in WITS (1.10 mm). All these changes were statistically significant. Class II correction was predominantly contributed by forward mandibular displacement with relatively less contribution from maxilla. Similar findings were also concluded by Zymperdikas et al.<sup>8</sup> and Malhotra et al.<sup>10</sup> who reported reduction in ANB angle of  $1.74^\circ$  and  $0.87^\circ$  respectively. These findings were also in agreement with the findings reported by Antony et al.<sup>14</sup>

There was statistically non-significant vertical change following PowerScope™ 2 therapy in the present study though there was a slight increase in AFH (0.50 mm) and SN – GoGn ( $0.30^\circ$ ) which could have been due to the distalization of maxillary molar causing a wedging effect. These results were in agreement with the findings reported by Antony et al.<sup>14</sup> as well as Malhotra et al.<sup>10</sup> who reported non-significant changes in mandibular plane angle of  $0.067^\circ$ .

### 5.3. Dental changes

PowerScope™2 appliance resulted in Class II correction mainly by dentoalveolar effects (Table 1) similar to other FFA.<sup>8,9</sup> The headgear effect resulted in distalization (0.8 mm) and intrusion (1.1 mm) of maxillary molar along with marked mesialization (4.60 mm) and extrusion (0.20 mm) of mandibular molar resulting in net molar correction by approximately 5.4 mm which was contributed by dentoalveolar changes (3.90 mm) primarily and skeletal effects (1.50 mm) to a lesser extent. Similar results were reported by previous studies as well.<sup>10,14</sup> In the present study the improvement in molar relation was mainly contributed by dental effects (72.3 %) and secondarily by skeletal effects (27.7 %) (Fig 7). A similar contribution was reported with other FFA as well. Pancherz<sup>15</sup> reported 43% and 57% molar correction with skeletal and dental effects respectively with Herbst appliance. Ruf et al<sup>16</sup> reported molar correction using Herbst appliance being contributed by 25% skeletal and 75% dental effects in young adults & 41% skeletal and 59% dental correction in early adolescents. Heinig et al.<sup>17</sup> reported 39% molar correction due to skeletal changes and 61% due to dental changes with Forsus appliance. Stromeyer et al.<sup>18</sup> reported molar correction by 7% skeletal and 93% dental effects using Eureka spring.

The FFA therapy also resulted in intrusion (0.80 mm) and proclination of mandibular incisors with an increase in IMPA by 9.2° with forward positioning by 3.40 mm. Maxillary incisors were retroclined and repositioned by 6.40° and 3.30 mm respectively along with extrusion of 1.10 mm. The overjet and overbite were decreased with a net reduction of 6.50 mm and 3.60 mm respectively. All these findings were statistically significant. The net reduction in overjet was contributed by 22.4% skeletal and 77.6% dental effects (Fig 7). Similar contribution in overjet reduction has been reported with other FFA as well.<sup>15–17</sup>

The proclination of mandibular incisor is an unwanted effect observed with PowerScope™ 2 appliance similar to other FFA despite the cinching of archwire distal to mandibular molar. This side effect could have been due to the telescopic mechanism of PowerScope 2 appliance which exerted a mesially directed force on mandibular anteriors. The incorporation of lingual torque in archwire as an additional preventive measure may reduce the tendency of lower incisors to flare out but cannot avoid it completely as the point of force application in mandibular anterior region is above the center of resistance of dentoalveolar unit. The use of negative torque brackets as well as anchorage reinforcement using microimplants has also been advocated with FFA to further limit this proclination.<sup>19,20</sup>

#### 5.4. Soft tissue changes

Following PowerScope™ 2 therapy there was an overall improvement in facial esthetics (Table 1). There was an increase in STFA which is related to the forward positioning of soft tissue pogonion in relation to hard tissue pogonion. The retrusion of upper lip as a result of palatal tipping of maxillary incisors led to a decrease in UL – E line as well as a significant increase in NLA. This further improved the upper lip strain. The lower lip protrusion was contributed by the proclination of mandibular incisors. A statistically significant reduction in inferior sulcus depth also contributed to the net improvement in facial esthetics. Similar favourable results on soft tissues secondary to dentoalveolar changes have been reported in previous studies.<sup>8,10,14</sup>

#### 6. Limitations of the study

Statistically significant results were obtained for the objectives of the study; however, the following limitations were noted:

1. Study sample size was small. It is recommended to confirm the results with a larger sample and preferably in a multicentric setting.
2. There was a lack of uniform distribution in the male and female groups; hence the gender-based comparison could not be carried out.
3. The present study was for a short duration, thus the stability of the results achieved could not be

established. It is recommended to have a long-term follow-up of the results obtained.

4. There was a lack of control sample in the study.

#### 7. Conclusion

The following conclusions were drawn from the study:

1. The null hypothesis was rejected as changes were observed in the skeletal, dental and soft tissue parameters following PowerScope™ 2 FFA.
2. PowerScope™ 2 serves as an effective appliance for the correction of skeletal Class II malocclusion among growing patients.
3. The skeletal Class II correction was primarily caused by dentoalveolar changes with comparatively less contribution from skeletal changes. Marked improvement in facial esthetics was noted as contributed by soft tissue changes following PowerScope™ 2 FFA therapy.

#### 8. Source of Funding

None.

#### 9. Conflict of Interest

None.

#### References

1. Alhammadi MS, Halboubi E, Fayad MS, Labib A, Saidi CE. Global distribution of malocclusion traits: A systemic review. *Dent Press J Orthod.* 2018;23(6):1–10.
2. Siddegowda R, Satish RM. The prevalence of malocclusion and its gender distribution among school children: An epidemiological survey. *SRM J Res Dent Sci.* 2014;5(4):224–33.
3. Mcnamara JA. Components of class II malocclusion in children 8-10 years of age. *Angle Orthod.* 1981;51(3):177–202.
4. Papadopoulos MA. Orthodontic treatment of the Class II non-compliant patient: Current principles and techniques. St Louis: Mosby; 2006. p. 9–17.
5. American Orthodontics Introduces Powerscope Class II Corrector; 2021. Available from: <https://orthodonticproductsonline.com/miscellaneous/american-orthodontics-introduces-powerscope-class-ii-corrector>.
6. Graber TM, Rakosi T, Petrovic AG. Dentofacial orthopedics with functional appliances. St Louis: Mosby; 1997.
7. Panigrahi P, Vineeth V. Biomechanical effects of fixed functional appliance on craniofacial structures. *Angle Orthod.* 2009;79(4):668–75.
8. Zymperdikas VF, Koretski V, Papageorgiou SN, Papadopoulos MA. Treatment effects of fixed functional appliances in patients with Class II malocclusion: a systematic review and meta-analysis. *Eur J Orthod.* 2015;37(4):418–52.
9. Perinetti G, Primozic J, Furlani G, Franchi L, Contardo L. Treatment effects of fixed functional appliances alone or in combination with multibracket appliances: A systematic review and meta-analysis. *Angle Orthod.* 2015;85(3):480–92.
10. Malhotra A, Negi KS, Kaundal JR, Negi N, Mahajan M, Chainta D, et al. Cephalometric evaluation of dentoskeleton and soft tissue changes with Powerscope class II retractor. *J Indian Orthod Soc.* 2018;52(3):167–73.

11. Voudouris JC, Kuftevec MM. Improved clinical use of Twin-block and Herbst as a result of radiating viscoelastic tissue forces on the condyle and fossa in treatment and long-term retention: Growth relativity. *Am J Orthod Dentofac Orthop.* 2000;117(3):247–66.
12. Zhou X, Zhou Z, Zhao M. [Analysis of the condyle in the state on the mandibular protrusion by means of the three-dimensional finite element method]. *Zhonghua Kou Qiang Yi Xue Za Zhi.* 1993;34(2):85–92.
13. Hu L, Zhou Z, Song J, Fan Y, Jiang W, Chen J. The influences of stress distribution on the condylar cartilage surface by Herbst appliance under various bite reconstruction - a three dimensional finite element analysis. *Hua Xi Kou Qiang Yi Xue Za Zhi.* 2001;19(1):46–54.
14. Antony T, Amin V, Hegde S, Hegde S, Shetty D, Khan MB. The evaluation and clinical efficiency of Powerscope: An original research. *J Int Soc Prevent Communit Dent.* 2018;8(3):264–70.
15. Pancherz H. The mechanism of Class II correction in Herbst appliance treatment. *Am J Orthod Dentofac Orthop.* 1982;82(2):104–17.
16. Ruf S, Pancherz H. Dentoskeletal effects and facial profile changes in young adults treated with Herbst appliance. *Angle Orthod.* 1999;69(3):239–84.
17. Heinig N, Goz G. Clinical applications & effects of Forsus spring. *J Orofac Orthod.* 2001;62(6):436–50.
18. Stromeyer EL, Caruso JM, Devincenzo JP. A cephalometric study of the Class II correction effects of the Eureka spring. *Angle Orthod.* 2002;72(3):203–13.
19. Manni A, Pasini M, Mauro C. Comparison between Herbst appliance with or without miniscrew anchorage. *Dent Res J (Isfahan).* 2012;9(2):216–37.
20. Elkordysa, Abouelezz AM, Fayed MM, Attia KH, Ishaq RA, Mostafa YA. Three dimensional effects of the mini implant anchored Forsus fatigue resistant device: A randomized controlled trial. *Angle Orthod.* 2016;86(2):292–305.

### Author biography

**Dhruv Jain**, Assistant Professor

**Sanjeev Datana**, Professor

**Sukhbir Singh Chopra**, Professor

**Cite this article:** Jain D, Datana S, Chopra SS. Is PowerScope™ 2 an effective Class II corrector ? A prospective cephalometric study. *J Contemp Orthod* 2023;7(2):94–100.