



## Original Research Article

## Evaluation of skeletal changes in glenoid fossa, condylar head and articular space following fixed functional appliance therapy using cone beam computed tomography – A clinical prospective study

Kunaal Agrawal<sup>1\*</sup>, Shashikala Kumari V.<sup>2</sup>

<sup>1</sup>Dept. of Orthodontics and Dentofacial Orthopaedics, Rishiraj College of Dental Science, Bhopal, Madhya Pradesh, India

<sup>2</sup>Dept. of Orthodontics and Dentofacial Orthopaedics, Government Dental College and Research Institute, Bangalore, Karnataka, India



## ARTICLE INFO

## Article history:

Received 24-11-2022

Accepted 03-04-2023

Available online 16-06-2023

## Keywords:

Cone Beam Computed Tomography (CBCT)

Powerscope appliance

Condyle

Glenoid fossa

Articular space

## ABSTRACT

**Objective:** This study was conducted to evaluate skeletal changes in glenoid fossa, condylar head and articular space following Powerscope appliance therapy using CBCT.

**Materials and Methods:** This study included twenty patients (age group of 11-15 years) having Class II Division 1 skeletal & dental malocclusion. A pre-treatment CBCT scan (T1) of both TMJs was taken. Following leveling & aligning, Powerscope appliance was inserted, which was sequentially activated using crimpable shims until edge-to-edge bite was obtained. After completion of phase 1 of treatment, another CBCT scan (T2) was taken. Condylar position, length, height, glenoid fossa & articular space measurements were obtained from pre- & post-treatment CBCT scans and data obtained were statistically analysed and compared by Paired-t test.

**Results:** Comparison between T1 & T2 data showed that the condyles were shifted anteriorly by 1.08 mm, condylar length and height increased by 0.26 mm and 0.71 mm, respectively. Glenoid fossa and anterior articular space decreased by 1.50° and 0.23 mm, whereas, middle and posterior articular spaces increased linearly by 2.55 mm and 1.85 mm, respectively.

**Conclusion:** Powerscope shifted the condyle anteriorly, increased its length and height, and reduced the glenoid fossa angle. Anterior articular space decreased whereas middle and posterior articular spaces increased.

This is an Open Access (OA) journal, and articles are distributed under the terms of the [Creative Commons Attribution-NonCommercial 4.0 International](https://creativecommons.org/licenses/by-nc/4.0/), which allows others to remix, and build upon the work non-commercially, as long as appropriate credit is given and the new creations are licensed under the identical terms.

For reprints contact: [reprint@ipinnovative.com](mailto:reprint@ipinnovative.com)

## 1. Introduction

In clinical setting, skeletal Class II malocclusion may manifest either by prognathic maxilla and orthognathic mandible, or orthognathic maxilla and retrognathic mandible, or a combination of the two.<sup>1,2</sup>

One of the recommended therapeutic approaches to Class II malocclusion in growing patients, who are around circumpubertal growth period, is functional jaw orthopedics through the primary mechanism of mandibular

advancement. This forms the basis of growth modulation therapy.

Contrary to removable functional appliances, fixed functional devices do not require patient's collaboration and can be worn full time in association with multibracket therapy, so that skeletal and dental discrepancies can be corrected in a single phase treatment. This modality significantly reduces treatment duration and cost factor.<sup>3</sup>

Shortcomings of 2D diagnostic imaging techniques paved way to 3D imaging techniques, which have provided a new possibility for orthodontic diagnosis and treatment

\* Corresponding author.

E-mail address: [confidential.braces@gmail.com](mailto:confidential.braces@gmail.com) (K. Agrawal).

evaluation. The application of recently introduced cone beam computed tomography (CBCT) to craniofacial region provides an alternative to traditional computed tomography (CT) systems with advantages of reduced radiation and lower expenditure. 3D superimposition protocol uses a ridged voxel-based registration technique that eliminates examiner bias in the registration process.<sup>4</sup>

Since Powerscope has been recently introduced to the orthodontic fraternity, very limited studies have been published regarding this appliance till date. So the aim of this study was to evaluate skeletal changes produced in the condyle, glenoid fossa and articular space following Powerscope appliance, in collaboration with multibracket fixed appliance treatment, using cone beam computed tomography.

Objectives of the study were to measure position, length and height of condyle, glenoid fossa angle and articular space at anterior, middle and posterior regions using CBCT scans following Powerscope appliance treatment.

## 2. Materials and Methods

Twenty patients with mandibular retrognathia visiting the institute's Department of Orthodontics were included in this study.

All subjects and their parents were informed about the procedures to be performed and signed informed consent was obtained from the parent/guardian, as all patients were minor.

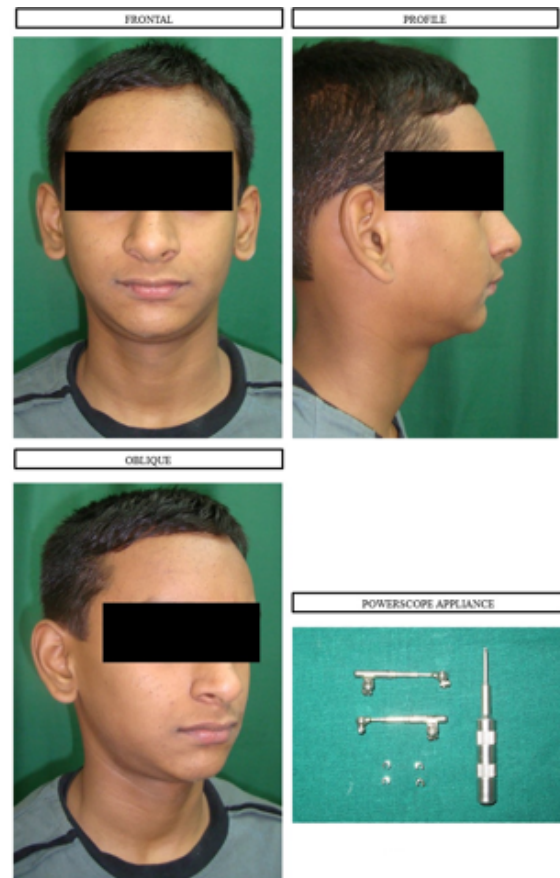The study was approved by Institutional Ethics Committee and review board, Government Dental College and Research Institute, Bangalore, vide letter no. GDCRI/ACM(2)/3562/2015-16.

Young growing patients presenting with Class II Division 1 skeletal and dental malocclusion with mandibular retrognathia and within Cervical Vertebral Maturity Indicator Stage 4 and 5<sup>5</sup> were included in the study.

Subjects with CVMI stage < 3 and > 5, subjects having any periodontal disease(s), subjects having undergone any previous orthodontic treatment(s), subjects with any history or symptoms of temporomandibular joint disease(s) or any systemic disease(s) affecting bone metabolism were excluded from the study.

Eleven growing patients, who fulfilled the selection criteria, were chosen. Following their preliminary extraoral and intraoral examination, diagnostic records were made (Figures 1 and 2), which confirmed orthognathic maxilla, retrognathic mandible and horizontal to average growth pattern. A CBCT scan was obtained of both temporomandibular joints before commencement of treatment (T1) to check for the position of condyle, condylar length, condylar height, glenoid fossa and articular space using KODAK 9000 3D Extraoral Imaging System (Carestream Health, Rochester, New York, USA) and data were exported as DICOM images to CS 3D

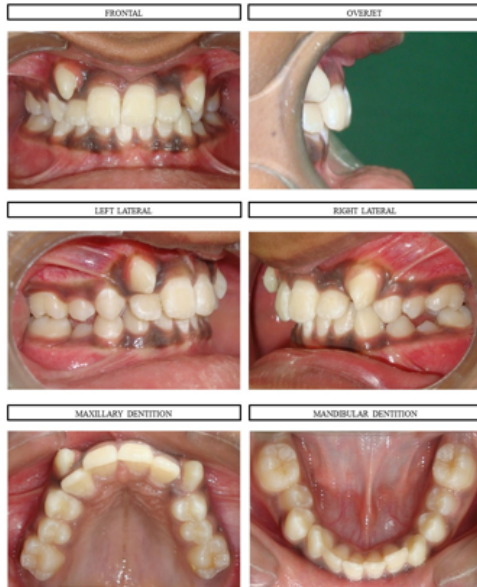
Imaging Software (Carestream Health, Rochester, New York, USA).



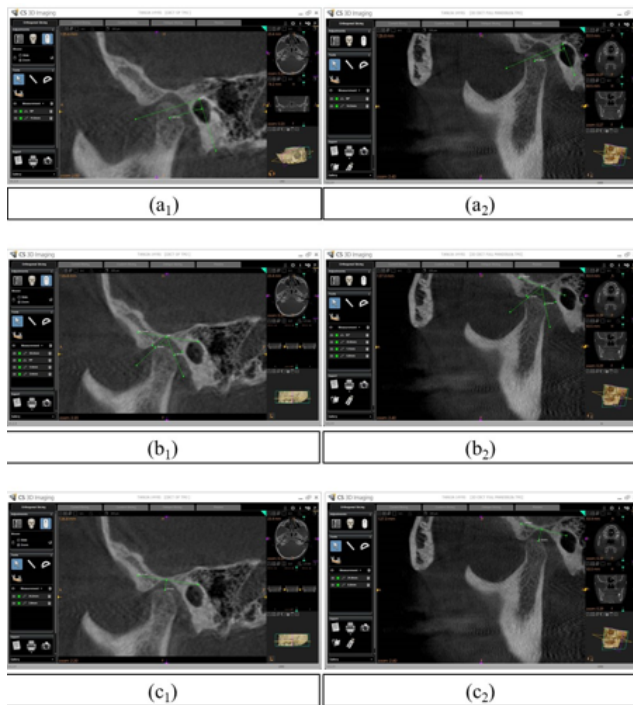
**Figure 1:** Extraoral pre-treatment photographs and powerscope appliance

After CBCT scans were analyzed, the above mentioned variables were assessed on DICOM images using the same software. The field of view was confined to both TMJs so that condylar head, glenoid fossa and external auditory meatus were visualized. To carry out the measurements on CBCT scan, conventional sagittal slicing was used. A horizontal line was constructed passing through the tangent of external acoustic meatus, which was parallel to the true horizontal.<sup>6</sup> The section of the CBCT was then aligned such that maximum length and width of the external auditory meatus was obtained. After locating the midpoint of external auditory meatus, a line, perpendicular to the tangent and passing through the midpoint, was drawn. Linear measurement was obtained by drawing a line from the center of the condylar head to the midpoint of external auditory meatus parallel to the tangent<sup>6</sup> (Figure 3 a-c).

Glenoid fossa angle was measured by drawing a tangent to anterior and posterior slopes of glenoid fossa<sup>6</sup> (Figure 4, a-c). Linear measurements between anterior and posterior slopes of glenoid fossa and condylar head at three different

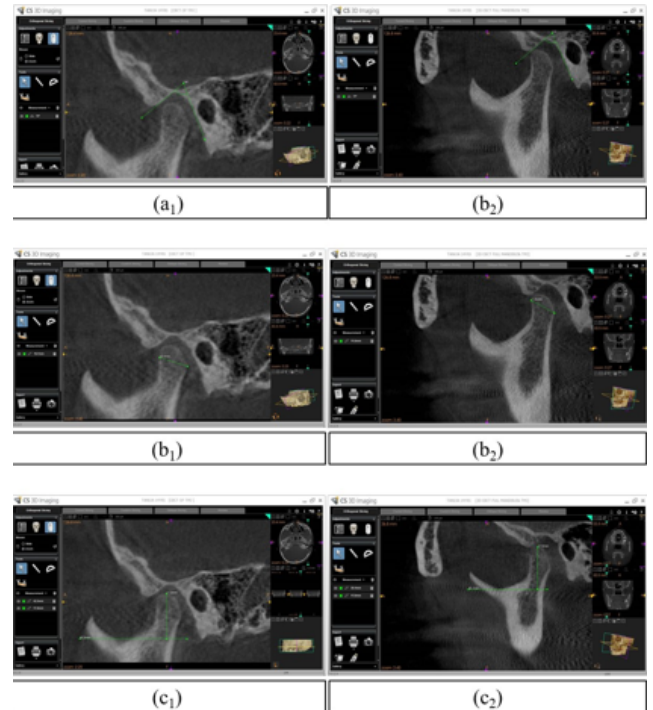


**Figure 2:** Intraoral pre-treatment photographs



**Figure 3:** a-c : a<sub>1</sub> – Pre-Treatment (T1) Condylar Position, a<sub>2</sub> – Post-Treatment (T2) Condylar Position, b<sub>1</sub> – Pre-Treatment (T1) Anterior and Posterior Articular Spaces, b<sub>2</sub> – Post-Treatment (T2) Anterior and Posterior Articular Spaces, c<sub>1</sub> – Pre-Treatment (T1) Middle Articular Space, c<sub>2</sub> – Post-Treatment (T2) Middle Articular Space

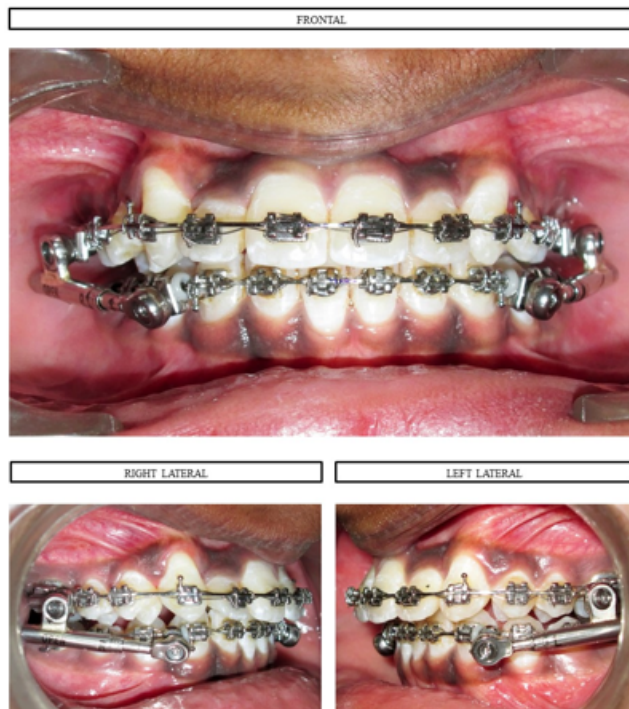locations i.e., anterior,<sup>7</sup> middle<sup>8</sup> and posterior,<sup>7</sup> were taken for articular space (Figure 3, a-c). Linear measurement was carried out to get the size of condylar head between points on anterior and posterior curvature of condylar head.<sup>9</sup> Condylar height was obtained by drawing a perpendicular from the highest point on the condylar head to a tangent to the deepest point on sigmoid notch<sup>9</sup> (Figure 4, a-c).



**Figure 4:** a-c: a<sub>1</sub> – Pre-Treatment (T1) Glenoid Fossa Angle, a<sub>2</sub> – Post-Treatment (T2) Glenoid Fossa Angle, b<sub>1</sub> – Pre-Treatment (T1) Condylar Length, b<sub>2</sub> – Post-Treatment (T2) Condylar Length, c<sub>1</sub> – Pre-Treatment (T1) Condylar Height, c<sub>2</sub> – Post-Treatment (T2) Condylar Height

Firstly, 0.022x0.028” preadjusted edgewise MBT brackets (American Orthodontics, Sheboygan, WI, USA) were bonded to the patients’ dentition. Upper and lower second molars were also banded/bonded in order to minimize intrusive forces on the molars. A transpalatal arch was placed to maintain transverse dimension of the maxillary arch. After initial leveling and aligning, 0.019x0.025” U/L rectangular stainless steel archwires were placed for 1 month. Labial root torque was provided in the lower archwire in mandibular anterior region and archwires were cinched back in order to prevent dumping of mandibular anteriors. Entire maxillary and mandibular arches were consolidated using 0.009” stainless steel ligature. Later, Powerscope Appliance (American Orthodontics, Sheboygan, WI, USA) (Figure 1) was placed. Intraoral photographs (Figure 2) were taken. Patients were called after 10 days for an initial check-up, then once every 4 weeks for regular check-up for a period of 6-8

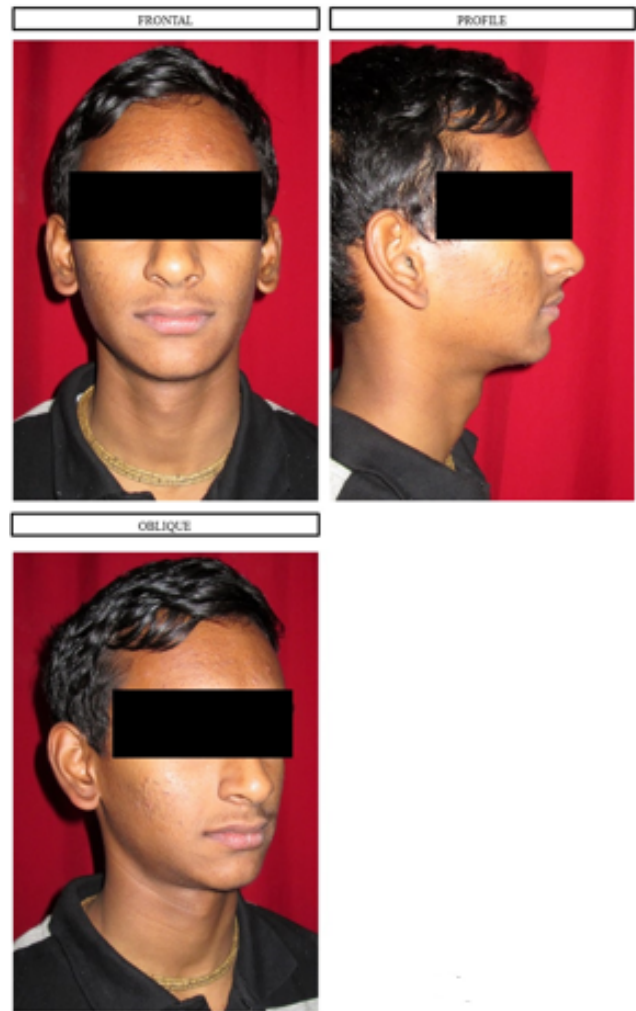months. Monthly appointments included assessment of attainment of pterygoid reflex, any breakages of the fixed appliance, and checkup for any discomfort and regular motivation. Appliance was sequentially activated by using crimpable shims (available in 2 mm and 3 mm sizes) depending on the amount of skeletal discrepancy in each patient's mouth, until edge-to-edge bite was obtained. After completion of 6-8 months of treatment with Powerscope appliance, CBCT of both temporomandibular joints were repeated (T2) to quantify skeletal changes produced in glenoid fossa, condylar head and articular space and to compare with linear and angular measurements from pre-treatment scans (T1). Following complete treatment duration of approximately 24 months, post-treatment extraoral and intraoral records were taken (Figures 5, 6 and 7). Removable retention appliance with inclined plane for maxillary dentition and fixed lingual retainer for mandibular dentition was placed. Out of 11 patients, 3 did not report for further treatment so total 8 patients completed the Powerscope appliance therapy successfully.



**Figure 5:** Intraoral photographs with Powerscope appliance

All measurements were carried out by two operators, to avoid intra- and inter-observer errors. Double assessment of each parameter was done at least 1 week apart to check for intra- & inter-examiner reliability which was excellent as coefficient of correlation was above 0.96 for all CBCT measurements.

The data obtained were subjected to statistical analysis. Means, standard errors, and standard deviations were tabulated, which were calculated using SPSS (Statistical



**Figure 6:** Extraoral post-treatment photographs

Package for Social Sciences Software, SPSS Inc., Chicago, Ill, USA).

### 3. Results

Sample size included 5 females (45.45%) and 6 males (54.54%), with a mean age of 12.50 years for female patients and 13.66 years for male patients.

The statistical test used in this study was paired t-test. The level of significance ( $\alpha$ ) was set at 0.05.

Statistically significant forward positioning of the mandibular condyle and increase in condylar length, condylar height, middle & posterior articular space was seen on both sides. Statistically significant decrease in anterior articular space and glenoid fossa angle was seen (Figures 8, 9 and 10). The mean difference between T1 & T2 on both sides of above variables is shown in Tables 1 and 2. In all of the variables studied, statistically significant difference was not seen between either side, so mean of both sides is taken

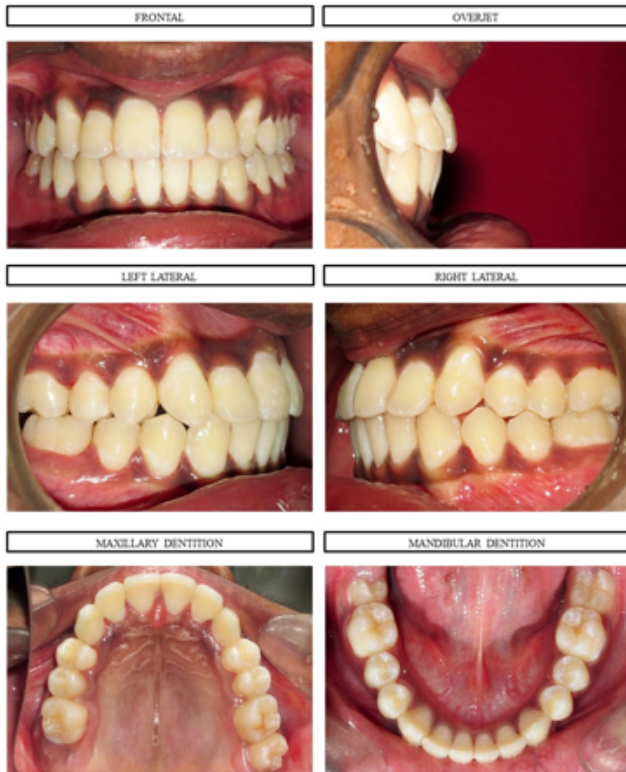


Figure 7: Intraoral post-treatment photographs

(Table 2).

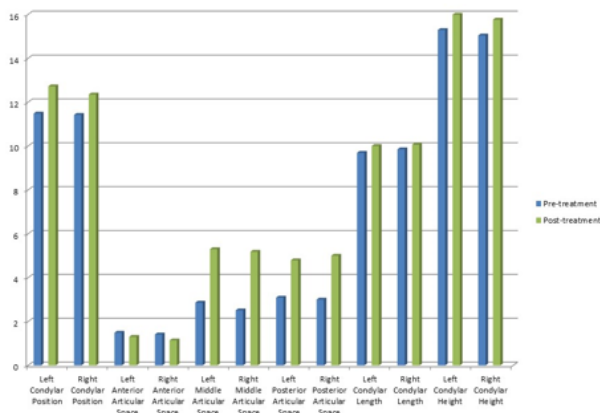


Figure 8: Comparison of different variables between pre-treatment & post-treatment on CBCT scans

#### 4. Discussion

The treatment of Class II malocclusion has always presented with a challenge to the orthodontists.

Over time, although various fixed functional jaw orthopaedic appliances were developed for correction of Class II malocclusion with mandibular retrusion,

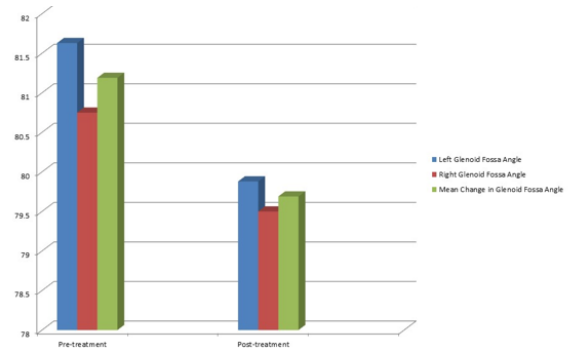


Figure 9: Comparison of glenoid fossa angle on right & left sides and mean value between pre treatment and post-treatment on CBCT scans

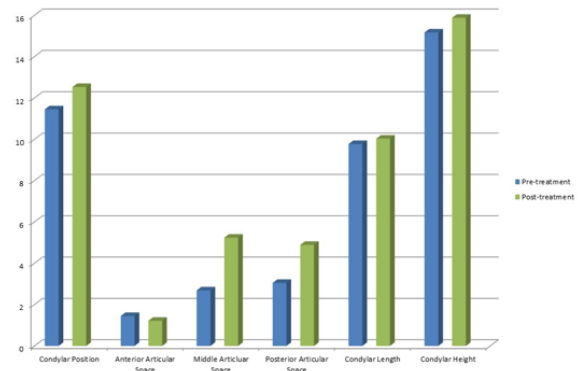


Figure 10: Comparison of mean changes in variables between pre-treatment and post-treatment on CBCT scans

Powerscope appliance was used in this study owing to its certain advantages. The problem of fatigue failure is addressed by its telescopic spring architecture, which is usually the case with rigid fixed functional appliances, and hence, greatly reduces the number of patient’s emergency visits to the orthodontist.<sup>10</sup> This appliance is factory manufactured and doesn’t require any chairside assembly. Appliance placement is not cumbersome, since it can be directly attached to the archwire. Activation is done by adding crimpable shims of predefined dimensions for stepwise advancement of mandible and this greatly reduces the orthodontist’s chairside time during follow-up activation appointments.

According to Baccetti et al,<sup>11</sup> when twin block appliance is used, best results of orthopedic correction are obtained when patients are treated during or slightly after the onset of pubertal peak.

There are instances when patients report to the orthodontist seeking treatment when he/she has reached past the age of pubertal growth spurt. By then, maximum percentage of growth has already been completed, with only residual condylar growth to be completed. But according to Aras,<sup>7</sup> Konik,<sup>12</sup> and Ruf and Pancherz,<sup>13</sup> mandibular growth

**Table 1:** Comparison of different variables between pre-treatment & post-treatment on CBCT scans

S. No.	Parameter (in mm)	Pre-Treatment (T1)		Post-Treatment (T2)		Mean Difference	P Value
		Mean	SD	Mean	SD		
1.	Left Condylar Position	11.48	± 0.49	12.72	± 0.57	1.24	0.000
2.	Right Condylar Position	11.42	± 1.38	12.35	± 1.36	0.93	0.001
3.	Left Anterior Articular Space	1.49	± 0.27	1.30	± 0.22	0.19	0.004
4.	Right Anterior Articular Space	1.41	± 0.29	1.14	± 0.13	0.27	0.028
5.	Left Middle Articular Space	2.86	± 0.58	5.30	± 0.56	2.44	0.000
6.	Right Middle Articular Space	2.51	± 0.43	5.18	± 0.57	2.67	0.000
7.	Left Posterior Articular Space	3.09	± 0.40	4.79	± 0.61	1.70	0.000
8.	Right Posterior Articular Space	3.00	± 0.53	5.00	± 0.96	2.00	0.000
9.	Left Glenoid Fossa Angle*	81.63	± 3.58	79.88	± 3.36	1.75	0.001
10.	Right Glenoid Fossa Angle*	80.75	± 4.74	79.50	± 3.93	1.25	0.006
11.	Left Condylar Length	9.69	± 0.54	10.00	± 0.76	0.31	0.012
12.	Right Condylar Length	9.85	± 0.52	10.06	± 0.66	0.21	0.042
13.	Left Condylar Height	15.29	± 1.93	15.99	± 2.10	0.70	0.003
14.	Right Condylar Height	15.04	± 1.90	15.76	± 1.99	0.72	0.005

\* Indicates values in Degrees

**Table 2:** Comparison of different variables on right and left sides between pre-treatment & post-treatment on CBCT scans

S.No.	Parameter (in mm)	Left		Right		Mean Difference	P Value	Average Change
		Mean	SD	Mean	SD			
1.	Condylar Position	1.24	± 0.50	0.93	± 0.46	0.31	0.557	1.08
2.	Anterior Articular Space	0.19	± 0.12	0.27	± 0.28	0.08	0.820	0.23
3.	Middle Articular Space	2.44	± 0.86	2.67	± 0.44	0.23	0.449	2.55
4.	Posterior Articular Space	1.70	± 0.35	2.00	± 0.55	0.30	0.498	1.85
5.	Glenoid Fossa Angle*	1.75	± 0.89	1.25	± 1.58	0.50	0.700	1.50
6.	Condylar Length	0.31	± 0.26	0.21	± 0.24	0.10	0.385	0.26
7.	Condylar Height	0.70	± 0.43	0.72	± 0.41	0.02	0.556	0.71

\* Indicates values in Degrees

can extend beyond puberty, and minimal residual growth can only be stimulated with fixed functional appliances. According to Ruf and Pancherz,<sup>13,14</sup> Herbst appliance is most successful in treatment of Class II patients who are at the end of growth period. According to Pancherz's viewpoint,<sup>5</sup> orthopedic growth adaptation with the use of Herbst appliance is a useful alternative to orthognathic surgery in borderline adult skeletal Class II cases and that owing to remodeling capacity of TMJ in adult patients, it can be used for growth modulation in young adults for bringing about skeletal changes in the TMJ. The phenomenon of 'Cephalocaudal Gradient of Growth' also applies in the craniofacial region, as elsewhere in the body, wherein mandible, being distal to the cranium, continues its sagittal growth until late adolescence whereas maxilla,

being in proximity to the cranium, completes its growth before the mandible.<sup>15</sup>

Thus, in this study, case selection was done keeping above factors in mind.

As stated earlier, owing to its high degree of accuracy and reliability<sup>9,16–18</sup> in maxillofacial imaging, CBCT of TMJ was preferred for measuring the said parameters.

#### 4.1. Treatment effect on condyles

A forward shift in condylar position obtained in this study (Tables 1 and 2) is in agreement with Wadhawan et al.<sup>6</sup> where an MRI study concluded that forward condylar shift of 1.20 mm was seen following functional appliance treatment.

An increase in the condylar length and height (Tables 1 and 2) contributed to overall increase in mandibular length. In previous studies, a similar change in condylar dimensions after Herbst appliance therapy was reported by LeCornu et al.,<sup>4</sup> Ruf and Pancherz.<sup>19</sup>

#### 4.2. Treatment effect on glenoid fossa

In this study, bone remodeling in the glenoid fossa can be explained by a decrease in glenoid fossa angle (Tables 1 and 2) which indicates bone deposition on the posterior slope and bone resorption along the anterior slope of glenoid fossa. Similar changes were noticed by LeCornu et al.<sup>4</sup> and Ruf and Pancherz<sup>19</sup> while using Herbst appliance. LeCornu et al.<sup>4</sup> reported bone resorption along the anterior wall (right, 1.69 mm; left, 1.43 mm) with deposition along the posterior wall of glenoid fossa (right, 0.59 mm; left, 0.79 mm).

Ruf and Pancherz<sup>19</sup> reported that remodeling of the glenoid fossa occurred at inferior part of anterior surface of post-glenoid spine and decreased progressively towards the superior part of the fossa. Findings in the glenoid fossa in our study are in agreement with findings of the study mentioned above.

Rabie et al.<sup>20</sup> and Jung<sup>21</sup> have associated the changes in the glenoid fossa to changes occurring at the cellular level. They found that mandibular protrusion resulted in osteoprogenitor cells being oriented in the direction of pull of posterior fibers of articular disc and also resulted in a considerable increase in bone formation in the glenoid fossa. Changes in the glenoid fossa observed in this study could be probably due to similar cellular responses.

It has been reported that new bone formation seems to be induced by tensile forces of posterior fibrous tissues of articular disc transmitted to the periosteum of the glenoid fossa. This indicated that at least two etiological factors might be responsible for growth modification mechanism: force of viscoelastic tissues and force transduction. The viscoelastic properties are associated with the stretched retrodiscal tissues, fibrous capsule, and sticky, hydrophilic synovial fluids communicating with the condyle and the glenoid fossa, described in the growth relativity hypothesis.<sup>22</sup> Also, according to Voudouris,<sup>23</sup> bone formation found in experimental animals up to the articular eminence, where there is no retrodiscal attachment, has also been linked to force transduction, which appears to be produced from the attachment of the retrodiscal tissues at the anterior aspect of the fossa. Hence, changes in the glenoid fossa could be due to new bone formation as explained by above studies.

#### 4.3. Treatment effect on articular space

In this study, anterior articular space was found to be reduced whereas middle and posterior articular spaces

increased (Tables 1 and 2).

From above results, it is clear that skeletal changes were seen in both sagittal and vertical planes with respect to condyle and in sagittal plane with respect to glenoid fossa which contributed to statistically significant overall increase in mandibular length. Studies conducted by Wadhawan<sup>6</sup> and Baysal<sup>24</sup> on effects of twin block concluded that treatment effects were mainly due to mandibular skeletal changes by anterior relocation of Condyle-Glenoid Fossa (C-GF) complex. As mentioned in previous studies conducted on appliances like Herbst, Eureka spring, Jasper Jumper, Forsus nitinol flat-spring and Forsus Fatigue Resistant Device by Cacciatore,<sup>3</sup> Aras,<sup>7</sup> Karacaya,<sup>25</sup> Servello,<sup>26</sup> Perinetti,<sup>27</sup> Franchi,<sup>28</sup> Aslan<sup>29</sup> Zymperdikas,<sup>30</sup> and Celikoglu<sup>31</sup> respectively, as well as studies on Powerscope appliance particularly conducted by Agarwal,<sup>32</sup> Antony,<sup>33</sup> Ansari,<sup>34</sup> Singaraju,<sup>35</sup> Varghese,<sup>36</sup> and Kaur,<sup>37</sup> the overall correction of Class II malocclusion by fixed functional appliances is mainly dentoalveolar in nature. But in this study, only skeletal changes in condyle-glenoid fossa region were evaluated, whereas changes in dentoalveolar structures before and after Powerscope appliance treatment were not taken into account.

Besides skeletal changes induced by Powerscope appliance in the C-GF region, other factors such as relief of dental intercuspation due to the appliance and intrinsic genetic potential of the patient favoring residual sagittal mandibular growth, ought to be taken into consideration. However, there is a complex interplay of above mentioned factors which govern the growth modulation therapy using functional appliances which might have played a role in sagittal correction of the mandible.

More evidence is required in order to substantiate long term skeletal and dentoalveolar effects caused by Powerscope appliance.

## 5. Conclusion

When powerscope appliance was incorporated for the correction of skeletal Class II malocclusion, it can be concluded that:

1. An average forward shift of mandibular condyle by 1.08 mm was seen after 6-8 months of treatment.
2. An increase in condylar length (0.26 mm) and height (0.71 mm) was seen, which may have contributed to increase in mandibular length.
3. Changes in anterior and posterior slopes of the glenoid fossa may have led to decrease in glenoid fossa angle ( $1.50^\circ$ ).
4. An average decrease in anterior articular space by 0.23 mm and increase in middle and posterior articular space by 2.55 mm and 1.85 mm respectively, was seen which could be due to forward shift of the condyle and changes in the glenoid fossa.

## 6. Acknowledgement

We would like to extend our acknowledgement to Dr. Alok Chaurasia, MD, who helped us with the statistical analysis of this study, and Dr. Vinod Kumar, MDS, who helped us in interpreting and analyzing the CBCT results.

## 7. Source of Funding

None.

## 8. Conflict of Interest

None.

## References

- Venes D. Taber's Cyclopedic Medical Dictionary. 20th ed. and others, editor; 2005. p. 1298.
- Daskalogiannakis J. Glossary of Orthodontic Terms. Germany: Quintessence Publishing Co, Inc. Berlin; 2000. p. 284.
- Cacciatore G, Tomas L, Alvetroc HG, Giuntini L, Franchi V. Treatment and post-treatment effects induced by the Forsus appliance - A controlled clinical study. *Angle Orthod.* 2014;84(6):1010–27.
- Lecornu M, Lucia HS, Cevidanes, Zhu H, Wu CD, Larson B. Three-dimensional treatment outcomes in Class II patients treated with the Herbst appliance: A pilot study. *Am J Orthod Dentofac Orthop.* 2013;144(6):818–48.
- Pancherz H. Dentofacial orthopedics or Orthognathic surgery: Is it a matter of age? *Am J Orthod Dentofac Orthop.* 2000;117(5):571–74.
- Wadhawan N, Kumar S, Kharbanda OP, Duggal R, Sharma R. Temporomandibular joint adaptations following two-phase therapy: an MRI study. *Orthod Craniofac Res.* 2008;11(4):235–50.
- Aras A, Saracoglu AE, Gezer H, Aras NS. Comparison of treatments with the Forsus fatigue resistant device in relation to skeletal maturity: A cephalometric and magnetic resonance imaging study. *Am J Orthod Dentofac Orthop.* 2011;140:616–41.
- Ikeda K, Kawamura A. Assessment of optimal condylar position with limited cone-beam computed tomography. *Am J Orthod Dentofac Orthop.* 2009;135:495–501.
- Hilgers ML, Scarfe WC, Scheetz JP, Farman AG. Accuracy of linear temporomandibular joint measurements with cone beam computed tomography and digital cephalometric radiography. *Am J Orthod Dentofac Orthop.* 2005;128(6):803–14.
- Papadopoulos MA. Orthodontic Treatment of Class II Malocclusion in Non-compliant Patient. China: Elsevier Publishing; 2006. p. 10–2.
- Baccetti T, Franchi L, Toth LR, McNamara JA. Treatment timing for Twin-block therapy. *Am J Orthod Dentofac Orthop.* 2000;118(2):159–70.
- Konik M, Pancherz H, Hansen K. The mechanism of Class II correction in late Herbst treatment. *Am J Orthod Dentofac Orthop.* 1997;112:87–91.
- Ruf S, Pancherz H. Dentoskeletal effects and facial profile changes in young adults treated with the Herbst appliance. *Angle Orthod.* 1999;69(3):239–85.
- Ruf S, Pancherz H. Temporomandibular joint remodeling in adolescents and young adults during Herbst treatment: A prospective longitudinal magnetic resonance imaging and cephalometric radiographic investigation. *Am J Orthod Dentofac Orthop.* 1999;115(6):607–25.
- Proffit WR, Fields HW, Sarver DM. Contemporary Orthodontics. 4th ed. St. Louis, Missouri, USA: Mosby Elsevier; 2007. p. 28–30.
- Ye N. Accuracy of in-vitro tooth volumetric measurements from cone-beam computed tomography. *Am J Orthod Dentofac Orthop.* 2012;142(6):879–87.
- Honey OB, Scarfe WC, Hilgers MJ, Klueber K, Silveira AM, Haskell BS. Accuracy of cone-beam computed tomography imaging of the temporomandibular joint: Comparisons with panoramic radiology and linear tomography. *Am J Orthod Dentofac Orthop.* 2007;132(4):429–67.
- Berco M, Rigali JR, Miner PH, Deluca RM, Anderson S, Will NK. Accuracy and reliability of linear cephalometric measurements from cone-beam computed tomography scans of a dry human skull. *Am J Orthod Dentofac Orthop.* 2009;132(4):17–8.
- Ruf S, Pancherz H. Temporomandibular joint growth adaptation in Herbst treatment: a prospective magnetic resonance imaging and cephalometric roentgenographic study. *Eur J Orthod.* 1998;20(4):375–86.
- Rabie AB, Zhao Z, Shen G, Hägg EU, Robinson W. Osteogenesis in the glenoid fossa in response to mandibular advancement. *Am J Orthod Dentofacial Orthop.* 2001;119(4):390–400.
- Jung M. Fixed-functional appliance treatment combined with growth hormone therapy. *Am J Orthod Dentofacial Orthop.* 2017;152:402–414.
- Voudouris JC, Kuftinec MM. Improved clinical use of Twin-block and Herbst as a result of radiating viscoelastic tissue forces on the condyle and fossa in treatment and long-term retention: Growth relativity. *Am J Orthod Dentofac Orthop.* 2000;117(3):247–66.
- Voudouris J, Woodside DG, Altuna G, Kuftinec MM, Angelopoulos G, Bourque PJ. Condyle-fossa modifications and muscle interactions during Herbst treatment, Part 2. Results and conclusions. *Am J Orthod Dentofac Orthop.* 2003;124(1):13–29.
- Baysal A, Uysal T. Dentoskeletal effects of Twin Block and Herbst appliances in patients with Class II division 1 mandibular retrognathia. *Eur J Orthod.* 2014;36(2):36–164.
- Karacaya S, Akina E, Olmez H, Gurtonb AU, Sagdi D. Forsus Nitinol Flat Spring and Jasper Jumper Corrections of Class II division 1 Malocclusions. *Angle Orthod.* 2006;76(4):666–72.
- Servello DF, Fallis DW, Alvetro L. Analysis of Class II patients, successfully treated with the straight-wire and Forsus appliances, based on cervical vertebral maturation status. *Angle Orthod.* 2015;85(1):80–6.
- Perinetti G, Primozic J, Furlani G, Franchi L, Contardo L. Treatment effects of fixed functional appliances alone or in combination with multibracket appliances: A systematic review and meta-analysis. *Angle Orthod.* 2015;85(3):480–92.
- Franchi L, Alvetro L, Giuntini V, Masucci C, Defraia E, Baccetti T. Effectiveness of comprehensive fixed appliance treatment used with the Forsus Fatigue Resistant Device in Class II patients. *Angle Orthod.* 2011;81(4):678–83.
- Aslan BI, Kucukkaraca E, Turkoz C, Dincer M. Treatment effects of the Forsus Fatigue Resistant Device used with miniscrew anchorage. *Angle Orthod.* 2014;84(1):76–87.
- Zymperdikas VF, Koretsi V, Papageorgiou SN, Papadopoulos MA. Treatment effects of fixed functional appliances in patients with Class II malocclusion: a systematic review and meta-analysis. *Eur J Orthod.* 2015;38(2):113–39.
- Celikoglu M, Unal T, Bayram M, Candirli C. Treatment of a skeletal Class II malocclusion using fixed functional appliance with miniplate anchorage. *Eur J Dent.* 2014;8:276–80.
- Agarwal L, Singh K, Tandon R. Treatment of Class II Division 2 malocclusion using Powerscope: A case report. *Orthod J Nep.* 2018;8(1):63–7.
- Antony T, Amin V, Hegde S, Hegde S, Shetty D, Khan BM. The evaluation and clinical efficiency of Powerscope: Original research. *J Int Soc Prev Commun Dent.* 2018;8(3):264–70.
- Ansari A, Jain AK, Singh A, Sharma P, Adil M. Management of skeletal Class II malocclusion in non-compliant patient using Powerscope: A case report. *Orthod J Nepal.* 2019;9(2):77–81.
- Singaraju GS, Vannala V, Ankiseti SA, Mandava P, Ganugapanta VR, Unnam D. Evaluation of sagittal changes in Class II Division 2 patients with decelerating phase of growth by Powerscope appliance: A retrospective cephalometric investigation. *J Pharm Bioallied Sci.* 2019;11(2):208–15.
- Varghese RM, Subramanian AK, Sreenivasagan S. Comparison of dentoskeletal changes in skeletal Class II cases using two different




fixed functional appliances: Forsus Fatigue Resistant Device and Powerscope Class II Corrector: A clinical study. *J Int Oral Health*. 2021;13(3):234–78.

37. Kaur GJ, Gandhi G, Khanna M, Loomba A, Sharma A. A cephalometric evaluation and comparison of skeletal, dentoalveolar, and soft tissue changes brought about by Forsus Fatigue Resistant Device and Powerscope Fixed Functional Appliance. *J Indian Orthod Soc*. 2022;56(3):227–36.

**Shashikala Kumari V.**, Professor and HOD

**Cite this article:** Agrawal K, Shashikala Kumari V.. Evaluation of skeletal changes in glenoid fossa, condylar head and articular space following fixed functional appliance therapy using cone beam computed tomography – A clinical prospective study. *J Contemp Orthod* 2023;7(2):107-115.

### Author biography

**Kunaal Agrawal**, Associate Professor  <https://orcid.org/0000-0003-1050-3026>