



Original Research Article

Bond failures of orthodontic attachments during orthognathic surgery: A retrospective study

Sanjeev Datana¹, SS Agarwal^{1*}, ID Roy¹¹Dept. of Dental Surgery & OHS, Armed Forces Medical College Pune, Maharashtra, India

ARTICLE INFO

Article history:

Received 19-02-2023

Accepted 14-03-2023

Available online 16-06-2023

Keywords:

Bond failure

Orthodontic attachments

Molar tubes

Brackets

Orthognathic surgery

ABSTRACT

Introduction: Present study assessed the incidence of bond failures of orthodontic attachments during various orthognathic surgeries.

Materials and Methods: Treatment records of 100 patients undergone ortho-surgical rectification of skeletal malocclusion were divided into four groups: Maxillary Advancement (Max A), Maxillary Superior Repositioning (Max SR), Mandibular Advancement (Mand A), and Mandibular Setback (Mand S) surgery groups (25 patients, 200 molar tubes and 500 brackets in each group). The bond failure numbers for molar tubes and brackets during the surgical procedure were recorded. Values obtained from groups were added to attain the total number of bond failures during maxillary surgery and mandibular surgery.

Results: The incidence of bond failures did not differ significantly between Max A & Max SR groups and Mand A & Mand S groups (P-value>0.05). The incidence was higher in maxillary compared to mandibular surgery group (P-value<0.05); higher in molar tubes compared to brackets in Max A, Mand A and Mand S groups (P-value<0.05); and no difference between molar tubes and brackets in Max SR group (P-value>0.05).

Conclusions: The overall incidence of intra-operative bond failures reported was 4.75%. The debonding of molar tubes was more frequent (7.3%) than brackets (3.7%), with more incidence during maxillary surgery (5.57%) as compared to mandibular surgery (3.92%). Among the various orthognathic surgical procedures studied, the maximum bond failures were noted for maxillary superior repositioning (5.85%) and the least for mandibular advancement surgery (3.6%).

This is an Open Access (OA) journal, and articles are distributed under the terms of the [Creative Commons Attribution-NonCommercial 4.0 International](https://creativecommons.org/licenses/by-nc/4.0/), which allows others to remix, and build upon the work non-commercially, as long as appropriate credit is given and the new creations are licensed under the identical terms.

For reprints contact: reprint@ipinnovative.com

1. Introduction

The introduction of bonding in Orthodontics has eased orthodontic treatment by avoiding the cumbersome and time-consuming banding procedure.^{1,2} The bonding of molars has gained more popularity recently due to improvements in bonding material and bonding technology. A survey has shown that orthodontists prefer bonding over banding for first molars (52%) and second molars (33%). Bonding offers definitive advantages over banding: it eliminates the need for separator placement & band

cementation, reduces clinical time, reduces plaque accumulation & gingival inflammation, and subsequent demineralization of enamel.^{3–5}

The patients with skeletal malocclusion requiring ortho-surgical correction invariably undergo a phase of pre-surgical orthodontic preparation to decompensate the dentition, establish arch compatibility and prepare the dentition in such a way that the jaws fit into a stable occlusion post-surgically. The planned orthognathic procedure is then performed with an orthodontic appliance in place. The bonded orthodontic attachments (molar tubes and brackets) might debond (bond failure) during orthognathic surgery i.e., during osteotomy, down fracture

* Corresponding author.

E-mail address: docshivagarwal@rediffmail.com (S. S. Agarwal).

of the maxilla, mobilization of osteotomised segments, or while placing Inter-maxillary Fixation (IMF) as relatively heavier forces are applied during these procedures.^{6–8}

Studies have shown that bond failures (debonding) of orthodontic attachments during orthognathic surgery may result in complications such as surgical wound contamination and infection. These loose components may even get aspirated and displaced into the oropharynx and pose serious consequences.⁶ Though few case reports highlight this issue, to the best knowledge of the authors, there is no study available that quantifies the rate of bond failures of orthodontic attachments during different orthognathic surgeries, and therefore, the present study was commenced. The present study can help the ortho-surgical team plan suitable modifications in the preparations & procedures and avoid any potential adverse effects.

2. Aim

The study aimed to evaluate the incidence of bond failures of orthodontic attachments (bonded molar tubes and brackets) during various orthognathic surgeries.

3. Objectives

1. To evaluate the incidence of bond failures of orthodontic attachments during different maxillary and mandibular surgeries.
2. To compare the incidence of bond failures of orthodontic attachments between maxillary and mandibular surgeries.

4. Materials and Methods

4.1. Study design

Retrospective study

4.2. Study setting

The present study was executed on the patient records available in archives of a tertiary care government hospital's Department of Orthodontics and Dentofacial Orthopaedics.

4.3. Participants

The patient treatment records, who underwent ortho-surgical correction for management of skeletal malocclusions in the department between 01 Jan 2016 and 31 Dec 2020 and matched the selection criteria of the study were included. All patients were bonded with 0.022" McLaughlin, Bennett, Trevisi (MBT) orthodontic appliance. The sequence of archwire placement was same for all patients i.e., 0.016" Nickel-Titanium (NiTi), 0.17x0.25" NiTi, .017x0.25" Stainless Steel (SS), 0.19x0.25" SS and 0.21x0.25" SS archwires. SS ligatures (0.010") were used for archwire ligation in all cases and at all stages

of treatment. The orthognathic surgery was performed with 0.21x0.25" SS archwires placed in both arches. A single ortho-surgical team with adequate experience in orthognathic procedures operated on all cases with maxillary down fracture/ Bilateral Sagittal Split Ramus Osteotomy (BSSRO). The surgical splints were used in all cases intra-operatively to guide the surgical team during the fixing of the osteotomised segments with rigid fixation. The surgical splints were immobilized intra-operatively with intermaxillary fixation (IMF) using 26-gauge stainless steel wire. In each quadrant, two box-shaped IMF were done, one in the molar region (upper 1st molar to lower 1st molar) and the other in the premolar region (upper two premolars to lower two premolars).

4.4. Inclusion criteria

1. Both genders included
2. Cases treated with non-extraction protocol, with a full complement of dentition (up to second molars)
3. Bonded molar tubes (first and second molars)
4. Patients managed using a conventional orthognathic approach
5. Patients underwent single jaw surgery only (either maxilla or mandible)

4.5. Exclusion criteria

1. Syndromic patients including patients with Cleft Lip and Palate
2. Banded first and/or second molars
3. Patients who underwent Bi-jaw surgery or genioplasty alone
4. IMF placed on bone screws/ orthodontic implants
5. Patients with missing and extracted teeth (other than 3rd molars)

The patients who underwent Bi-jaw surgery were not part of this study. The reasons for not including Bi-jaw surgery patients were:

1. There is a requirement for double splints in Bi-jaw surgeries, both splints need to be secured to the jaws using orthodontic appliances, hence, increasing the chance of bond failures more than the cases with single jaw surgery requiring a single splint.
2. The duration of surgical procedures is prolonged for bi-jaw surgery as compared to single-jaw surgery. Hence, the exposure of orthodontic attachments to surgical procedures is prolonged. This may result in a higher rate of bond failures.
3. The quantum of manipulation of osteotomized segments in bi-jaw surgery is generally more as compared to single jaw surgery. Hence, the chance of bond failures is more.

4.6. Variables

The variables studied were the total number of bond failures of molar tubes (on 1st and 2nd molar) and brackets (on premolars, canines, and incisors) during the corrective surgical procedure.

Treatment records of 100 patients, managed with ortho-surgical correction of various skeletal malocclusions were selected. The patients were segregated into four groups:

1. Group: Maxillary Advancement (Max A surgery)
2. Group: Maxillary Superior Repositioning (Max SR surgery)
3. Group: Mandibular Advancement (Mand A surgery)
4. Group: Mandibular Setback (Mand S surgery)

Each group (n=25) comprised 200 molar tubes and 500 brackets which would equate to 8 tubes and 20 brackets per patient.

The number of bond failures (molar tubes & brackets) reported during various orthognathic procedures were noted from the record sheets of the patients. The values obtained from Group 1 and 2 were added to obtain total bond failures during maxillary surgery and Group 3 and 4 were added to obtain total bond failures during mandibular surgery. The data was gathered in MS Excel Sheets (Microsoft Excel v16.0, Microsoft Corporation, Washington) and analyzed with statistical analysis.

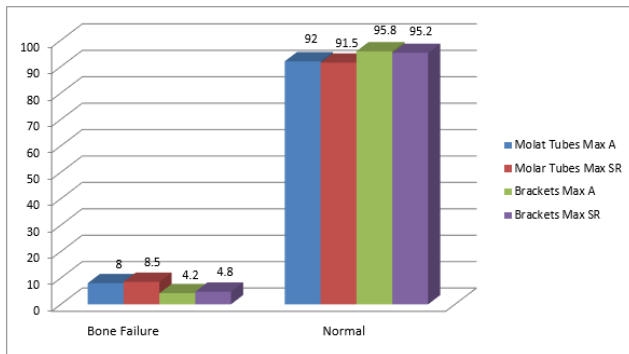


Figure 1: Percentage of bond failures during maxillary surgery

5. Results

5.1. Bond failures during maxillary surgery

Bond failure incidence was significantly higher in molar tubes compared to brackets in the Max A group (P-value<0.05). However, this incidence did not differ significantly between molar tubes and brackets in the Max SR group (P-value>0.05). The incidence did not differ significantly between Max A and Max SR groups (P-value>0.05) (Table 1, Figure 1).

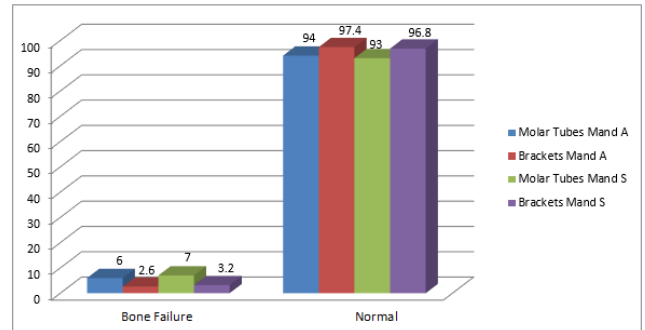


Figure 2: Percentage of bond failures during mandibular surgery

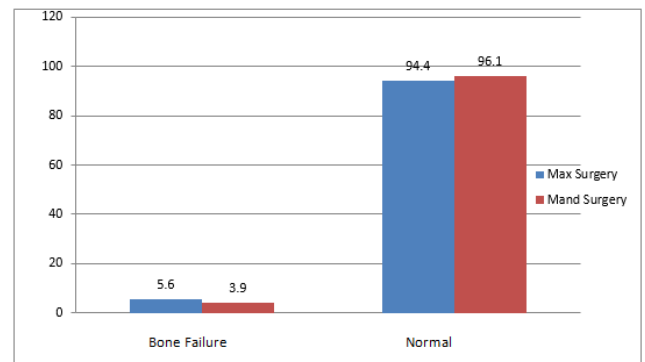


Figure 3: Bond failures during maxillary and mandibular surgery

5.2. Bond failures during mandibular surgery

The incidence of bond failures was significantly higher in molar tubes compared to brackets in both Mand A (P-value<0.05) and Mand S (P-value<0.05) groups. The incidence did not differ significantly between Mand A and Mand S groups (P-value>0.05) (Table 2, Figure 2).

5.3. Comparison of bond failures between maxillary and mandibular surgery

The incidence of bond failures was significantly higher in the maxillary surgery group compared to the mandibular surgery group (P-value<0.05) (Table 3, Figure 3).

6. Discussion

In preparation of a patient for surgical correction of underlying skeletal malocclusion using the conventional orthognathic approach, pre-surgical orthodontic treatment is initiated before the surgery. Though banding of molars provides better strength and rigidity during treatment, bonded attachments have recently gained popularity over banded because of the obvious advantages which include: no need for separators placement, no cementation, save clinical time, better periodontal health, and can be used in partially erupted teeth.⁶ Due to the above-mentioned

Table 1: Bond failures during maxillary surgery (n=50 cases)

Type of Surgery	Bond failures		Total (i+ii)	P-value(Molar tubes vs Brackets)	P-value(Max Avs Max SR)
	No of Molar tubes(i) (n=200)	No of Brackets(ii) (n=500)			
Maxillary Advancement (Max A) (n=25)	16 (8.0%)	21(4.2%)	37 (5.28%)	0.042*	0.641 ^{NS}
Maxillary Superior Repositioning (Max SR) (n=25)	17 (8.5%)	24 (4.8%)	41 (5.85%)	0.060 ^{NS}	

P-value by Chi-Square test. P-value<0.05 was considered to be statistically significant. *P-value<0.05, NS-Statistically non-significant.

Table 2: Bond failures during mandibular surgery(n=50 cases)

Type of Surgery	Bond failures		Total (i+ii)	P-value	P-value (Mand A vs Mand S)
	No of Molar tubes (i) (n=200)	No of Brackets (ii) (n=500)			
Mandibular Advancement (Mand A) (n=25)	12 (6.0%)	13 (2.6%)	25 (3.6%)	0.029*	0.492NS
Mandibular Setback (Mand S) (n=25)	14 (7.0%)	16 (3.2%)	30 (4.3%)	0.025*	

P-value by Chi-Square test. P-value<0.05 was considered to be statistically significant. *P-value<0.05, NS-Statistically non-significant.

Table 3: Comparison of bond failures between maxillary and mandibular surgery

Type of Surgery	Bond failures		Total (i+ii)	P-value (Maxillary vs Mandibular)
	Molar tubes (i)	Brackets (ii)		
Maxillary Surgery (n=50)	33 (8.25%)	45 (4.5%)	78 (5.57%)	0.041*
Mandibular Surgery (n=50)	26 (6.5%)	29 (2.9%)	55 (3.92%)	
Overall (n=100)	59 (7.3%)	74 (3.7%)	133 (4.75%)	

P-value by Chi-Square test. P-value<0.05 was considered to be statistically significant. *P-value<0.05.

reasons, an increased number of orthodontists prefer using bonded tubes on both first and second molars.

Literature has shown bond failure incidence ranging from 0.6 to 28.3% during routine orthodontic treatment.⁹ However, the chance of bond failures increases for patients who undergo an orthognathic surgical procedure in conjunction with routine orthodontic treatment. The reason for this could be the higher forces used during osteotomy of the jaw, manipulation of surgically osteotomized segments, frequent entanglement of surgeons' gloves and gauge pieces, and use of orthodontic attachments to secure surgical splints during IMF.⁶ A study reported a 16% incidence of missing/ loose brackets intraoperatively when IMF was achieved by ligating surgical splint to orthodontic appliances.¹⁰

The bond failures of the orthodontic appliance during fixed orthodontic treatment not involving orthognathic surgery have been reported as 18.4% & 2.6% for bonded and banded molars respectively.¹¹ Godoy F et al. reported an incidence of 1.9% attachment failure among bonded molars and no attachment failure among banded molars among patients who underwent orthognathic surgical procedures. They however did not relate bond failure with the type of surgery as done in our study.¹² The incidence of bond failures is higher among studies where the surgical splint was secured using orthodontic attachments as compared to studies where surgical screws were used instead. Attishia R et al. reported an attachment failure rate of 16% when the splint was secured with the orthodontic attachments during surgery and a reduced rate when it was secured using surgical screws.¹⁰ The results of the present study

show a mean bond failure incidence (molar tubes plus brackets) of 5.6% for maxillary surgery and 3.9% for mandibular surgery. This incidence reported is within the range documented in the literature. However, to the best knowledge of the authors, no study highlights the intra-operative incidence of bond failures of molar tubes & brackets with the type of orthognathic surgery, and hence, the present study was commenced to augment knowledge on the subject.

A higher rate of bond failures of molar tubes (p-value < 0.05) was experienced in our study, these results are similar to those of Godoy F¹² who observed bond failure most commonly in bonded maxillary second molars. Pandis N et al.¹³ observed a failure rate of 20% for bonded second molars and 9.66% for first molars. However, their study involved the evaluation of bond failures during routine orthodontic treatment and not intra-operatively with ortho-surgical procedures.

The bond failure incidence was significantly higher in the maxillary surgery group compared to the mandibular surgery group in the present study (P-value<0.05). This may be attributed to excessive force application and manipulation of the osteotomised maxilla during the maxillary down fracture leading to bond failure. The authors couldn't find any study comparing bond failure between maxilla and mandible during orthognathic surgery.

The loose attachments resulting from bond failures are generally retrieved by the surgical team during the surgical procedure only; however, case reports on the subject illustrate dislodgment into surgical wound, upper lip,¹⁴ submandibular space,¹⁵ intraosseous in the buccal cortical plate¹⁶ or even lost in the airway.⁶ These loose attachments may result in wound infection¹⁷ or space infection.

The failure of bonding and subsequent dislodgment of attachments may have significant adverse consequences (though uncommon).¹² A study has reported an incidence of 0.6% foreign body contamination in patients undergoing BSSRO and advocated that patients should be prior informed regarding bond failure and possible contamination and failure to do so may constitute negligence.⁷ Studies have advocated that bonded attachments should be avoided on terminal molars in orthognathic surgery patients due to the possibility of debonding during surgery, getting embedded/lost in spaces/airways causing infection and airway obstruction.⁶⁻⁸ In the present study, 02 molars tubes (0.25%) and 04 brackets (0.20%) were found embedded in the healing wound during follow-up radiographs and all cases were asymptomatic.

It was observed that bonding of molars, though a convenient procedure should be avoided for patients planning for an orthognathic surgical procedure, due to higher chances of bond failures during surgery and possible adverse consequences. Banded attachments on molars should be preferred in such cases.

7. Conclusions

With the findings of the present study, it can be deduced that the overall incidence of intra-operative bond failure is 4.75%. The bond failures of molar tubes are more frequent (7.3%) than brackets (3.7%), with more incidence during maxillary surgery (5.57%) as compared to mandibular surgery (3.92%). Among the various orthognathic surgical procedures studied, the maximum bond failures were noted for maxillary superior repositioning (5.85%) and the least for mandibular advancement surgery (3.6%). Banding of molars is a more cumbersome and time-consuming procedure as compared to bonding, however, for the safety of the patients, it is recommended to avoid the use of bonded molar tubes for patients planned for ortho-surgical correction.

8. Source of Funding

None.

9. Conflict of Interest


None.

References


- Buonocore MG. A simple method of increasing the adhesion of acrylic filling materials to enamel surfaces. *J Dent Res.* 1955;34(6):849–53.
- Mizrahi E. Orthodontic bands and directly bonded brackets: a review of clinical failure rate. *J Dent.* 1983;11(3):231–6.
- Murray PG, Millett DT, Cronin M. Bonded molar tubes: a survey of their use by specialist orthodontists. *J Orthod.* 2012;39(2):129–64.
- Gottlieb EL, Nelson AH, Vogels DS. Study of orthodontic diagnosis and treatment procedures. Part I results and trends. *J Clin Orthod.* 1996;30:615–44.
- Millett DT, Hallgren A, Fornell AC, Robertson M. Bonded molar tubes: a retrospective evaluation of clinical performance. *Am J Orthod Dentofac Orthop.* 1999;115(6):667–74.
- Filho JL, Godoy F, FO'Ryan. Orthodontic bracket lost in the airway during orthognathic surgery. *Am J Orthod Dentofac Orthop.* 2008;134(2):288–90.
- Teltzrow T, Kramer FJ, Schulze A, Baethge C, Brachvogel P. Perioperative complications following sagittal split osteotomy of the mandible. *J Cranio maxillofac Surg.* 2005;33(5):307–20.
- Wenger NA, Atack NE, Mitchell CN, Ireland AJ. Peri-operative second molar tube failure during orthognathic surgery: two case reports. *J Orthod.* 2007;34(2):75–84.
- Almosa N, Zafar H. Incidence of orthodontic brackets detachment during orthodontic treatment: A systematic review. *Pak J Med Sci.* 2018;34(3):744–75.
- Attishia R, Van Sickels J, Cunningham LL. Incidence of bracket failure during orthognathic surgery: a comparison of two techniques to establish interim maxillomandibular fixation. *Oral Maxillofac Surg.* 2015;19(2):143–50.
- Nazir M, Walsh T, Mandall NA, Matthew S, Fox D. Banding versus bonding of first permanent molars: a multi-center randomized controlled trial. *J Orthod.* 2011;38(2):81–9.
- Godoy F, Filho J, Rosenblatt A, O'ryan F. Prevalence of banding and bonding molar brackets in orthognathic surgery cases. *Oral Maxillofac Surg.* 2011;69(3):911–7.
- Pandis N, Christensen L, Eliades T. Long-term clinical failure rate of molar tubes bonded with a self-etching primer. *Angle Orthod.* 2005;75(6):1000–2.

14. Conti G, Dolci M, Borgonovo A, Maiorana C. Aesthetic restoration of the upper lip after removal of post-trauma foreign body (orthodontic bracket). *Eur J Paediatr Dent*. 2012;13(3):239–79.
15. De Queiroz S, Curioso PAB, Carvalho FSR, De Limab V. Submandibular-space abscess from loss of a bonded molar tube during orthognathic surgery. *Am J Orthod Dentofac Orthop*. 2013;143(5):735–42.
16. Chandra RV, Anumala N, Vikrant V. An asymptomatic orthodontic bracket in the mandibular alveolar bone region. *BMJ Case Rep*. 2013;2013. doi:10.1136/bcr-2013-009866.
17. Shaeran T, Samsudin AR. Dislodged bonded molar tube into the wound during orthognathic surgery. *Cas Rep Dent*. 2018;p. 1–4.

Author biography

Sanjeev Datana, Professor (Orthodontics)  <https://orcid.org/0000-0003-3950-4138>

SS Agarwal, Assistant Professor  <https://orcid.org/0000-0003-3950-4137>

ID Roy, Professor (OMFS)  <https://orcid.org/0000-0003-3950-4156>

Cite this article: Datana S, Agarwal SS, Roy ID. Bond failures of orthodontic attachments during orthognathic surgery: A retrospective study. *J Contemp Orthod* 2023;7(2):133-138.