

CASE REPORT

Msurgery First Orthognathic Approach for Management of Skeletal Class II Malocclusion with Facial Asymmetry

¹Abi Somaskandan

To cite: Abi Somaskandan

Msurgery First Orthognathic Approach for Management of Skeletal Class II Malocclusion with Facial Asymmetry

J Contemp Orthod 2020;4(2): 5-11.

Received on: 20-04-2020

Accepted on: 2-05-2020

Source of Support: Nil

Conflict of Interest: None

ABSTRACT

Surgical-orthodontic treatment of jaw deformities presents challenges in both diagnosis and mechanotherapy. The orthognathic approach has undergone a paradigm shift through the years, from correcting the skeletal component to addressing the soft tissues, thus optimizing aesthetic outcome. This case report presents a patient with a skeletal class II malocclusion with facial asymmetry who has been managed by surgical first orthognathic approach (SFOA). The treatment duration was decreased tremendously because of the Regional Acceleratory Phenomenon (RAP). The treatment outcome resulted in class I skeletal and dental relationships with phenomenal changes in correction of facial asymmetry attaining a pleasing facial profile and divergence.

KEYWORDS: Surgery First Orthognathic Approach (SFOA), Facial asymmetry, orthognathic surgery, Skeletal class II, Regional Acceleratory Phenomenon (RAP)

INTRODUCTION

Management of severe skeletal malocclusions in adults requires orthognathic surgery in combination with surgical orthodontics. Since the introduction of the mandibular sagittal split ramus osteotomy by Trauner and Obwegeser [1] in 1957 the modern era of orthognathic surgery has begun. Orthognathic surgery (OGS) has evolved a great deal over the last five decades and particularly in the past 10 years, this concept and technique of surgery-first orthognathic approach (SFOA) or Surgery-first approach (SFA) towards the correction of dentofacial anomalies is taking precedence over the conventional approach. The prolonged treatment phase of 7–47 months before and after OGS and a temporary worsening of facial appearance is a huge disadvantage of the conventional approach over SFA. SFOA offers minimal or no presurgical orthodontics and the shortest possible postsurgical orthodontic phase taking advantage of the regional acceleratory phenomenon with completion of treatment in approximately 6–12 months [2,3,4]. From a biological point of view, this concept is founded on the core principles of fracture healing: according to Frost's -biological theories, the healing environment created by the surgical wound could cause teeth and the periodontium to be susceptible to active orthodontic forces [5,6]. This concept finds clinical evidence in many studies, in which different authors described the regional acceleratory phenomenon (RAP): the metabolic pattern induced by a surgical wound can enhance bone turnover, thus gaining faster results in dentoalveolar movements [7,8]. This report describes the successful treatment of a case of Class II skeletal

malocclusion due to retrognathic mandible treated by maxillofacial surgery and orthodontics.

HISTORY

A 18 year old female patient reported to the Department of Orthodontics and Dentofacial Orthopaedics with chief complaint of forwardly placed upper front teeth. No history of illnesses or trauma was elicited by the patient. EXTRA ORAL ASSESSMENT: Clinical examination revealed Moderate built with Mesocephalic head type, Mesomorphic body type and mesoprosopic facial pattern. On extra oral examination, she had a convex profile with posterior divergence, Normal Nasolabial angle, low clinical FMA and mandibular shift towards the left by 5mm leading to mild asymmetry in lower third of the face. In the frontal view, during smile, the patient exhibited upper teeth visibility of 10 mm. INTRA ORAL ASSESSMENT: Intra oral examination revealed symmetrical, ovoid shaped maxillary and mandibular arch with proclined anteriors. Patient exhibited Class I Molar relationship on right side and end-on molar relationship on left side with bilateral end-on canine relationship. She had a class –II incisor relationship with increased overjet of 9mm and overbite of 9 mm with lower midline shifted to the left by 3mm. MODEL ANALYSIS: Model analysis revealed Relative Anterior mandibular tooth material excess by 2.8 mm relative Overall mandibular tooth material excess by 1.8mm. RADIOGRAPHIC ASSESSMENT: Pre-treatment Orthopantomogram (OPG) indicated that patient was in her permanent dentition stage with missing 18 and 28 and erupting 38 and 48. Cephalometric evaluation revealed Skeletal class II with orthognathic maxilla and retrognathic

mandible on a low mandibular plane angle and a horizontal growth pattern. The upper incisors and lower incisors were proclined. The upper posterior dentoalveolar heights and lower anterior facial height were found to be reduced. The Lower anterior facial height was reduced. No signs and symptoms of temporomandibular joint disorder were elicited through the questionnaire or clinical examination. Pre-treatment Poster-Anterior cephalometric analysis indicated that there was a mandibular shift towards the left by 5mm at the level of the body of the mandible. A positive Surgical Treatment Objective (STO) was obtained.

DIAGNOSIS









Based on the investigations, the patient was diagnosed as Angle’s dentoalveolar Class II Division 1 malocclusion on a Class II skeletal base with orthognathic maxilla and retrognathic mandible on a low mandibular plane angle with proclined upper and lower anteriors and increased overjet and overbite.

1. Conventional Orthodontic – Surgical management [9]
2. Surgery First Orthognathic Approach
3. Orthodontic Camouflage of the Class II skeletal base
 - Upper 1st premolar extractions bilaterally [1011]
 - Miniplate assisted distalization of maxillary dentition.

Considering the skeletal discrepancy of the upper and lower jaws, mandibular deviation suggesting yaw correction, short duration of treatment [12,13] and well aligned dental arches, surgical first orthodontic treatment mode of management was the treatment of choice. Pre-surgical orthodontics for levelling, aligning followed by Advancement Bilateral Sagittal Split Osteotomy of 7mm to address the mandibular deficiency and yaw correction of 3mm was done followed by post-surgical orthodontics for final settling and adjustments were to be carried out, to obtain a Class I occlusion.

PRE-TREATMENT (GRUMMONS ANALYSIS)	RIGHT	LEFT
Mandibular morphology (Co Ag Me)	135 ⁰ Co-Me : 101 mm Ag- Me : 46mm	127 ⁰ 93mm 38mm
Maxillomandibular comarison	J-MSR : 28.5 mm Ag- MSR : 36mm	26mm 32mm
Linear asymmetry assessment	Co-MSR: 50mm NC: 17mm	48mm 16mm
Me-MSR	Menton shifted to left by 5mm	

AIMS OF THE TREATMENT

-  To achieve ideal soft tissue profile
-  To correct skeletal discrepancy
-  To achieve ideal overbite
-  To align upper and lower arch
-  To achieve ideal vertical height
-  To achieve Class I molar and canine relation.
-  To achieve ideal overjet
-  To achieve ideal interincisal angle

TREATMENT ALTERNATIVES

Following assessment of the skeletal structures and its associated / contiguous soft tissue structures, the following treatment options were devised: -

TREATMENT PLAN

The following treatment plans were discussed with the patient considering the treatment objectives and correlating with patient’s requirements.

The initial treatment plan for the patient fulfilling the treatment objectives was an orthodontic-surgical combined approach. Cephalometric parameters revealed orthognathic maxilla and retrognathic mandible. Thus, advancement Bilateral Sagittal Split Osteotomy along with yaw correction was planned. The planned movements were derived from lateral cephalogram surgical treatment (STO) and confirmed with model surgery.

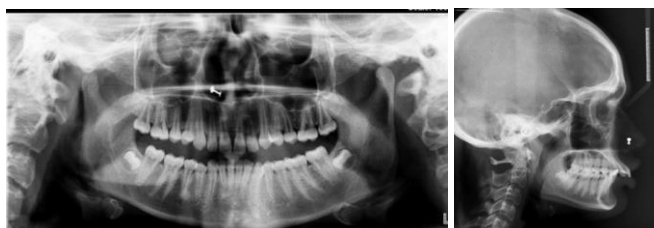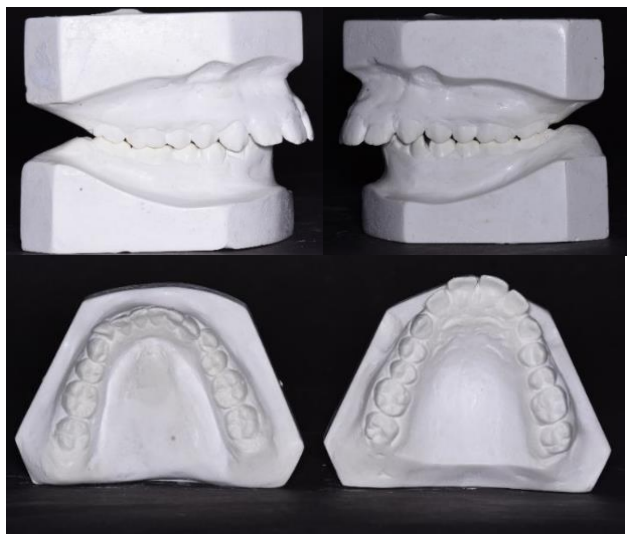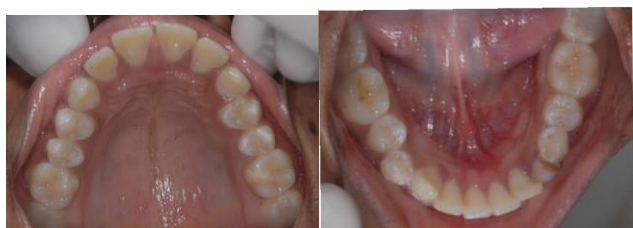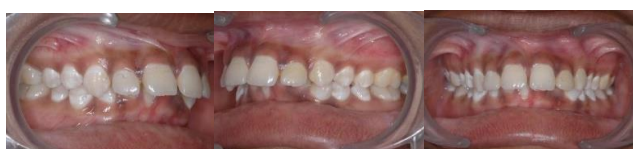Pre-surgical orthodontics for levelling, aligning followed by post-surgical orthodontics for final settling and adjustments were to be carried out, to obtain a Class I occlusion.

TREATMENT PROGRESS

A full orthodontic appliance, of 0.022” slot MBT system, was bonded first in the upper arch following which alignment and levelling was done sequentially with 0.016 NiTi, 16 × 22 NiTi

and 16 × 22 SS. The maxillomandibular relationship was registered using a Face Bow and transferred to the SAM III articulator and a surgical splint was fabricated. The lower arch strap up was done followed by placement of 0.016 SS.

PRE - TREATMENT



The patient was then subjected to surgery.

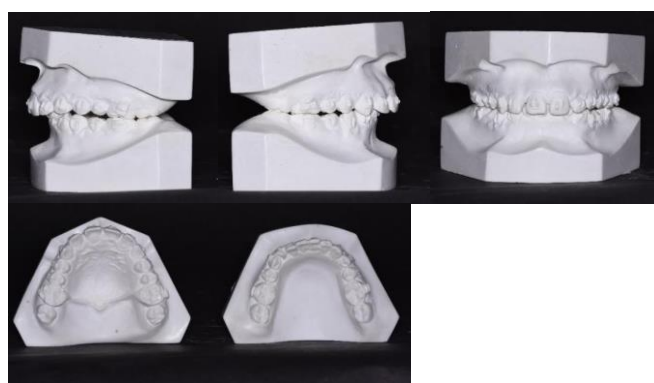
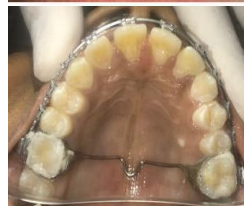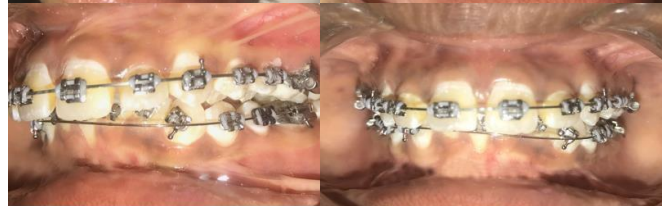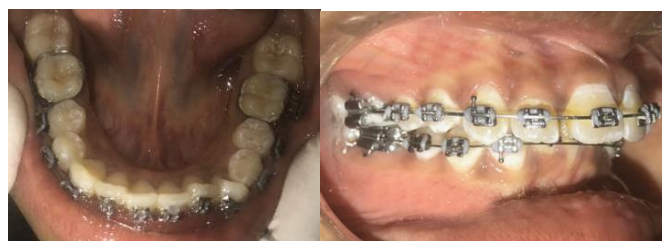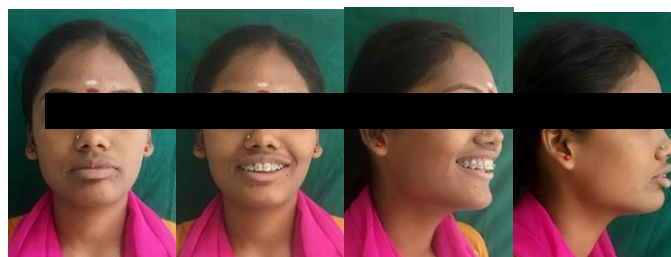The surgical phase comprised of Advancement Bilateral Sagittal Split Osteotomy of 7mm and 3mm of yaw correction was performed. 0.016 NiTi, 16 × 22 NiTi were placed

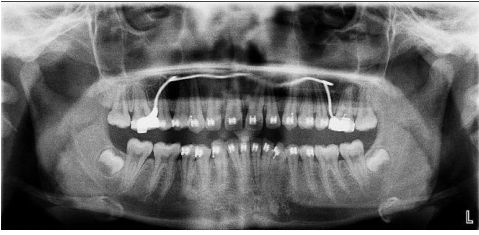
sequentially. Following this, 17x25 NiTi- 19x 25 NiTi and 21x25 SS were placed in both upper and lower arches.

Postsurgical orthodontics was continued after surgery to close the deep curve of spee. The goals of this phase of treatment were to rehabilitate and restore the neuromuscular function and achieve final occlusal settling. Settling of the occlusion was done on 0.018”ss arch wire with the help of settling elastics.

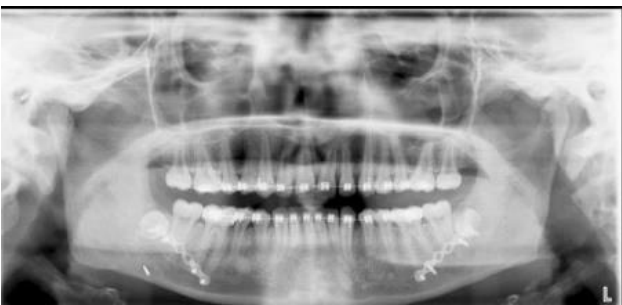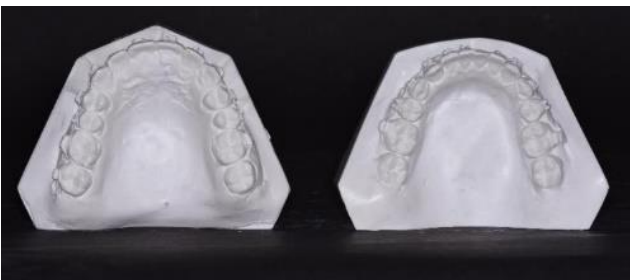
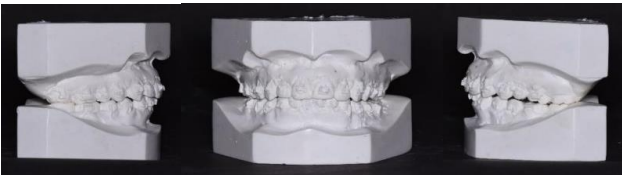
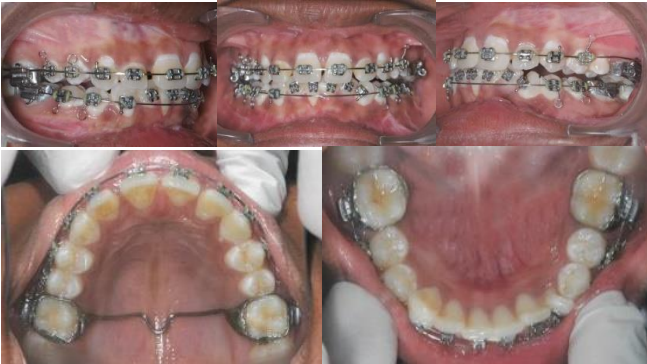In the retention phase, an anterior inclined plane was given to prevent relapse. Later, Upper Beggs wrap around retainer was delivered and a lower lingual retainer was bonded. The treatment was completed in 19 months.

PRE - Surgical

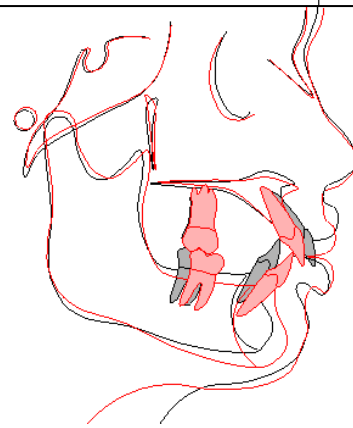




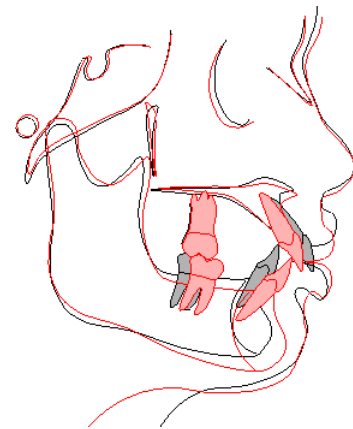
POST - SURGICAL



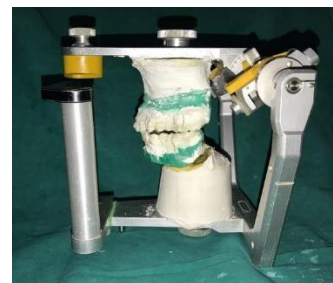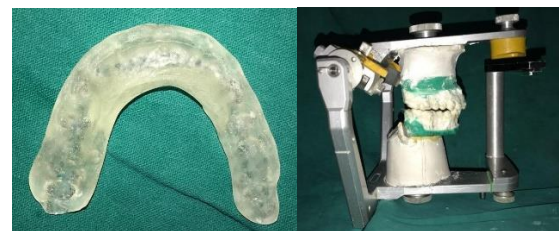SURGICAL TREATMENT OBJECTIVE



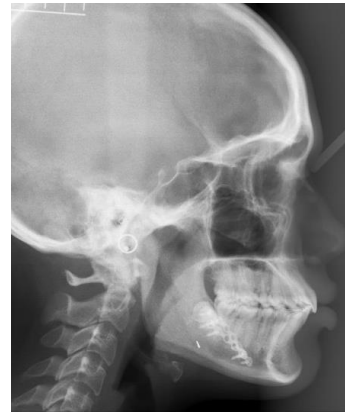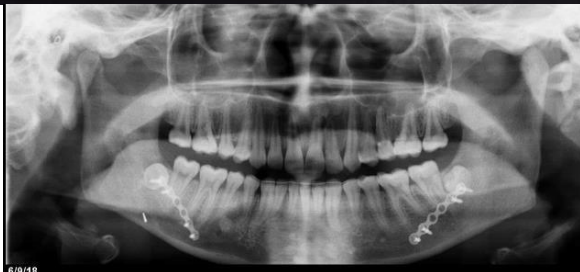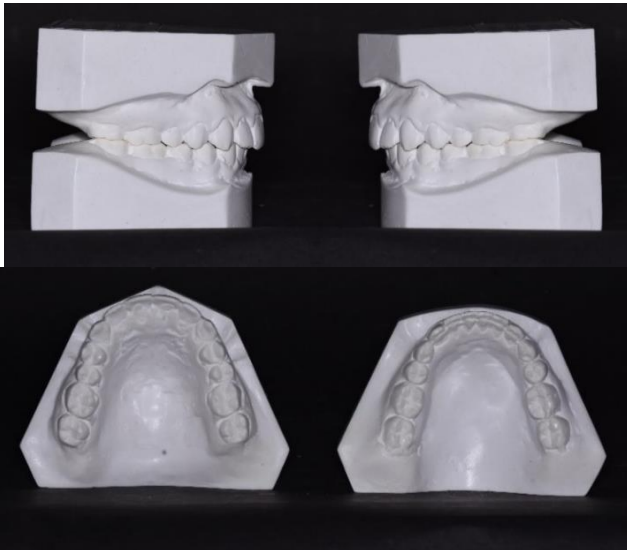
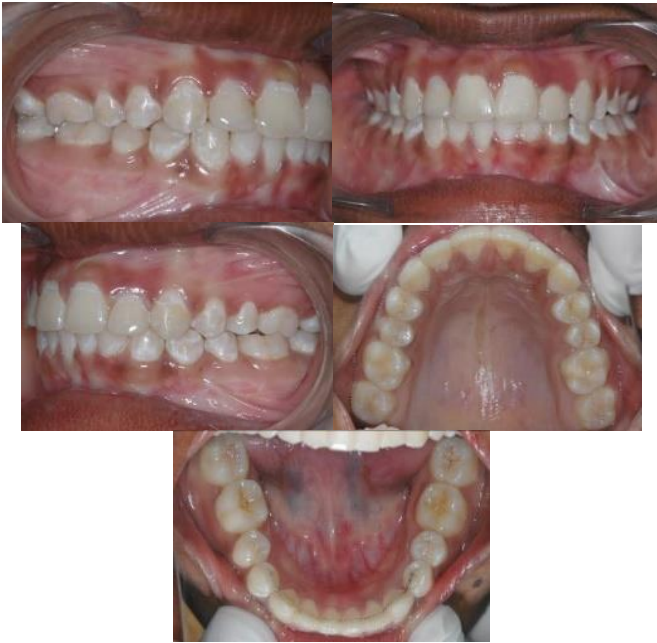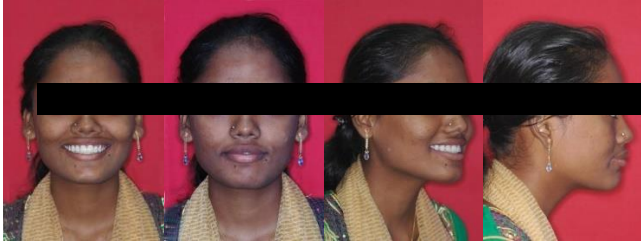SUPERIMPOSITION



MOCK SURGERY



POST - TREATMENT



SUMMARY

A 18 year old Female patient, came to the Department of Orthodontics with the chief complaint of forwardly placed upper front teeth. Extra oral examination revealed a convex profile and reduced lower facial height. Intra oral examination revealed, proclined upper anterior teeth and lower anterior teeth with missing. On cephalometric evaluation, skeletal Class II was evident with orthognathic maxilla and retrognathic mandible. Model analysis revealed no arch length-tooth material discrepancy. Surgical first orthographic approach was carried with mandibular advancement of 7 mm, followed by post-surgical orthodontics.

At the end of treatment, the assessment of the treatment outcomes showed well-aligned dentition. Extraorally, the patient demonstrated a harmonious smile and well-balanced facial profile and competent lips. Intraorally, the overjet and overbite were restored to normal and a stable Class I molar, Class I canine, matching midlines and good buccal intercuspsation were obtained.

Superimposition of the pre and post orthodontic cephalometric tracing illustrates the amount of skeletal correction achieved through surgery and its associated dental and soft tissue changes.

DISCUSSION

Severe skeletal malocclusions especially Class II, are frequently seen among the Indian population. A skeletal Class II patient with a short face and impinging bite typically develops an exaggerated curve of Spee and severely proclined lower incisors to compensate for the excessive overjet. By combining Orthodontics and Orthognathic surgery a refined and better treatment alternative can be provided to the patients with skeletal deformities[14,15]. In 1959, skaggs raised the issue of timing in relation to orthodontic treatment if a satisfactory interarch relationship can be achieved surgically. This is the first documented reference of "surgery first" technique. To overcome the disadvantages and inconveniences of presurgical orthodontics, surgery first orthognathic approach has been

introduced by Behrman and Behrman in 1988^[16]. The surgery-first approach has gained popularity as a new treatment concept for the management of dentomaxillofacial deformity.

According to Wilcko and colleagues, corticotomy can enhance tooth movement by increasing bone turnover and reducing bone density^[17]. Similarly, we speculate that bone

When surgery is performed first in such cases, the facial height is increased, and the occlusion will be unstable without presurgical orthodontics. Hence, a surgical splint is essential to guide repositioning of the mandible.

The final treatment outcome was highly successful as the enhancement of the facial esthetics combined with well-stable occlusion was established within a short duration of time.

VARIABLES	PRE TREATMENT	POST TREATMENT
SNA (°)	8 1	83
SNB (°)	7 4	81
ANB (°)	7	2
U1 TO NA mm	1 1	7
U1 TO SN	1 2 2	112
L1 TO B	4	4
IMPA (°)	1 0 2	95
INTERINCISAL ANGLE (°)	1 1 3	126
FMA (°)	1 9	21
LOWER ANTERIOR FACIAL HEIGHT	3 5	39
H LINE ANGLE (°)	7	10
NOSE TIP TO H LINE mm	9	12
LOWER LIP TO H LINE mm	5	3
BODY LENGTH Go-Me mm	6 7	73
Go-Pg mm	7 2	78

turnover after orthognathic surgery can significantly accelerate orthodontic tooth movement.

Class II malocclusion can be treated by a combination of maxillary and mandibular surgeries, maxillary surgery alone or by mandible surgery solely depending on the underlying skeletal discrepancy. Based on the clinical and cephalometric findings, the patient in this case report had a normal maxilla, retrognathic mandible with a class II relation. Hence, treatment of Class II malocclusion was by mandibular advancement surgery.

CONCLUSION

With the advances in techniques and refinement of surgical and orthodontic procedures, fast and efficient combined orthodontic-orthognathic.

Surgery treatment option can be offered to patients with skeletal deformities^[18]. Treatment of impaired facial esthetics in adults requires careful assessment of the underlying skeletal problem and often requires combined orthodontic surgical management. Furthermore, this approach offered conducive neuromuscular

overlay which along with a stable occlusion provided good postoperative stability. The future of orthognathic surgery is geared toward minimizing the overall treatment time without compromising the final results.

REFERENCES

- 1) Obwegeser H. The surgical correction of mandibular prognathism and retrognathia with consideration of genioplasty. *Oral Surg.* 1957;10:67
- 2) Hernandez-Alfaro F, Guijarro-Martinez R, Molina-Coral A, Badia- Escriche C. "Surgery first" in bimaxillary orthognathic surgery. *J Oral Maxillofac Surg* 2011;69:e201-7.
- 3) Hernandez-Alfaro F, Guijarro-Martinez R, Peiro-Guijarro MA. Surgery first in orthognathic surgery: what have we learned? A comprehensive workflow based on 45 consecutive cases. *J Oral Maxillofac Surg* 2014;72:376-90.
- 4) Baek S, Ahn HW, Kwon YH, Choi JY. Surgery-first approach in skeletal class III malocclusion treated with 2-jaw surgery: evaluation of surgical movement and postoperative orthodontic treatment. *J Craniofac Surg* 2010;21:332-8.
- 5) Frost hM. The biology of fracture healing. An overview for clinicians. Part I. *Clin Orthop Relat Res* 1989; 248: 283-293.
- 6) Frost hM. The regional acceleratory phenomenon: A review. *Henry Ford Hosp Med J* 1983; 31: 3-9.
- 7) liou eJ, chen Ph, wang yc, yu cc, huang cS, chen yr. Surgery-first accelerated orthognathic surgery: postoperative rapid orthodontic tooth movement. *J Oral Maxillofac Surg* 2011; 69: 781785
- 8) yu cc, chen Ph, liou eJ, huang cS, chen yr. A Surgery-first approach in surgical- orthodontic treatment of mandibular prognathism - a case report. *Chang Gung Med J* 2010; 33: 699-705.
- 9) Poulton DR, Ware HW. Surgical orthodontic treatment of severe mandibular retrusion. Part I. *Am J Orthod* 1971; 59:244-65.
- 10) Mihalik CA, Proffit WR, Phillips C. Long-term follow-up of Class II adults treated with orthodontic camouflage: a comparison with orthognathic surgery outcome. *Am J Orthod Dentofacial Orthop.* 2003;123:266–278.
- 11) Weaver N, Glover K, Major P, Varnhagen C, Grace M. Age limitation on provision of orthopedic therapy and orthognathic surgery. *Am J Orthod Dentofacial Orthop.* 1998;113:156–164.
- 12) Dowling, P.A.; Espeland, L.; Krogstad, O.; Stenvik, A.; and Kelly, A.: Duration of orthodontic treatment involving orthognathic surgery, *Int. J. Adult Orthod. Orthog. Surg.* 14:146•152, 1999.
- 13) Luther, F.; Morris, D.O.; and Hart, C.: Orthodontic preparation for orthognathic surgery: How long does it take and why?- A retrospective study, *Br. J. Oral Maxillofac. Surg.* 41:401•406, 2003.
- 14) Schubert P, Bailey LTJ, White RP, Proffit WR. Long-term cephalometric changes in untreated adults compared to those treated with orthognathic surgery. *J Adult Orthod Orthognath Surg.* 1999;14:91–99
- 15) Schendel SA, Epker N. Results after mandibular advancement surgery and analysis of 87 cases. *J Oral Surg.* 1980;38:255–282.
- 16) Behrman SJ, Behrman DA. Oral surgeons' considerations in surgical orthodontic treatment. *Dent Clin North Am* 1988;32:481-507.
- 17) Wilcko, W.M.; Wilcko, T.; Bouquot, J.E.; and Ferguson, D.J.: Rapid orthodontics with alveolar reshaping: Two case reports of decrowding, *Int. J. Period. Restor. Dent.* 21:9•19, 2001.
- 18) Liou EJ, Chen PH, Wang YC, Yu CC, Huang CS, Chen YR. Surgeryfirst accelerated orthognathic surgery: postoperative rapid orthodontic tooth movement. *J Oral Maxillofac Surg* 2011;69:781-5.