

## CASE REPORT

# Ortho-Surgical Management Of Skeletal Class III Malocclusion: Case Series

**To cite:** Jeegar Vakil, Ketan Vakil, Dhruvit N. Thakar  
Ortho-surgical management of Skeletal Class III malocclusion: Case series

J Contemp Orthod 2020;4(3): 1-8.

**Received on:** 20-07-2019

**Accepted on:** 23-09-2019

**Source of Support:** Nil

**Conflict of Interest:** None

<sup>1</sup>Jeegar Vakil, <sup>2</sup>Ketan Vakil, <sup>3</sup>Dhruvit N. Thakar

<sup>1</sup>MDS. M Orth RCS (Edinburgh), Diplomate - Indian Board of Orthodontics).

<sup>2</sup>MDS, Diplomate - Indian Board of Orthodontics.

<sup>3</sup>MDS, Oral & Maxillofacial Surgeon, Fellow - Head & Neck Oncology

## ABSTRACT

**Abstract:** Class III malocclusion is always challenging for the orthodontist. There are different methods to address the Class III malocclusion in growing patients, adolescents and adults. When the malocclusion is very severe and beyond the scope of orthodontics alone, ortho-surgical approach is considered to correct the underlying skeletal deformity. This article is a description of two cases treated with bi-jaw surgery to achieve the desired treatment outcome.

**Keywords:** Orthognathic surgery, Skeletal Class III malocclusion, Bi-jaw surgery Adult orthodontics, Inter-disciplinary orthodontics.

## INTRODUCTION

The prevalence of Angle's Class III malocclusion varies among and within the population, ranging from 0% to 26%.<sup>1</sup> In the Indian population, the prevalence rate is 1.2%.<sup>2</sup> Ellis and McNamara<sup>3</sup> found a combination of mandibular prognathism and maxillary retrognathism to be the most common skeletal relationship. Severe skeletal Class III affects the facial aesthetics apart from having improper dental occlusion. When the severity is beyond the scope of orthodontics alone, inter-disciplinary approach is adopted using the skills and expertise of the maxillofacial surgeon. This article describes the treatment of two patients treated using orthosurgical approach to provide satisfactory treatment outcome.

### Case 1: Patient name: V.B

Pre-treatment assessment: V.B, a 19 year old female reported with the chief complaint of forwardly placed lower front jaw. Extra-oral examination revealed symmetric face, concave profile, mid-face deficiency and a prominent chin. (Fig 1 a-c).



Fig1 (a-c) Pre-treatment extra-oral

Intraoral examination showed Angle's Class III molar relationship, overjet and overbite of (-2 mm), spacing between the teeth. The incisor relation was Class III. The teeth were well aligned in the arches. (Fig 2 a-e)

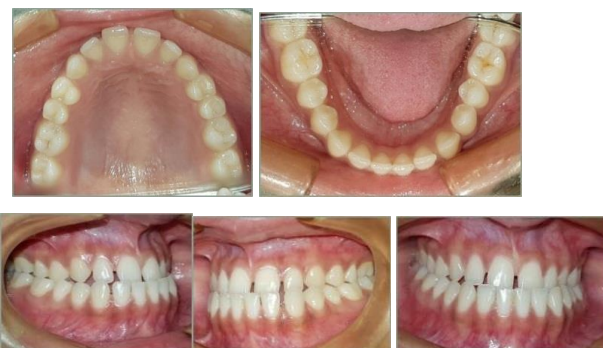
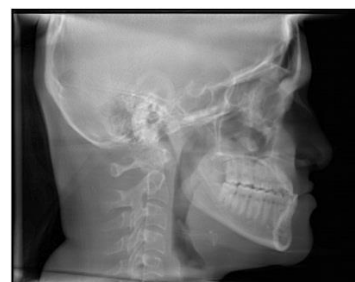
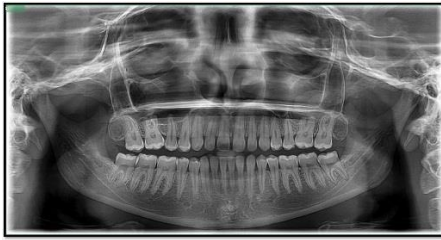Fig2 (a-e) Pre-treatment intra-oral photographs

### Pre-treatment radiographic analysis:

Pre-treatment lateral cephalogram (Fig 3 a) indicates





skeletal Class III pattern with retropositioned maxilla and prognathic mandible. The patient had a

Fig 3b : Pre-treatment Orthopantomogram

**DIAGNOSIS**

Skeletal Class III jaw base relation due to prognathic mandible and retrognathic maxilla, with hypodivergent growth pattern. Dentally, Angle’s Class III molar relation bilaterally, negative overjet and overbite and procumbent lower lip.

Variable	Pre-Treatment	Pre-surgical	Post-treatment
<b>Sagittal skeletal relation</b>			
SNA	79 <sup>0</sup>	78	<b>83<sup>0</sup></b>
SNB	85 <sup>0</sup>	85 <sup>0</sup>	<b>82<sup>0</sup></b>
ANB	-6	-7	<b>1<sup>0</sup></b>
Wits appraisal	-6	-6	<b>-2</b>
<b>Dental relationship:</b>			
U1-NA(mm/deg)	5 mm /38 <sup>0</sup>	4 mm/ 37 <sup>0</sup>	<b>4 mm/32<sup>0</sup></b>
L1-NB (mm/deg)	2 mm / 22 <sup>0</sup>	2 mm/23 <sup>0</sup>	<b>2MM/22<sup>0</sup></b>
U1-SN plane	122 <sup>0</sup>	123 <sup>0</sup>	<b>123<sup>0</sup></b>
L1-mandibular plane (IMPA)	85 <sup>0</sup>	88 <sup>0</sup>	<b>89<sup>0</sup></b>
Inter-incisal angle	125 <sup>0</sup>	124 <sup>0</sup>	<b>123<sup>0</sup></b>
Lower incisor to A-pog line	1 mm		
Overjet	-3 mm	-5 mm	<b>+2 mm</b>
Overbite	-1 mm	-1 mm	<b>+1 mm</b>
<b>Vertical skeletal relationship:</b>			
Maxillary-mandibular plane angle	24 <sup>0</sup>	25 <sup>0</sup>	<b>27<sup>0</sup></b>
FMA	22 <sup>0</sup>	24 <sup>0</sup>	<b>25<sup>0</sup></b>
Y axis	58 <sup>0</sup>	60 <sup>0</sup>	<b>62%</b>
Jarabak ratio	67%	68%	<b>68%</b>
<b>Soft-tissues:</b>			
Upper lip to Rickett’s E plane	-5 mm	-5 mm	<b>-3 mm</b>
Lower lip to Rickett’s E plane	-3 mm	-3 mm	<b>-2 mm</b>
Nasolabial angle	103 <sup>0</sup>	104 <sup>0</sup>	<b>96<sup>0</sup></b>

**Table 1: Comparison of Pre-treatment, pre-surgical and post-treatment cephalometric analysis.**

hypodivergent growth pattern. Maxillary anteriors were proclined and mandibular anteriors were upright. (Table 1)

Orthopantomogram (OPG) (Fig 3b) showed presence of 3<sup>rd</sup> molars (38, 48) in the lower arch.

**OBJECTIVES**

The specific objectives of present study were to evaluate the association of tongue posture (measured as the tongue-to-palate distance), and upper airway parameters (measured as

Velopharyngeal Airway Space (VAS), Posterior Airway Space (PAS) and Hypopharyngeal Airway Space (HAS)) with the maxillary dental morphology (measured by inter canine and inter molar widths) in a group of skeletal Class II malocclusion subjects in comparison to a group of Class I malocclusion (normal) subjects.

Problem list:

1. Concave profile
2. Skeletal Class III jaw base relation
3. Angle's Class III molar relation
4. Negative overjet and overbite
5. Anterior crossbite
6. Spacing between the teeth

### Treatment planning

The treatment plan was orthodontics along with orthognathic surgery. Case was treated non-extraction. Decompensation was done to correct the inclination of incisors with respect to the jaws. Bi-jaw surgery was performed (maxillary advancement and mandibular setback).

### Treatment progress

The case was treated non-extraction (except that 38 and 48 were removed). 0.018 x0.025 “ MBT brackets with hooks on posterior teeth were used. Inter-dental spaces were closed and negative overjet was increased (-4 mm), as a part of orthodontic decompensation. Pre-surgical extraoral photographs (Fig 4 a-c), intra-oral photographs (Fig 5 a-e) and pre-surgical lateral cephalogram (Fig 6) are indicative of the decompensation.

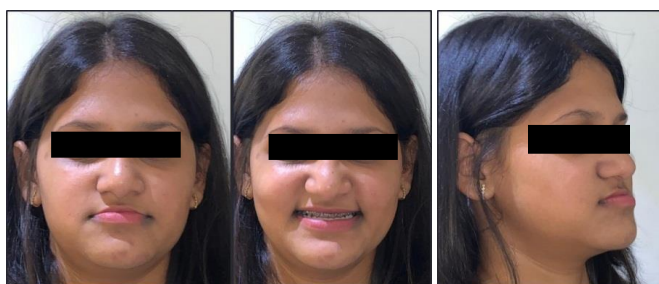

Fig 4 a-c: Pre-surgical extraoral photographs

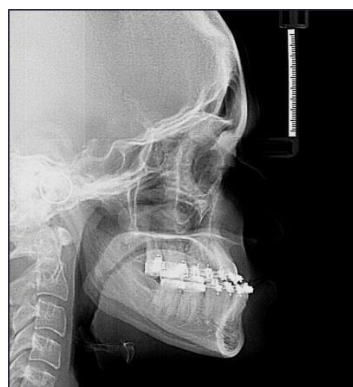
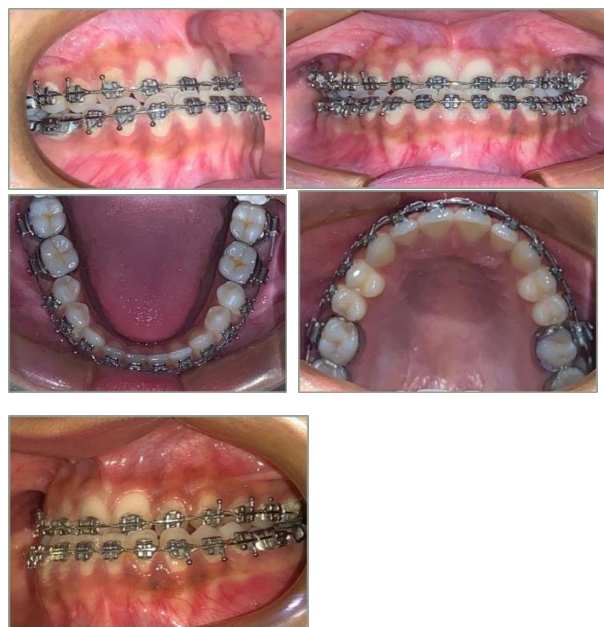
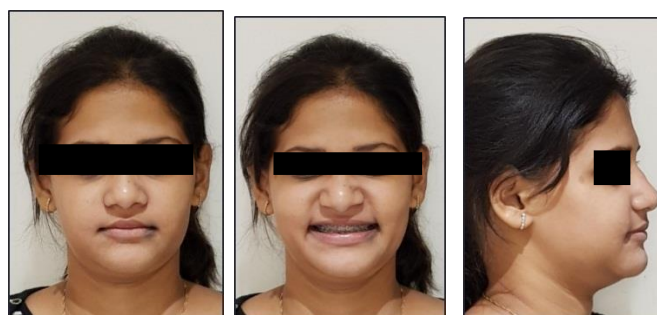
Fig 5 a-e: Pre-surgical intraoral photographs

Fig 6: Pre-surgical lateral cephalogram

### Post-surgical management

Bi-jaw surgery comprising of maxillary advancement of 6 mm and mandibular setback of 4 mm was done. For 5-6 weeks, Class III elastics were advised to prevent relapse post-surgically. Vertical settling elastics were given after sectioning the



archwire, to allow occlusal settling. Figures 7 (a-c) and 8 (a-e) are indicative of post-surgical phase of treatment.

Fig 7 (a-c) Post-surgical extra-oral photographs

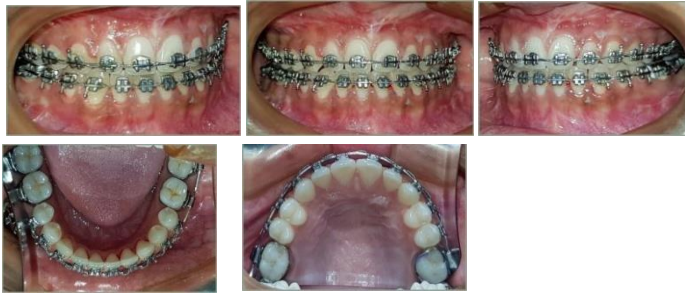

Fig 8 (a-e) Pre-surgical extra-oral photos

**Post-Treatment assessment:**

There was great improvement in patient’s facial profile and overall facial aesthetics. Patient had ideal overjet and overbite at the end of treatment. The case was finished in Class I molar, canine and incisor relation. Soft-tissue balance was well achieved. Figures 9(a-c) and 10 (a-e) depict post-treatment photographs of the patient.

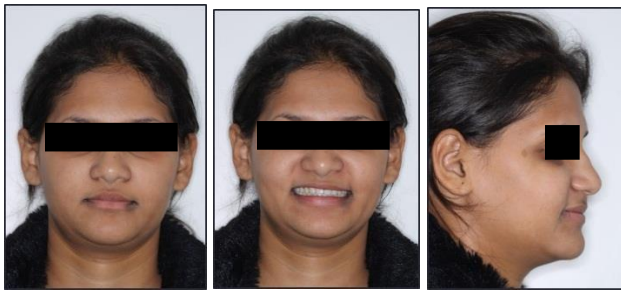

Fig 9 (a-c) Post-treatment extra-oral photographs

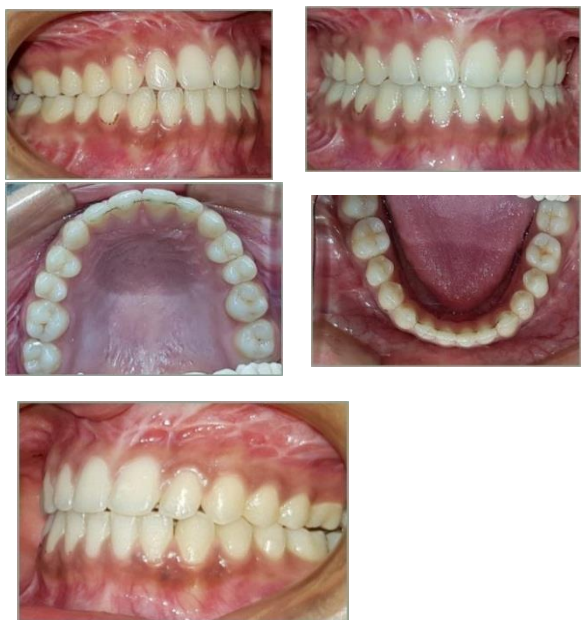

Fig 10 (a-e) Post-treatment extra-oral photographs

**Post treatment Cephalometric assessment:**

Post-treatment lateral cephalogram (Fig 11 a) indicates that skeletally, ANB value improved from  $-6^{\circ}$  to  $+1^{\circ}$  and

Wit’s changed from  $-6$  mm to  $-1$  mm, thus showing marked improvement in skeletal Class III malocclusion. Post-treatment orthopantomogram is shown in Fig 11 b. Cephalometric super-impositions (Figure 12 a,b) showed relevant changes in maxilla and mandible before and after orthognathic surgery. Lower lip procumbency reduced. (Table 1)

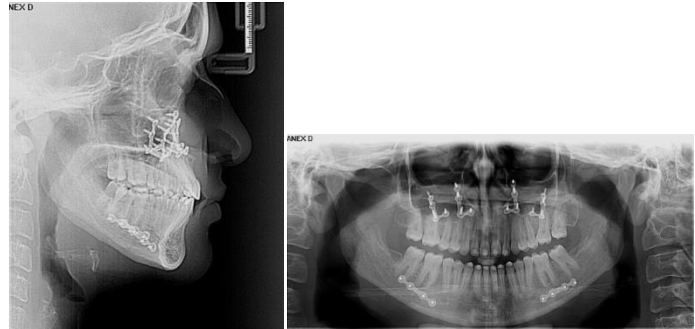


Fig 11 a-Post-treatment lateral cephalogram and 11 b-Post-treatment Orthopantomogram.

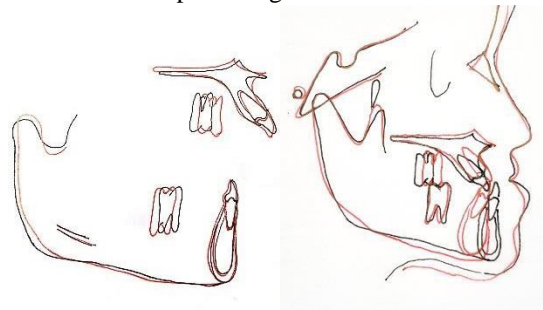


Fig 12 (a,b) Cephalometric superimpositions

**CASE 2: PATIENT NAME – A.M**

**Pre-treatment assessment:**

AM , a 20 year old male reported with the chief complaint of forwardly placed lower front jaw. Extraoral examination revealed symmetric face, concave profile, midface deficiency and a prominent chin. (Fig 13 a-c)

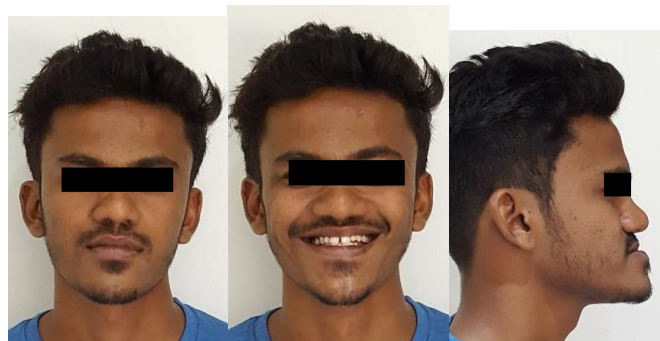
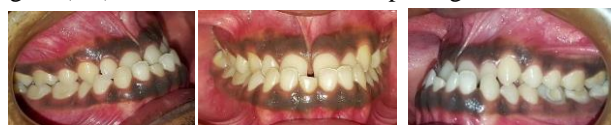
Fig 13 (a-c) Pre-Treatment extra-oral photogr



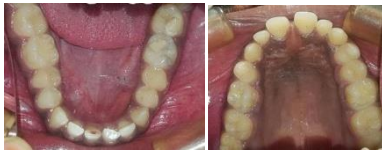

Fig 14 (a-e) Pre-treatment intra-oral photographs

Intraoral examination showed Angle's Class III molar relationship, overjet and overbite of (-2 mm), spacing between upper anteriors. The incisor relation was Class III. The teeth were well aligned in the arches. 1st premolar was missing in the upper right quadrant. Upper lateral incisors were smaller mesio-distally. Lower central incisor (41) was fractured.(Fig 14 a-e).

### Pre-treatment radiographic analysis:

Pre-treatment lateral cephalogram (Fig 15 a) indicates skeletal Class III pattern with retropositioned maxilla and prognathic mandible. The patient had a hypodivergent growth pattern. Maxillary anteriors were proclined and mandibular anteriors were retroclined. (Table 2)

Orthopantomogram (OPG) (Fig 15b) showed presence of 3rd molars in all 4 quadrants. Root canal treatment was done in the lower incisor (41).

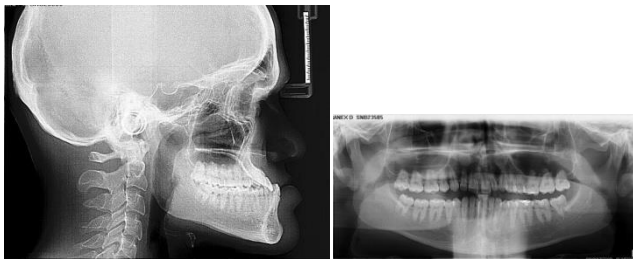


Fig 15 a Pre-Treatment Lateral cephalogram and 15 b- Pre-treatment Orthopantomogram

Table 2: Comparison of Pre-treatment, pre-surgical and post-treatment cephalometric analysis.

### DIAGNOSIS

Skeletal Class III jaw base relation due to prognathic mandible and retrognathic maxilla, with hypodivergent growth pattern. Dentally, Angle's Class III molar relation bilaterally, negative overjet and overbite and procumbent lower lip.

#### Problem list:

1. Concave facial profile
2. Skeletal Class III jaw base relation
3. Angle's Class III molar relation
4. Negative overjet and overbite
5. Anterior crossbite.

### Treatment planning:

The treatment plan was orthosurgical. Case was treated by extraction of 1<sup>st</sup> premolar in upper left quadrant and all 3<sup>rd</sup> molars were removed prior to the surgery. Decompensation was done to correct the inclination of incisors with respect to the jaws. Bi-jaw surgery was performed (maxillary advancement and mandibular setback).

### Treatment progress:

0.018 x 0.025 " MBT brackets with hooks on posterior teeth were used. Inter-dental spaces and extraction space of 24 were closed and negative overjet was increased (- 5mm), as a part of orthodontic decompensation. Upper midline was corrected in relation to the facial midline. Pre-surgical extraoral photographs (Fig 16 a-c), intra- oral photographs (Fig 17 a-e) and pre-surgical lateral cephalogram (Fig 18) are indicative of the decompensation.

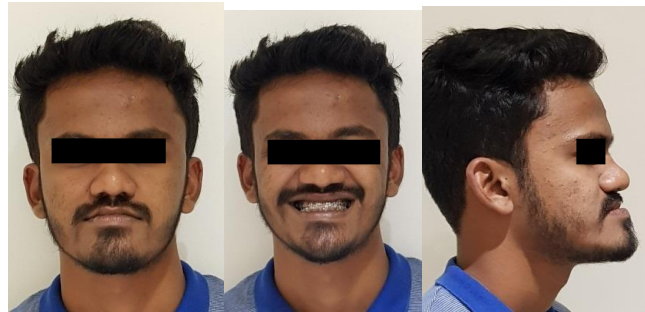

Fig 16 (a-c) Pre-surgical extra-oral photographs

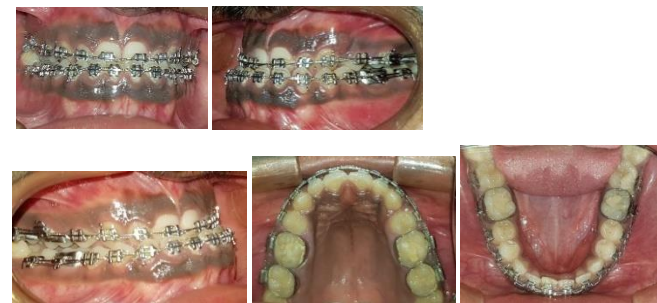

Fig 17 (a-e) Pre-surgical intra-oral photographs

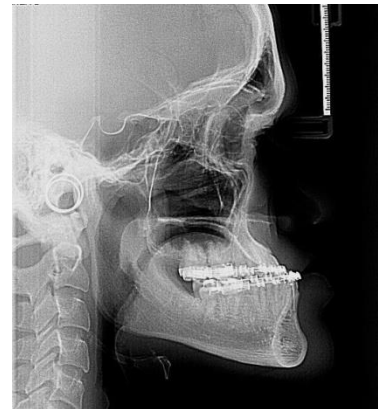

Figure 18- Pre-surgical lateral cephalogram

### Post-surgical management:

Bi-jaw surgery comprising of maxillary advancement of 7 mm and mandibular setback of 5 mm was done. For 6 weeks, Class III elastics were advised to prevent relapse post-surgically. Reposition of brackets was done, which was followed by vertical settling elastics for better finishing.

Figures 19 (a-c) and 20 (a-e) are indicative of post-surgical phase of treatment.

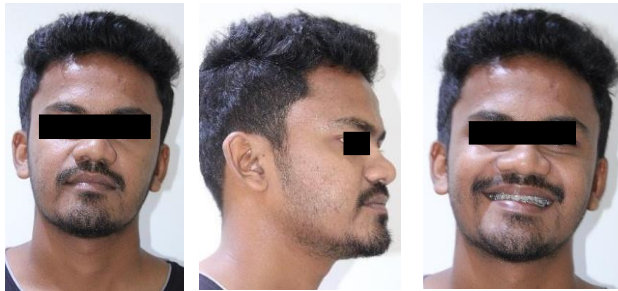

Fig 19 (a-c) Post-surgical extra-oral photographs

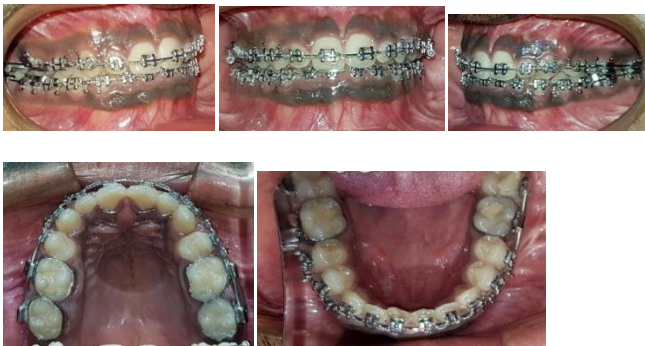

Fig 20: Post-surgical intra-oral photographs

### Post-Treatment assessment:

There was great improvement in patient's facial profile and overall facial aesthetics. Patient had ideal overjet and overbite at the end of treatment. The case was finished in Class II molar, Class I canine and incisor relation respectively. Occlusion was well settled and midlines were coincident. Soft-tissue balance was well achieved. Figures 21(a-c) and 22 (a-e) depict post-treatment photographs of the patient.



Fig 21 (a-c): Post-treatment extra-oral photographs

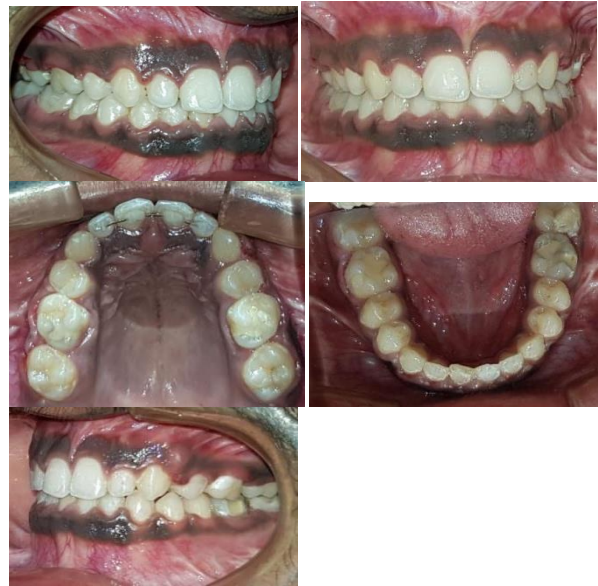

Fig 22 (a-e): Post-treatment intra-oral photographs

### Post-treatment Cephalometric assessment:

Post-treatment lateral cephalogram (Fig 23 a) depict that skeletally, ANB value improved from  $-13^{\circ}$  to  $-2^{\circ}$  and Wit's changed from  $-10^{\circ}$  mm to  $-5$  mm, thus showing marked improvement in skeletal Class III malocclusion. Maxillary incisor inclination improved from  $41^{\circ}$  to  $33^{\circ}$ . Post-treatment Orthopantomogram is shown in fig 23 b. Cephalometric superimpositions (Figure 24 a-c) showed relevant changes in maxilla and mandible before and after orthognathic surgery. Lower lip procumbency reduced. (Table 2)

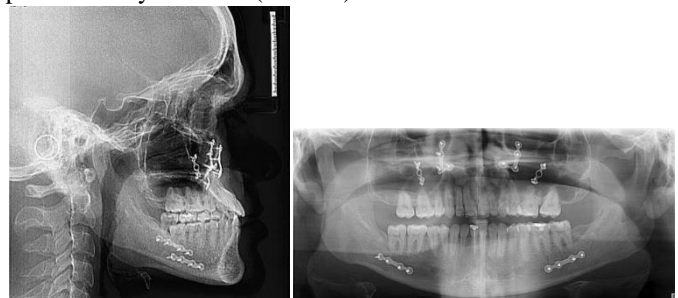


Fig 23: (a) Post-treatment lateral cephalogram and (b) Post-treatment orthopantomogram




Fig 24 (a-c) Cephalometric superimpositions

### DISCUSSION

Ortho-surgical treatment becomes the only option for severe adult skeletal Class III cases to achieve ideal facial and dental correction. Since the problem is skeletal, it gets reflected in the facial appearance of the patient. Hence, self-esteem becomes

an important factor to be considered during initial consultation of an ortho-surgical case.

just where it was put in about 80% of patients, and there is almost no tendency for major relapse (4 mm or more). With rigid fixation, the combination of maxillary advancement and

Variable	Pre-Treatment	Pre-surgical	Post-treatment
<b>Sagittal skeletal relation</b>			
SNA	83 <sup>0</sup>	81 <sup>0</sup>	89 <sup>0</sup>
SNB	96 <sup>0</sup>	96 <sup>0</sup>	91 <sup>0</sup>
ANB	-13 <sup>0</sup>	-15 <sup>0</sup>	-2 <sup>0</sup>
Wits appraisal	-10	-12	-5 mm
<b>Dental relationship:</b>			
U1-NA(mm/deg)	41 <sup>0</sup> / 5 mm	38 <sup>0</sup> /7 mm	33 <sup>0</sup> /5 mm
L1-NB (mm/deg)	10 <sup>0</sup> / 0 mm	9 <sup>0</sup> / 0 mm	9 <sup>0</sup> /0 mm
U1-SN plane	130 <sup>0</sup>	132 <sup>0</sup>	122 <sup>0</sup>
L1-mandibular plane (IMPA)	80 <sup>0</sup>	78 <sup>0</sup>	78 <sup>0</sup>
Inter-incisal angle	142 <sup>0</sup>	139 <sup>0</sup>	141 <sup>0</sup>
Lower incisor to A-pog line	6 mm	7 mm	4 mm
Overjet	-2 mm	-5 mm	2 mm
Overbite	-3 mm	-2 mm	1.5 mm
<b>Vertical skeletal relationship:</b>			
Maxillary-mandibular plane angle	10 <sup>0</sup>	12 <sup>0</sup>	15 <sup>0</sup>
FMA	15 <sup>0</sup>	16 <sup>0</sup>	17 <sup>0</sup>
Y axis	52 <sup>0</sup>	53 <sup>0</sup>	53 <sup>0</sup>
Jarabak ratio	81.6%	80%	80%

Surgical orthodontic treatment in Class III patients comprehends a pre-surgical orthodontic treatment to decompensate the malocclusion, followed by surgery and detailed finishing of the occlusion. The pre-surgical phase increases the severity of dental malocclusion and often results in a less pleasant facial profile. The lack of optimal dental compensation compromises the quality and quantity of the correction.<sup>4</sup>

mandibular setback is acceptably stable. In contrast, isolated mandibular setback is often unstable. Condylar sagging during the mandibular surgery is common because the patient is in a supine position during the surgery, and the condyles sag posteriorly in their sacs. The condyles reposition after intermaxillary fixation is removed, and the mandible moves anteriorly, mimicking surgical relapse. This is also true for downward movements of the maxilla that create downward-backward rotations of the mandible. For this reason, almost all

<b>Soft-tissues:</b>			
Upper lip to Rickett's E plane	-5 mm	-6 mm	-5 mm
Lower lip to Rickett's E plane	0 mm	0 mm	-2 mm
Nasolabial angle	107 <sup>0</sup>	110 <sup>0</sup>	99 <sup>0</sup>

Stability has been an important factor for all orthodontic corrections and ortho- surgical correction is no exception. Jakobson G et al, in a three year follow-up study in Class III patients who were treated with bimaxillary surgery concluded that there was good occlusal stability in all the patients. Skeletal stability varied depending on the direction and amount of surgical movements.<sup>5</sup>

In the treatment of Class III patients, the maxilla remains

Class III patients now have maxillary advancement, either alone or (more frequently) combined with mandibular setback.<sup>6</sup>

### Conclusion:

Adult skeletal class III cases present with a great challenge to the orthodontist. Due to the underlying skeletal discrepancy, ideal correction lies beyond the scope of orthodontics alone. We require the expertise of the maxillofacial surgeon to achieve the desired treatment result. The treatment results of

the two patients described in the case report is an attempt by the clinician to showcase the inter-disciplinary approach in treating severe Class III cases.

### References:

1. Hardy DK, Cubas YP, Orellana MF. Prevalance of Angle Class III malocclusion: a systematic review and meta-analysis. *Open J Epidemiol* 2012;2:75-82.
2. Gauba K, Ashima G, Tewari A, Utrja A. Prevalance of malocclusion and abnormal oral habits in North Indian rural children. *J Indian Soc Pedod Prev Dent* 1998;16:26-30.
3. Ellis E, Mcnamara JA Jr. Components of adult class III malocclusion. *J Oral Maxillofac Surg* 1984;42(5):295-305.
4. Leon-Salazar V, Janson G, de Freitas MR, de Almeida RR, Leon-Salazard R. Non- extraction treatment of skeletal Class III malocclusion. *Am J Orthod Dentofacial Orthop* 2009;136:736-745.
5. Jakobsone G, Stenvik A, Sandvik L, Espeland L. Three year follow-up of bimaxillary surgery to correct skeletal Class III malocclusion. Stability and risk factors for relapse. *Am J Orthod Dentofacial Orthop* 2011;139:80-89.
6. Ngan P, Moon W. Evolution of Class III treatment in Orthodontics. *Am J Orthod Dentofacial Orthop* 2015;148:22-36)