

CASE REPORT

Management of Unilateral Posterior Crossbite A Case Report

¹Ajit Jaiswal, ²J.P.S. Kalra, ³Jasmeet Kaur Ryait

¹Professor, ²Professor & Head, ³SENIOR LECTURER

^{1,2,3}Department Of Orthodontics And Dentofacial Orthopaedics B.J.S. Dental College Hospital And Research Institute Ludhiana, Punjab.

To cite: Ajit Jaiswal,
J.P.S. Kalra, Jasmeet
Kaur Ryait

Management Of Unilateral
Posterior Crossbite A
Case Report

J Contemp Orthod 2020;4(3):
16-23

Received on:
11-07-2020

Accepted on:
15-08-2020

Source of Support: Nil

Conflict of Interest: None

ABSTRACT

INTRODUCTION

Posterior Cross bite is malocclusion in transverse dimension. It is one of the most prevalent malocclusions in the primary and early mixed dentition and is reported to occur between 8% and 22%.¹⁻⁴. In most cases, the crossbite is accompanied by a mandibular shift, a so called forced crossbite, which causes midline deviation², Factors involved in the etiology of the crossbite, besides heredity, are sucking habits and impaired nasal breathing caused by, for example, enlarged tonsils and adenoids. It has been observed that untreated posterior crossbite may lead to craniofacial asymmetry and risk of damage to the temporomandibular joint (TMJ), the symptoms of which could include pain, clicking or locking of the TMJ.⁷

Cross bite can be of two types unilateral and bilateral and can be single tooth or complete arch. In true unilateral posterior crossbite, the aim should be to move selected teeth on the constricted side of the maxillary arch. If conventional expansion appliances are used to treat true unilateral posterior crossbite, then the maxillary dental arch will be expanded bilaterally, resulting in undesirable overexpansion of the unaffected side⁸.

Complete posterior cross bites are difficult to treat especially the unilateral one, since most of the expansion appliances are designed to expand the maxillary arch bilaterally which ideally suits for treatment of bilateral cross bite, however unilateral cross bite can be treated with these appliances by judicious differential activation and by controlling the untoward side effects. This case report describes the

management of 13 year old female patient with unilateral posterior cross bite by judicious unilateral activation of quad helix.

CASE REPORT

A 13 Years old female patient (M.J) reported to dept of orthodontics with chief complain of upper right side back teeth placed inside and unable to chew properly. She had class II skeletal pattern and Angles class II div1 subdivision (right side) malocclusion with unilateral complete cross bite. she has mesocephalic head, mesoprosopic facial form, straight profile, straight divergence and no apparent gross asymmetry with average growth pattern (Figure1-3).Soft tissue examination revealed potentially competent Lips, average nasolabial angle and mento-labial sulcus. Her upper dental midline was matching with facial midline while lower dental midline was shifted to right side. There was no gross facial asymmetry noticed. After through clinical examination it was found that the cross bite was dental in nature hence maxillary expansion was planned. Since patient age was favourable and palatal sutures were not completely fused slow maxillary expansion was selected. Since most of SME appliances were meant for bilateral expansion hence routine activation results in unwanted expansion of normal side. Hence quad helix was chosen to apply differential activation to correct unilateral cross bite with minimal expansion of normal side. Once desired result was achieved, the appliance was kept for another 4 months for retention. After that fixed mechanotherapy with 0.022 M.B.T appliance was continued for correction of space closure and midline discrepancy. After 21 months of treatment upper and lower fixed retention was done and upper removable retainer was

given.

Section 1 Pre Treatment Assessment

Initials: M.J

Sex: Female

Date of birth: 30-03-2005

Age at start of treatment: 13 Years

PATIENT'S COMPLAINTS: Upper right side back teeth placed inside and unable to chew properly on right side.

RELEVANT MEDICAL HISTORY: Not Significant

SKELETAL ASSESSMENT

Anteroposterior -Class II skeletal relation with normal maxillo-mandibular differential.

Vertical - Hypodivergent growth pattern with reduced SN-MP angle. Interlabial gap of 3mm was noticed at rest.

Transverse: Mesoprosopic facial form with acceptable facial symmetry and balance on frontal examination. Ashley Howe's and Pont's analysis shows that basal arch width (PMBAW) was more than premolar diameter (PMD) which indicated possibility of expansion. Upper dental midline was matching with facial midline, while Lower dental midline shifted to right.

SOFT TISSUE ASSESSMENT

Upper and lower lip had normal tonicity. Lip strain of 2 mm was present potentially competent Lips with inter labial gap of 3 mm was present Her nasolabial angle and mento-labial sulcus was average. 2 mm of gingiva was visible in central incisor area.

Clinical Features: Extra oral



Figure 1:Pre treatment extra oral features (a) Frontal view at rest ; (b) Frontal view at smile;(c) Right Profile view

CLINICAL EXAMINATION: INTRAORAL FEATURES

Soft tissues: No Abnormality detected

Oral hygiene: fair

Erupted teeth present:

7	6	5	4	3	2	1	1	2	3	4	5	6	7
7	6	5	4	3	2	1	1	2	3	4	5	6	

General dental condition: Fair

CROWDING / SPACING

Maxillary arch: Arch was v shaped and asymmetric. Vault was high .11 and 21 were mildly proclined while 12 and 22 were slightly retroclined.Mild crowding was present in relation to12 and 22. Upper right buccal segment (13, 14, 15 and 16) was placed palatally.

Mandibular arch: U shaped and asymmetric. Mild lower anterior crowding was present in incisors area.

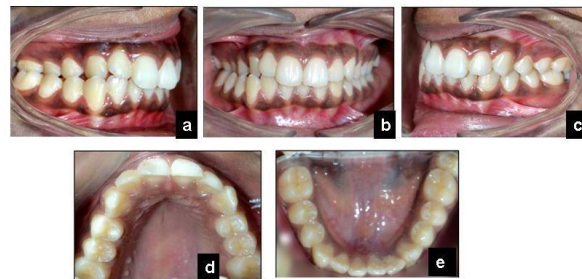

Figure 2. Pretreatment intraoral photographs: (a) right buccal view; (b) anterior view; (c) left buccal view; (d) maxillary occlusal view; and (e) mandibular occlusal view

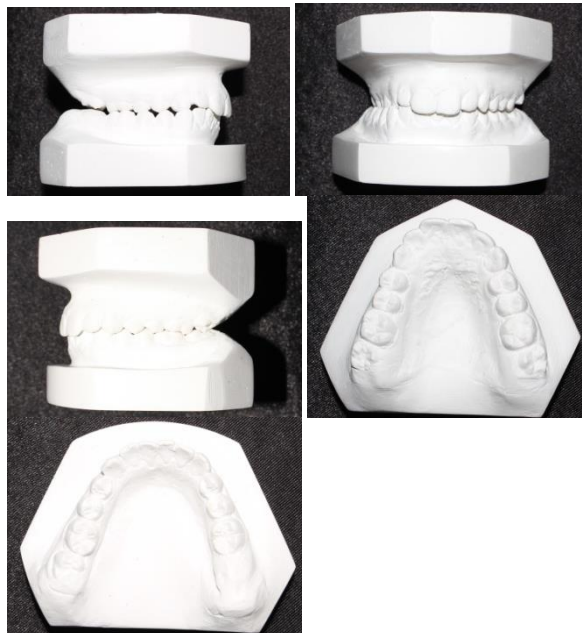


Figure 2b Pre treatment cast (a) Right buccal view; (b) Anterior view; (c) left buccal view; (d) maxillary occlusal view; (e) mandibular occlusal view.

OCCLUSAL FEATURES

- Incisor relationship: Class I
- Overjet (mm): 2 mm
- Overbite: 3 mm
- Centerlines: Upper dental midline matching with facial midline
- Lower dental midline shifted to right
- Incongruent dental midlines
- Left buccal segment relationship: Angle's class I molar relation
- Right buccal segment relationship: Angle's class II molar relation (End-on)
- Cross bites: unilateral posterior cross bite (right side)
- Displacements : 13,14,15 and 16 displaced palatally
- Marginal ridge discrepancy- 11,12 ;12,13;21,22, 22,23; 24,25
- Bolton's Discrepancy: Overall ratio = 93.9%,corresponds to overall mandibular tooth material excess of 2.7 mm) and. Anterior ratio = 80%, corresponds to mandibular anterior tooth material excess of 1.4mm

General Radiographic Examination

Pretreatment radiographs taken:Lateral cephalogram on: [28/4/18] (Figure 3)
Orthopantomogram (OPG) on[28/4/18] [(Figure 4)

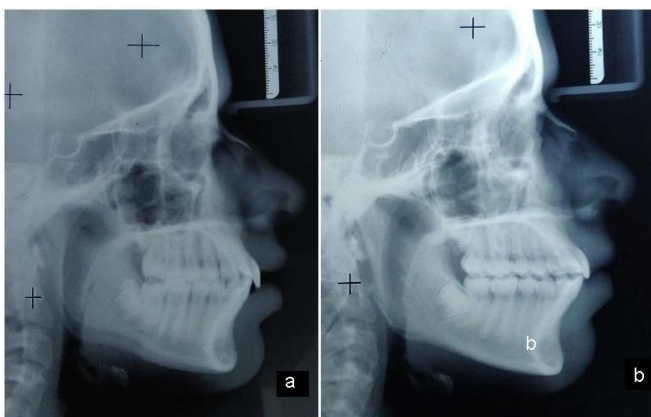


Figure 3 : Lateral cephalogram a ;Pre treatment b; Post treatment

RELEVANT RADIOGRAPHIC FINDINGS

The normal complement of permanent teeth was present with no abnormalities of the surrounding structures and regions; additionally, there were no abnormalities in the tooth form. The third molar tooth bud was present in all quadrants. The alveolar crestal bone level of the teeth present was within the normal limits of the CEJ. (Cemento-Enamel Junction) The condylar morphology was normal bilaterally.

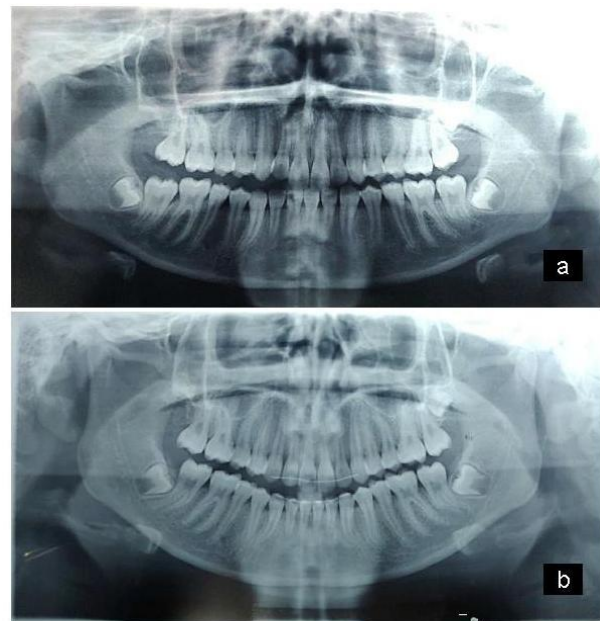


Figure 4 Orthopantomogram a; Pretreatment, b Post treatment

Pre treatment Cephalometric Findings and Their Interpretation

Various cephalometric findings are described in Tables 1-3.

Skeletal: The cephalometric analysis revealed a Class II skeletal base relationship based on ANB angle (6°) and Witt's appraisal (AO > BO by 1.5 mm) and skeletal class I based on Beta angle (32°). Both maxilla and mandible were forwardly placed in relation to cranial base (SNA 88° and SNB 82°). McNamara analysis revealed that both effective maxillary (Co - pt A = 82mm) and mandibular length (Co-Gn= 103 mm) were short from the norms of age 13 year (Co -pt A= 92.1 ± 2.7 mm, Co-Gn= 118.9 ± 5 mm) but the differential between maxillary and mandibular length were normal (21 mm) for the age group. Growth pattern was hypo-divergent in nature (Sn-GoGn= 28°)

Dental: The maxillary anteriors were retroclined and slightly forwardly positioned U1-NA (18° , 5mm) and the mandibular anteriors were proclined and forwardly placed L1-NB (35° , 7mm) .and IMPA (107°)..Her Intra oral examination revealed asymmetric V- shaped maxillary arch with minor crowding and U-shaped mandibular arch. She has all teeth erupted till 2nd permanent molar except in lower left segment where 2nd molar was absent. Her occlusion examination revealed that she has Angle's class I molar relation on left buccal segment and class II molar relation (End-on) on right buccal segment along with unilateral posterior cross bite of right side(Figure 4-9). Her incisor relationship was class I type with 2 mm of overjet and 2 mm of overbite. Her upper dental midline was matching with facial midline while lower dental midline was shifted to right side.

GENERAL RADIOGRAPHIC EXAMINATION

OPG and lateral cephalogram (Figure 10-11) showed all permanent teeth present except unerupted 18,28,37,38 and 48. There was no gross asymmetry noted. There was normal inter-proximal bone level.

Cephalometric analysis

Patient had forwardly placed maxilla and mandible (SNA=88° and SNB 82°) with respect to cranial base. She has Class II skeletal relation ANB= 6° with normal maxillo-mandibular differential and hypodivergent (FMA =24°) growth pattern (Figure 11). The maxillary incisors are slightly retroclined (U1 to NA 18° and 5mm) and Lower incisors were slightly proclined (L1 to NB 35° and 7 mm). Patient

VARIABLE	PRE-TREATMENT	POST treatment	NORMAL VALUES
Sagittal Skeletal Relationship			
SNA	88 ⁰	86 ⁰	82 ⁰ +2 ⁰
SNB	82 ⁰	81 ⁰	80 ⁰ + 2 ⁰
ANB	6 ⁰	5 ⁰	2-4 ⁰
Wits appraisal	AO ahead by 3mm	AO ahead by 1.5 mm	0 mm
Dental Base Relationship			
Upper incisor to NA (mm/deg)	5 mm, 18 ⁰	6 mm, 25 ⁰	22, ⁰ 4mm
Lower Incisor to NB (mm/deg)	7mm, 35 ⁰	6 mm, 33 ⁰	25 ⁰ ,4mm
Upper I to SN	105 ⁰	123	102 ⁰ ± 2 ⁰
Lower incisor to mandibular plane angle (IMPA)	101 ⁰		90 ⁰
Dental Relationship			
Inter- incisal angle	123 ⁰	118 ⁰	131 ⁰
Lower incisor to APo line	4 mm	6.mm	0-2 mm
Over bite	3.5mm	1.5mm	
Overjet	3.5mm	2 mm	
Vertical Skeletal Relationships			
Maxillary - mandibular planes angle	20 ⁰	21 ⁰	25 ⁰
SN Plane – Mand Plane	28 ⁰	29 ⁰	32 ⁰ ± 2 ⁰
Upper anterior face height	45 mm	45 mm	
Lower anterior face height	58 mm	59 mm	
Face height ratio	45:58	45:59	45: 55%
Jarabak Ratio	67.9%	66.6%	62-65%
Maxillary Length	82 mm	82mm	92.1±2.7
Mandibular Length – effective (McNamara)	103mm	104 mm	118.9±5
Soft Tissues			
Lower lip to Ricketts E Plane	1m m	1mm	-2 to 2mm
Nasolabial Angle	95 ⁰	93 ⁰	102 ⁰ ±8 ⁰
Other Parameters	Pre treatment	Post treatment	Normal values

Table 1. Cephalometric findings at various stages of orthodontic treatment: composite

Model Analysis

Bolton's Analysis showed overall ratio of 93.9% and anterior ratio of 80%. There was 2.7 mm overall mandibular excess 1.4 mm of anterior mandibular excess. Ashley Howe's Analysis reported PMBAW of 38.2% which exhibited that this is a borderline case. Pont's analysis showed 6 mm of expansion was possible in premolar region and 10 mm in molar region (MPV = 34mm, CPV = 40mm) and (MMV= 40mm, MMV =50 mm).

had normal nasolabial angle with normally positioned upper and lower lips (Table-1-2)

DIAGNOSIS

She has been diagnosed with Skeletal class II pattern (based on ANB=6°) with Angle's Class II div1 subdivision division (right side) malocclusion with retroclined upper incisors and proclined lower incisors and unilateral complete cross bite(right side) .She has normal nasolabial angle with potentially competent lips.

PROBLEM LIST

The following problem list were noticed

1. Unilateral Right side posterior cross bite
2. Retroclined maxillary incisors
3. Incongruent dental midlines
4. Incompetent lips
5. Improper masticatory function

AIMS AND OBJECTIVES OF TREATMENT

1. Maxillary Dentition:
Correction of unilateral posterior crossbite on right side
Correction of retroclined incisors
2. Mandibular Dentition
Correction of dental mid line
Correction of mild crowding in lower anterior region
3. Facial Esthetics
Improvement of smile esthetics
Correction of collapsed smile
Correction of mild lip incompetency
4. Function
Improvement of masticatory function

TREATMENT PLAN

Maxillary expansion with Fixed orthodontic (Non extraction) therapy

Quad helix was chosen for expansion appliance as patient was growing and maxillary sutures are not completely fused. Unilateral expansion of right side was planned by differential activation of quad helix

Appliances: Quad helix, Pre adjusted edge wise appliance
0.022 MBT Prescription

Additional dental treatment: Oral prophylaxis before start of treatment

Proposed retention strategy: Permanent retention along with upper removable retainer.

TREATMENT PROGRESS

At the start upper banding was done and impression with band was taken for fabrication of quad helix. Quad helix was activated unilaterally (right side) by 5 mm and cemented .

Bite turbos were placed lower first molars to create

dis-occlusion. After 5 months of active period,appliance was kept for retention. At this point upper arch bonding was done with 0.022 MBT appliance and .016 NiTi wire was ligated. After 7 of treatment, lower arch bonding was done and .016 NiTi was placed. After 9 months of treatment upper and lower .016x.022 NiTi wire werer placed. After 11 months of treatment upper and lower .016x.022 stainless steel wire was placed. At this stage quad helix was removed. After 13 months in treatment upper and lower .019x.025 stainless steel wire was placed.(Figure 12-17) After 16 months of treatment settling was started and finishing was completed by 20 months. Upper and lower fixed retainer was placed and case was debonded.

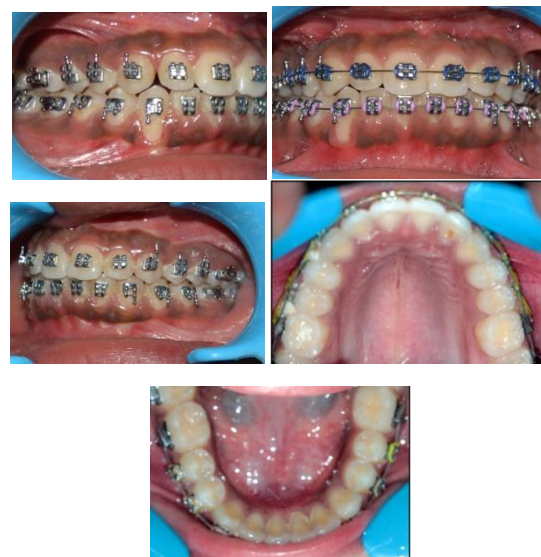

Figure 6: Mid treatment photographs .(a) (a) Right buccal view; (b) Anterior view; (c) left buccal view; (d) maxillary occlusal view; (e) mandibular occlusal view.

POST TREATMENT ASSESSMENT

Photographs OPG and lateral cephalogram were taken at end of treatment. . A pleasing facial profile and Angle's class I occlusion with 2 mm of over-jet and 1.5 mm of overbite was achieved. Cross bite of right side was completely corrected and no overhanging of posteriors was noticed. Due to correction of crossbite mandibular positioning was improved hence end on molar relationship of right side changed to angle class I and midlines became coinciding. Patient masticatory function was improved.

Post treatment cephalometric findings were interpreted as follows. (Table 3-6) There was an improvement in ANB angle along with correction of retroclined upper anteriors and mild improvement in proclination of lower anteriors. There was slight opening of mandibular plane angle. Chin position in sagittal plane improved due to residual mandibular growth.



Figure 7 Extra oral photographs (a) Frontal view at rest (b) Frontal view at smile and (c) Right profile view.

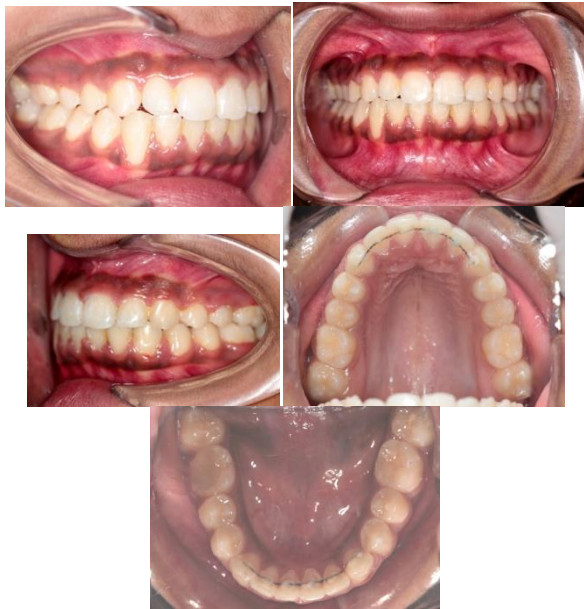

Figure 8a Intra oral photographs (a) (a) Right buccal view; (b) Anterior view; (c) left buccal view; (d) maxillary occlusal view; (e) mandibular occlusal view.

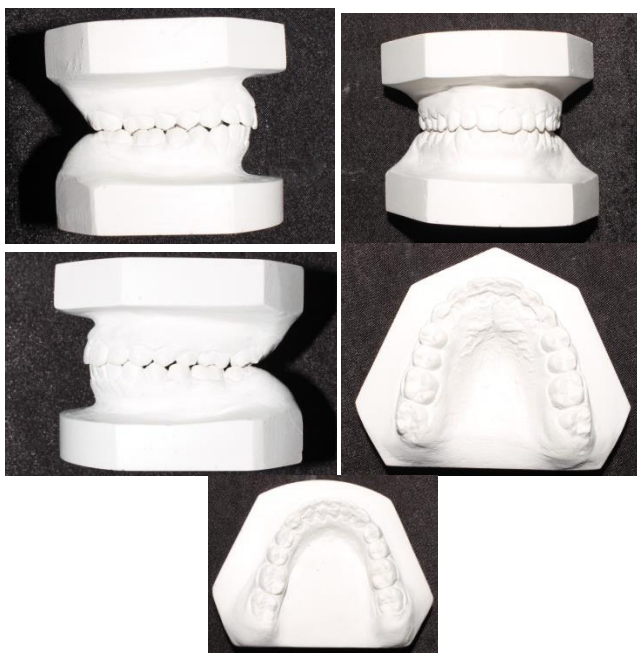

Figure: 8b Post treatment cast (a) (a) Right buccal view; (b) Anterior view;(c) left buccal view; (d) maxillary occlusal view; (e) mandibular occlusal view.

OCCLUSAL INDICES

Index of treatment need (IOTN) dental component score changed from grade 3 to grade 1 and aesthetic component score changed from grade 5 to grade 1. Peer assessment rating changed from score 5 to score 0. There was a 100% change after treatment.

COMPLICATIONS ENCOUNTERED DURING TREATMENT:

Cheek irritation with second molar tubes.

DISCUSSION

Unilateral cross bite can be treated with RME appliance and SME appliance both .In this particular case SME (quad helix) was preferred since patient was young and maxillary sutures were not completely fused. Its unique design permits unilateral activation which was suited for this case. Common problems encountered with expansion appliances are overhanging of palatal cusps of posterior teeth which results in opening of mandibular plane. This is more commonly observed With RME appliances. To control this adverse effects buccal root torque is added in .019x.025 ss wire in right posterior segment. Another important aspect of expansion appliances are its retention, enough time should be allowed so that achieved expansion can be retained otherwise relapse tendency is noted. In this case appliance was kept as passive for 4 months to stabilize the achieved expansion.

CRITICAL APPRAISAL

This case was treated according to the aims & objectives stated. The post treatment result show most of the objectives stated were achieved. Unilateral posterior cross bite was corrected and patient's masticatory function was improved due to correction of cross bite. There was a good improvement in retroclination of upper anteriors and buccal segment occlusion is achieved as class I bilaterally . However the lower incisor proclination could not be corrected much and mild gingival recession noticed on 43 could have been avoided.

CONCLUSION – In growing patient application of slow

Mc Namara analysis	Pretreatment	Post functional	Normal values for 13yr Female
$102^{\circ} \pm 8^{\circ}$	95°	93°	
Lower anterior facial height	58mm	59mm	65.6 ± 4.9
Pt A to NP	+9mm	+7mm	1mm
Cant of upper lip	17°	13°	$14^{\circ} \pm 8^{\circ}$
Pog to NP	8 mm behind NP	6mm behind NP	6-8mm behind NP
Upper incisor to pt A	6mm	8mm	4-6mm
Maxillary length	82mm	82mm	92.1 ± 2.7
Mandibular length	103mm	104mm	118.9 ± 5
Upper pharyngeal width	13mm	13mm	15-20mm
Lower pharyngeal width	7mm	7mm	11-14mm

Table 2. **Other Cephalometric findings at various stages of orthodontic treatment: composite**

maxillary expansion appliance like quad helix if used

judiciously can correct unilateral posterior cross bite without producing adverse effect like overhanging palatal cusps of posteriors. Slow maxillary expanders produce less tissue resistance around the circummaxillary structures and improve

REFERENCES

1. Kutin G, Hawes RR. Posterior cross-bites in the deciduous and mixed dentitions. *Am J Orthod.* 1969;56:491–504.

Other Parameters	Pre treatment	Post treatment	Normal values
FMA (Tweeds)	24°	24°	25°
Beta Angle	32°	34°	27° - 35° class I
Upper lip to S line (Steiners)	1mm	3mm	0mm
Lower lip to S line (Steiners)	2mm	3mm	2mm
Basic upper lip thickness (Holdaway)	13mm	14mm	
Upper lip thickness (Holdaway)	11mm	10mm	15mm
Lip strain (Holdaway)	2mm	3mm	0 mm
Scwartz analysis			
Anterior cranial base	62mm	62mm	71 ± 3
Length of body of mandible	65mm	65mm	
Length of ramus	55mm	56mm	
Length of maxilla	56mm	56mm	
Rakosi analysis			
Saddle angle	120°	122°	$123^{\circ} \pm 5^{\circ}$
Articular angle	145°	140°	$143^{\circ} \pm 6^{\circ}$
Gonial angle	124°	130°	$130^{\circ} \pm 7^{\circ}$
Bjork sum	389°	392°	396°
Posterior cranial base	35mm	35mm	32 ± 3
Inclination angle	85°	85°	85°

Table :3 **McNamara Analysis**

bone formation in the intermaxillary sutures^[9]

Declaration of conflicting interests

The author declared no potential conflicts of interest with respect to the research, authorship, and /or publication of this article.

FUNDING

The author received no financial support for the research, authorship and /or publication of this article.

4. Thilander B, Myrberg N. The prevalence of malocclusion in Swedish schoolchildren. *Scand J Dent Res.* 1973;81:12–20.
5. Heikenheimo K, Salmi K. Need for orthodontic intervention in five-year-old Finnish children. *Proc Finn Dent Soc.* 1987;83:165– 169.

6. Egermark-Eriksson I, Carlsson GE, Magnusson T,

INDEX	PARAMETER	VALUE
Index of Treatment Need		
Dental Health Component	Start	Grade-3
	Finish	Grade-1
Aesthetic Component	Start	Grade- 5
	Finish	Grade-1
Peer Assessment Rating (PAR)	Start	Score-5
	Finish	Score-0
	% Change	100 % change

Thilander B. A longitudinal study on malocclusion in relation to signs a symptoms of cranio-mandibular disorders in children and adolescents. *Eur J Orthod.* 1990;12:399–407.

7. Kurol J, Berglund L. Longitudinal study and cost-benefit analysis of the effect of early treatment of posterior crossbites in the primary dentition. *Eur J Orthod.* 1992;14:173–179.
8. Larsson E. The effect of dummy-sucking on the occlusion: a review. *Eur J Orthod.* 1986;8:127–130.
9. Bjerklin K. Follow-up control of patients with unilateral posterior cross-bite treated with expansion plates or the quad-helix appliance. *J Orofac Orthop* 2000;61:112-24.
10. M. S. Toroglu, E. Uzel, M. Kayalioglu, and I. Uzel, “Asymmetric maxillary expansion (AMEX) appliance for treatment of true unilateral posterior crossbite,” *American Journal of Orthodontics and Dentofacial Orthopaedics*, vol. 122, no. 2, pp. 164–173, 2002.
11. Henry RJ. Slow maxillary expansion: A review of quad-helix therapy during the transitional dentition. *ASDC J Dent Child* 1993;60:408-.