

Prognostic Factors of Palatally Displaced Canine: A Clinical Review

To cite: Vipul Kumar Sharma, Neeteesh Kumar Shukla, TP Chaturvedi - Prognostic Factors of Palatally Displaced Canine: A Clinical Review 2018; 3 (1): 20-27.

Received on:
14-01-2019

Accepted on:
28-02-2019

Source of Support: Nil

Conflict of Interest: None

¹Vipul Kumar Sharma, ²Neeteesh Kumar Shukla, ³TP Chaturvedi

¹Assistant professor, MDS, ²Student, MDS, ³Professor, MDS., PhD.

¹⁻³Faculty of Dental Sciences, BHU.

ABSTRACT

In this clinical review, prognostic factors related to the spontaneous eruption of palatally displaced canine are discussed based on available literature. There are number of literature has been published from time to time regarding different measures those helps in detection of prognostic variability for the spontaneous eruption of palatally displaced canine. Age at the time of diagnosis, position of canine related to sectors, angulation to different axes, distance of crown to cemento-enamel junction and occlusion plane, and position of root apex are the prime indicators of the prognosis. This review is a compilation of different studies published regarding spontaneous eruption of palatally displaced canine.

Key words: Palatally displaced canine, Sector classification, Angulation, Prognostic factors.

BACKGROUND

An impacted canine is the tooth which was unerupted even after complete root formation and/or the contralateral tooth was already erupted for atleast 6 months and for which there are clinical and radiographic evidences that chances of further eruption will be nil.^[1-2] Impaction of Maxillary canine is ranked second after third molar impaction. Prevalence may vary from 0.27% (among Japanese) to 3.58% (among Turkish population).^[3-4] The impacted canine is placed palatal to the dental arch in 85% of cases and labial/buccal in 15% of cases.^[2,5-7] This ratio may vary from 3:1 to 12:1.^[8-9] Among all palatal canine impactions, 92% have unilateral and only 8% have bilateral incidence.^[10] There is wide variation among the different racial population, palatal impactions are more common in Whites while Asians have more buccal impactions.^[11] Females are more affected than males.^[12]

ETIOLOGY

Several aetiological factors have been proposed for palatally impacted canines such as local obstruction in the eruption path of canine due to presence of hard tissue, any local pathology (cyst, odontoma etc), developmental anomaly of the incisors (peg lateral, short root etc) and genetic factors.^[13] In general, palatally impacted canines have enough space to erupt while buccally impacted canines are found in crowded dentition.^[5] Two major theories have been proposed and supported by many authors related to the etiology of palatally impacted canine e.g; guidance theory and genetic theory. One of the most important factor for the guidance to the mesially erupting canine in a favorable distobuccal and occlusal direction is the presence of normally developed lateral incisor which is erupted at right time with adequate root length.^[14-16] The genetic theory shows genetic factors as primary etiology

of palatally impacted canine and may be associated with missing, small or abnormal lateral incisor, enamel hypoplasia, aplasia of the second premolar, and infra occlusion of primary molars.^[17-18] MSX1 and PAX9 which have been correlated with the agenesis of teeth might be involved in palatally displaced canine. Mutation in the homeobox, HOX or sonic hedgehog gene related with the development of midface and teeth, hence may be as the causative factor in palatal impaction of canine.^[19] Number of controversies existed between guidance and genetic theories but according to a recent literature, genetic and guidance or environmental component both can lead to impaction but acting at different period of time.^[20] One more literature considered rate of migration in the occlusal and transverse direction as a critical factor for palatally displaced canine. If the rate is faster in occlusal direction, even in the presence of anomalous lateral incisor, canine would still manage to erupt normally and if the rate is faster in mesiopalatal direction, even in the presence of normal lateral incisor it will lead to impaction.^[21] Incisor inclination such as in Angle's Class II div 2 malocclusion may be risk factor for impaction^[22-23] and sometimes associated with peg-shaped lateral in 7.5% and palatal impaction in 33.5% cases.^[24]

DEVELOPMENT OF MAXILLARY CANINE (FIG. 1)

Maxillary Canine development commences at 4–5 months of age, high in the maxilla, lateral to the piriform fossa, begins to calcify at approximately 12 months of age between the roots of the first deciduous molar and completed at 5–6 years of age. It is then left behind as the deciduous molar erupts, allowing development of the first premolar between the roots of deciduous molar. At this stage, location of developing permanent canine is found just above both the developing first premolar and the first deciduous molar. Forward migration of

permanent incisor and canine crypts occurs at a greater rate than the forward movement of the deciduous teeth itself during eruption towards the occlusal plane.^[25] At the age of 7 years, the canine crown is medial to the root of deciduous cuspid with a vertical overlap of approximately 3 mm, then continues to move occlusally, guided via the distal aspect of the root of the upper lateral incisor traveling finally the longest path of eruption of 22 mm.^[26-27] Between 5 to 9 years of age, it is tendency of canines to move palatally but later in between 10 and 12 years of age there would be substantial movement in a buccal direction to achieve best possible position in the arch. So, the positional changes occurs during eruption of the canines in between 8 and 10 years of age need careful observation for detection of potential impaction.^[28]

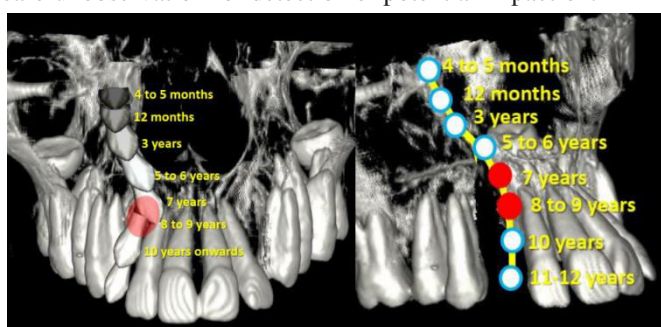


Fig. 1; coronal and sagittal views shows development of permanent maxillary canine from its tooth germ formation to emergence in oral cavity. Red shades indicates changing in direction from mesiopalatal to distobuccal to attain proper location in oral cavity. If this turn in direction would not exist it may cause palatal impaction of canine.

Accurate location of impacted canine must be known for proper interceptive treatment outcomes. Clinical and radiological examinations are most common form of investigations involved for assessment of unerupted canine. The absence of labial bulge in age 10 to 12 years leads to the high possibility of palatally displaced canine.^[29] In this alarming situation, we should go for conventional/3D radiographic assessment of the unerupted canine. Prognosis regarding spontaneous eruption of palatally displaced canine depends upon several factors like age of the patient, early diagnosis of impaction, position and angulation of the canine crown and root and presence of obstruction etc.

Position of crown and overlapping to adjacent incisors

One of the most common and relevant classification to determine the favorable prognosis of palatally displaced canine is Sector classification in which sectors are divided in and around lateral incisor in panoramic radiographs. No horizontal overlap of adjacent incisor indicates good prognosis and as the overlapping increases to the root of the adjacent incisor prognosis will be poorer.^[30] Ericson and

Kurol^[31] divided the area in and around maxillary lateral incisor into five sectors and located the palatally displaced canine tip in different sectors. They concluded that in total number of palatally displaced canine, 52% located in sector 1 and sector 2, 91% get normalized, and 48% of the total located in sector 3 and 4, 64% get normalized, means most of the teeth which did not normalize was located in sector 3 and 4.^[31] Simply means more mesial location of crown tip of the canine post the poor prognosis. Later, sector classification was modified by Lindauer et al^[1] into 4 sectors (Fig.2) and concluded that this method identifies upto 78% of the canines those will become impacted, all of which having cusp tip located in sector II, III, and IV. Almost same results were obtained in another study in which 82% impactions were present in sectors II, III, and IV and observation was made that as sector location move mesially chances of impaction increase factor of almost 9 per sector.^[32] Another study reported that at the age of 9 years and above, the cusp tip of impacted canine was found to lie between the distal root surface and the central long axis of adjacent lateral incisor while cusp tip of control canine located superior to deciduous canine.^[33]

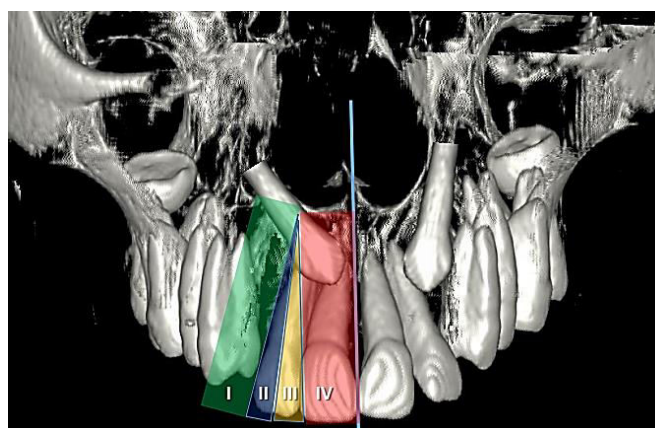


Fig. 2; Lindauer modified sector classification (I-IV) for mesiodistal crown position of the permanent maxillary canine. I- correspond to distal to the distal contour of lateral incisor; II- between sector I and the long axis of lateral incisor; III- between sector II and IV; IV- area mesial to the mesial contour of lateral incisor to the midline.

Alpha angle (α) is used to represent the angle between the long axis of canine and inter-incisor midline (Fig. 3) and if this angle is greater than 25° then prognosis will be poor.^[29] Another study reported poor prognosis for angulation more than 31° to midline.^[28] According to various findings, if the angulation is more than 20° , it reduces the chances of spontaneous eruption.^[20,28-29,34] One study stated that angulation to midline only contributed in sector II to increase chances of impaction.^[32] Angulation of long axis of canine to the bicondylar line (Fig. 4) is decreased for impaction with a mean of 63.20° and increased for nonimpaction with a mean of 75.12° .^[32] In the PA view, prognosis can be evaluated through the evaluation of angle formed between the transorbital line and long axis of

permanent canine (Fig. 4), poor prognosis and treatment difficulty increases as the said angle decreases.^[35] In lateral cephalogram prognostic evaluation of impacted canine carried out by evaluating the labial tipping of long axis of canine and intersecting it with the perpendicular to Frankfurt plane (Fig. 5), the ideal vertical eruptive path of unerupted canine was 10° of labial tipping, small increase in angulation or forward tipping lead to worsening of prognosis when combined with midline displacement.^[36] A CBCT study concluded that impacted canine angle to midline and adjacent lateral incisor (Fig. 6) was 20.7 and 36.3 respectively that was higher than non-impaction cases.^[37]

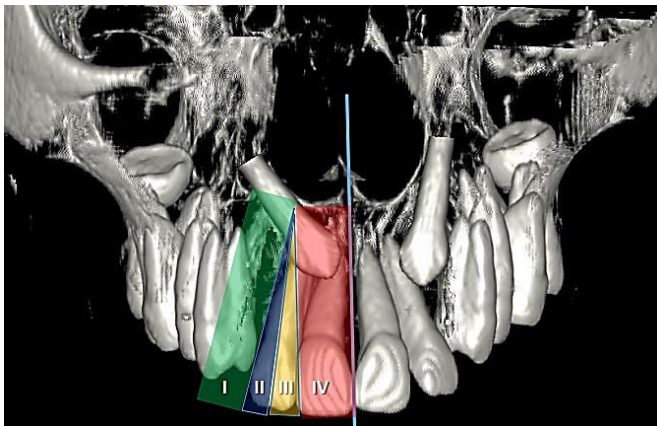


Fig. 3; Alpha (α) angle is the angle between midline and long axis of canine.

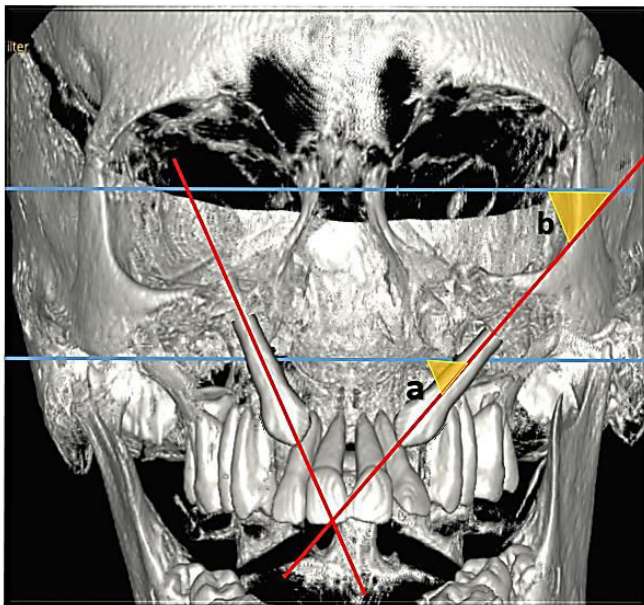


Fig. 4; 'a' denotes angle between long axis of canine and bicondylar line while 'b' denotes angle between long axis of canine and transorbital line.

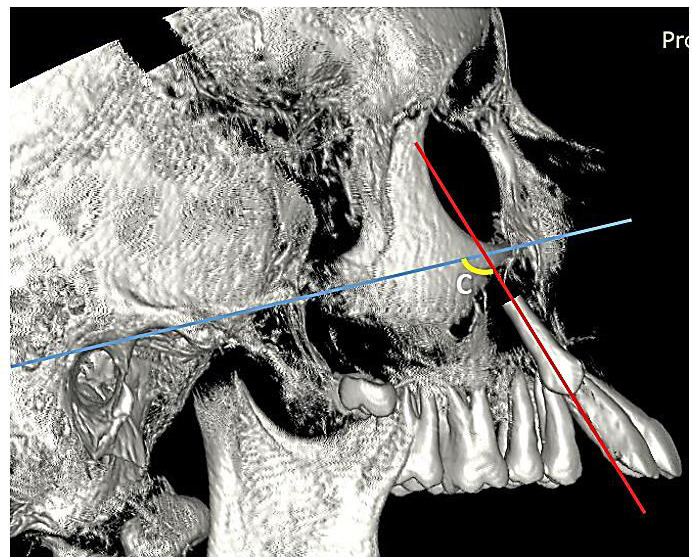


Fig. 5; Angle between long axis of canine and FH plane in lateral cephalogram (c).

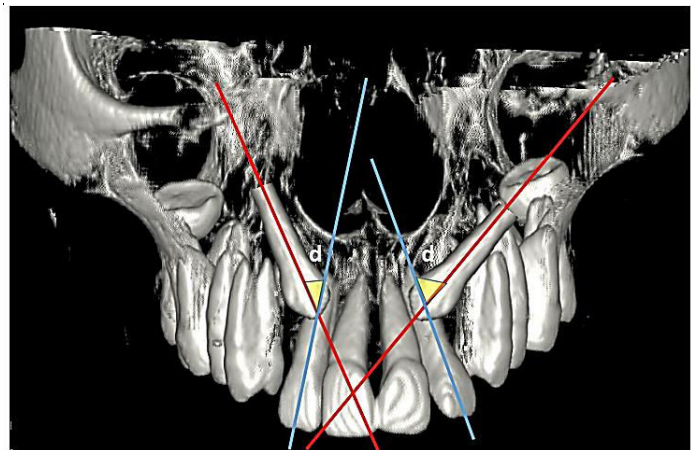


Fig. 6; Angle between long axis of canine and long axis of lateral incisor (d).

VERTICAL POSITION OF CUSP TIP OF IMPACTED CANINE(FIG. 7, 8)

More the apical position of crown, poorer is the prognosis. Canine cusp tip at the level of the cervical portion of the adjacent incisor root shows good prognosis. A fair prognosis would be predicted if the canine cusp tip lie at a level of half root length which should be towards cervical third of the root of the adjacent incisor, and when a canine cusp tip present or lay against the apical third of the adjacent incisor root shows poor prognosis for alignment (Fig. 7).^[30] Some time it is possible that even higher position of canine may have good prognosis in case of minimal eruption path deflection.^[31] The results demonstrated that the impacted canines have minimum potential to move (mean distance 3.3mm) in the vertical direction towards the occlusal plane than the unaffected canine (mean distance 18.2mm)(Fig. 8).^[20] A study concluded the

distance of 12 mm as a borderline between successful and unsuccessful outcome.^[34]

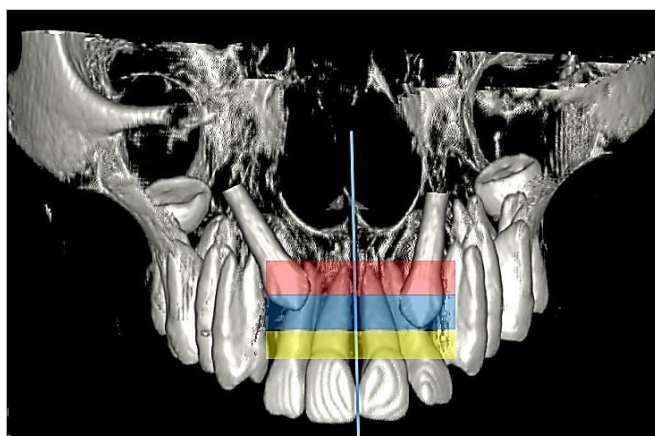


Fig. 7; yellow shade indicates cusp tip location at cervical third, blue indicates at middle third while red indicates at apical third.

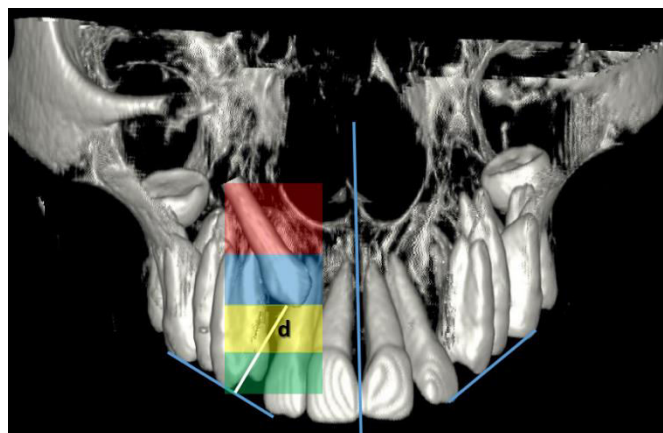


Fig. 8; Location of cusp tip related to occlusal plane, as the distance 'd' increases chances of spontaneous eruption decreases.

THE POSITION OF CANINE ROOT APEX IN HORIZONTAL PLANE (FIG. 9)

If the root apex of canine is located above the normal canine position, the prognosis would be good, if the location of the apex found above the first premolar region; the prognosis would be average and above the second premolar chances of impaction increased.^[30]

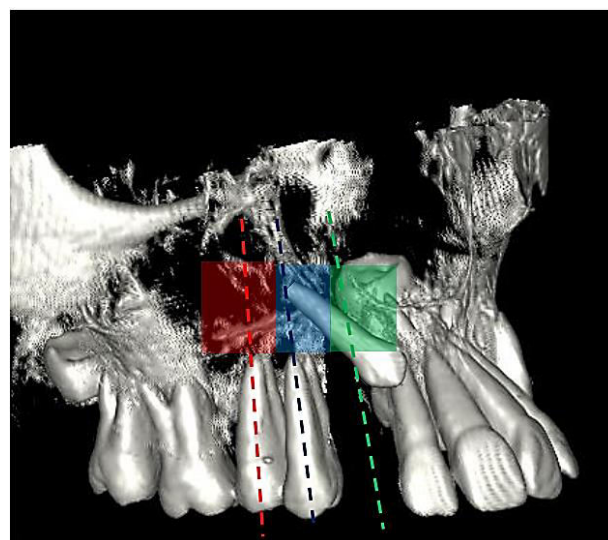


Fig. 9; position of canine root apex indicates by dotted lines and shades of green, blue, and red. Green indicates position at the long axis of future erupted canine, blue indicates above the long axis of first premolar root, while red indicates above the long axis of second premolar root.

SIZE OF DENTAL FOLLICLE (FIG. 10)

According to one study that that maximum width exceeded 3mm in 22% cases while other 78% having normal follicle width and ranges between 1 to 5mm and concluded that there was no correlation found between the chances of impactions and size of dental follicle.^[31] According to CBCT findings, there was no significant correlation found between follicular width and subject's gender, side of impaction, different localizations (palatal/central/buccal) and root resorption status of lateral incisors.^[38] Contrary to the above studies a finding concluded that follicle size was wider on average and asymmetric in shape in ectopically erupted canine.^[39]

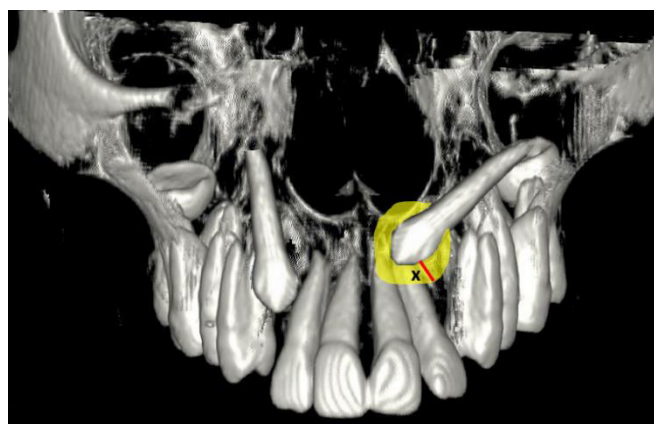


Fig. 10; as the size (x) of dental follicle increases and when its shape is more asymmetrical, it may have more chances of impaction.

CORTICAL BONE DENSITY

Multi Detector Computed Tomography (MDCT) study shows that mean bone density of the cortical bone is greater in the maxillary impacted canine side than in the control side.^[40] Higher resistance to eruption pathway may lead to impaction.

AGE OF THE PATIENT

The average age when a maxillary canine should erupt is 13 years in boys and 12 years 3 months in girls.^[41] The age group of 8 to 10 years is seems to be the best time to begin observation of the intraosseous positional changes of the canine.^[26,42-43] Removal of primary canine should be done before the age of 11 years to increase the chances of spontaneous eruption.^[27] Permanent maxillary canines shows good prognosis for the spontaneous eruption during prepubertal and pubertal growth phases. These results were determined using the statural height peak.^[44-45] There is great inter-individual variability with regard to the age of emergence of canine. The eruption of permanent maxillary canine usually occurs before the end of pubertal growth spurt (CS1 to CS4). Absence of permanent maxillary canine during postpubertal stage (CS5 and CS6) indicates delayed eruption or canine impaction.^[46] Demirjian et al^[47] described 8 stages (A to H) of maturation of second molar in which stages E to H are having particular interest regarding eruption of maxillary canine.

DISCUSSION

Maxillary canine has the longest and most tortuous course of eruption from its development to intraoral functioning position.^[48-51] The positional changes in early age need careful observation for detection of potential impaction. Failure to make buccal movement during the last phase of the eruption, has been implicated in palatal displacement of canine.^[28] One study quantified the movement of normally erupting maxillary canine using lateral and PA cephalogram between 5 and 15 years of age and concluded that the total horizontal movement of all canines averaged 11.48 mm in a posterior direction while vertical movement averaged 18.56 mm and the overall movement of the canine in the buccal direction was 2.67 mm so the mean total distance traveled was 22 mm between 5 and 15 years.^[52] There is significant differences between normal and ectopic canines between the ages of 8 and 12 years, with the normal canines moving in a more posterior direction while vertically, both normal and ectopic canines show significant changes throughout the age range and Laterally, normally erupting canines show

significant movement in a buccal direction after 10 years, whereas the ectopic canines move significantly in a palatal direction in each of the years from 5 to 15.^[53] A delayed erupting canine having both possibilities that it may erupt spontaneously after removing its etiology or other factors or it may remain impacted. Along with the genetic etiology, the eruption of the palatally displaced canine can be affected by local factors, and removal of these local/mechanical factors have become the targets of “interceptive treatment” for physiological eruption of canine. The most popular interceptive measure is the extraction of the deciduous predecessor.^[26-27,31,54-57] The removal of the deciduous canine for reducing the prevalence of palatal displacement of canine was first reported by Buchner in 1936.^[58] The reliable prediction of successful interceptive treatment could help decrease the patient’s need for surgical exposure and orthodontic traction of impacted canine. The mesiodistal position or sector location of the cusp tip and the angulations of the unerupted canine, as well as premolar inclination, has an established role in prediction of the future canine impaction or the chance of successful spontaneous eruption after interceptive treatment.^[1,32,59-62] An important, effective and most common approach to reduce the risk of impaction is based on intercepting and eliminating any local/mechanical factor that may interfere with eruption.^[63] In a study, 91% of impacted canines displaced no more than half of the lateral incisor root and that 64% located more mesially erupted after removal of deciduous canine only if there was enough space in the dental arch up to 11 years of age, overall success rate was 78%.^[31] While another study reported 62% success rate with an additional 19% cases having improved canine position.^[6] Contrary to above studies, as reported by the author, there was no statistically significant difference found for the group of successful outcomes that underwent the extraction of the deciduous canines and for those in the untreated control group.^[64] Many studies reported that during normal eruption of canine number of changes occurs in its inclination, with a physiological uprighting of its long axis at about 9 years of age.^[65-66] There is correlation between the preruptive positional changes of the maxillary canine and the first premolar between 8 and 10 years of age, greater uprighting of the long axis of the canine observed overtime if greater the uprighting of the long axis of premolar.^[67] There is no significant difference found between root development stages of impacted and unaffected canine.^[20] Patient with palatally impacted canines has significantly delayed dental development.^[68] In a CBCT study the canine angulation to the long axis of lateral incisor, the canine cusp tip to the occlusal plane and canine crown position considered to be the strongest predictors of spontaneous eruption.^[37] Another CBCT study reported the three best discriminating parameters between impacted and non-impacted canines were angle between long axis of canine and premolars,

distance of canine cusp tip to midline and maxillary plane.^[69]

CONCLUSION

Following prognostic variables can be drawn according to the number of different literature studied for the spontaneous eruption of maxillary canine-

1. Early missed diagnosis would post poor prognosis.
2. As the age advances prognosis would be poor. Patient above 13 years of age, patient after end of pubertal growth spurt or CS5/CS6 stage, and unerupted canine even after mandibular second molar maturation would show poor prognosis.
3. Crowded arch or disturbed arch perimeter in case of palatally displaced canine diagnosed lead to chances of impaction until or unless sufficient space is created.
4. In panoramic radiographs as the canine cusp tip lie more towards the midline/more towards sector IV or overlapping more on lateral incisor root would indicate less chances of canine eruption.
5. Increased inclination with midline/lateral incisor/first premolar or decreased inclination with bicondylar line/transorbital line or even small increased forward tipping with respect to FH plane in lateral cephalogram would forecast a poor prognosis.
6. Chances for spontaneous eruption decreased as the vertical distance from the occlusal plane increased and even more if it is added with increased path deflection.
7. Presence of any obstruction like a cyst, odontomas, root of adjacent teeth or retained deciduous canine, periapical pathologies would lead to increase the chances of impaction.
8. Increased size and asymmetric form of dental follicle may be associated with poor prognosis.

Dense cortical bone in the path of erupting canine may act as an obstruction and lowers the prognostic values.

REFERENCES

1. Lindauer S, Rubenstein L, Hang W, Andersen W, Isaacson R. Canine impaction identified early with panoramic radiographs. *J Am Dent Assoc.* 1992;123:91-2,95-7.
2. Thilander B, Jakobsson SO. Local factors in impaction of maxillary canine. *Acta Odontologica Scandinavica.* 1968;26:145-68.
3. Takahama Y, Aiyama Y. Maxillary canine impaction as a possible microform of cleft lip and palate. *Eur J Orthod.* 1982;4:275-7.
4. Aydin U, Yilmaz HH, Yildirim D. Incidence of canine impaction and transmigration in a patient population. *Dentomaxillofac Radiol.* 2004;33:164-9.
5. Jacoby H. The etiology of maxillary canine impactions. *Am J Orthod.* 1983;84:125-32.
6. Ericson S, Kurol J. Radiographic examination of ectopically erupting maxillary canines. *Am J Orthod Dentofacial Orthop.* 1987;91:483-92.
7. Hitchen AD. The impacted maxillary canine. *Br Dent J.* 1956;100:1-14.
8. Fournier A, Turcotte JY, Bernard C. Orthodontic considerations in the treatment of maxillary impacted canines. *Am J Orthod.* 1982;81:236-9.
9. Jacoby H. The "ballista spring" system for impacted teeth. *Am J Orthod Dentofacial Orthop.* 1979;75:143-51.
10. Dachi SF, Howell FV. A survey of 3,874 routine full-mouth radiographs. oII. A study of impacted teeth. *Oral Surg Oral Med Oral Pathol.* 1961;14:1165-69.
11. Oliver RG, Mannion JE, Robinson JM. Morphology of the maxillary lateral incisor in cases of unilateral impaction of the maxillary canine. *Br J Orthod.* 1989;16:9-16.
12. Oberoi S, Knueppel S. Three-dimensional assessment of impacted canines and root resorption using cone beam computed tomography. *Oral and maxillofacial radiology.* 2012;113:260-7.
13. Becker A, Chaushu S. Etiology of maxillary canine impaction: A review. *Am J Orthod Dentofacial Orthop.* 2015;148:557-67.
14. Becker A. In defense of the guidance theory of palatal canine displacement. *Angle Orthod.* 1995;65:95-8.
15. Miller BH. The influence of congenitally missing teeth on the eruption of the upper canine. *Dent Pract Dent Rec.* 1963;13:497-504.
16. Ziberman Y, Cohen B, Becker A. familial trends in palatal canines, anomalous lateral incisors, and related phenomena. *Eur J Orthod.* 1990;12:135-39.
17. Peck S, Peck L, Kataja M. The palatally displaced canine

- as a dental anomaly of genetic origin. *Angle Orthod.* 1994;64:249-56.
18. Baccetti T. A controlled study of associated dental anomalies. *Angle Orthod.* 1998;68:267-74.
 19. Duverger O, Morasso MI. Role of homeobox gene in the patterning, specification and differentiation of ectodermal appendages in mammals. *J Cell Physiol.* 2008;216:337-46.
 20. Sajani AK, King NM. The sequential hypothesis of impaction of maxillary canine- A hypothesis based on clinical and radiographic findings. *J cranmaxillofac surg.* 2012;40:375-85.
 21. Yan B, Sun Z, Fields H, Wang L, Luo L. Etiological factors for buccal and palatal maxillary canine impaction: a perspective based on cone beam computed tomographic analyses. *Am J Orthod Dentofacial Orthop.* 2013;143:527-34.
 22. Cernochova P, Izakovicova-Holla L. Dentoskeletal characteristics in patients with palatally and buccally displaced maxillary permanent canines. *Eur J Orthod.* 2012;34:754-61.
 23. Ludicke G, Harzer W, Tausche E. Incisor inclination-risk factor for palatally-impacted canines. *J Orofac Orthop.* 2008;69:357-64.
 24. Basdra EK, Kiokpasoglou M, Stellzig A. The Class II Division 2 craniofacial type is associated with numerous congenital tooth anomalies. *Eur J Orthod.* 2000;22:529-35.
 25. Noyes FB. *Dental histology and embryology.* 1930;4th ed. Kimpton, London, p. 370.
 26. Williams BH. Diagnosis and prevention of maxillary cuspid impaction. *Angle Orthod.* 1981;51:38-40.
 27. Becker A. The median diastema. *Dent Clin N Am.* 1978;22:685.
 28. Power SM, Short MB. An investigation into the response of palatally displaced canine to the removal of deciduous canine and assessment of factors contributing to favorable eruption. *Br J Orthod.* 1993;20:217-23.
 29. Ericson S, Kurol J. Longitudinal study and analysis of clinical supervision of maxillary canine eruption. *Community Dent Oral Epidemiol.* 1986;14:112-16.
 30. McSherry P. The assessment of and treatment option for the buried maxillary canine. *Dent update.* 1996;23:7-10.
 31. Ericson S, Kurol J. Early treatment of palatally erupting maxillary canines by extraction of the primary canines. *Eur J Orthod.* 1988;10:283-95.
 32. Warford JH, Grandhi RK, Tira DE. Prediction of maxillary canine impaction using sectors and angular measurement. *Am J Orthod Dentofacial Orthop.* 2003;124:651-5.
 33. Sajani AK, King NM. Early prediction of maxillary canine impaction from panoramic radiograph. *J Orthod Dentofacial Orthop.* 2012;142:45-51.
 34. Smailienė D, Šidlauskas A, Lopatienė K, Guzevičienė V, Juodžbalys G. factors affecting self-eruption of displaced permanent maxillary canine. *Medicina (kaunas).* 2011;47:163-9.
 35. Manverna R, Gracco A. Different diagnostic tools for the localisation of impacted canines: clinical considerations. *Progress in Orthodontics.* 2007;8:28-44.
 36. Orton HS, Garvey MT, Pearson MH. Extrusion of the ectopic maxillary canine using a lower removable appliance. *Am J Orthod Dentofacial Orthop.* 1995;107:349-59.
 37. Alqerban A, Jacobs R, Fieuws S, Willems G. Radiographic predictors for maxillary canine impaction. *Am J Orthod Dentofacial Orthop.* 2015;147:345-54.
 38. Dağsuyu İM, Okşayan R, Kahraman F, Aydın M, Bayrakdar İS, Uğurlu M. the relationship between dental follicle width and maxillary impacted canines. *Biomed Research International.* <https://doi.org/10.1155/2017/2938691>.
 39. Ericson S, Bjerklind K. The dental follicle in normally and ectopically erupting maxillary canines: a computed tomography study. *Angle Orthod.* 2001;71:333-42.
 40. Ghaib NH, Al-Ansari NB. The multidetector computed tomographical analysis of bone density in impacted maxillary canines. *J Bagh Coll Dentistry.* 2013;25:165-67.
 41. Bishara SE. Impacted maxillary canines: a review. *Am J Orthod Dentofacial Orthop.* 1992;101:159-71.
 42. Ortop. 1992;101:159-71.
 43. Kufteci MM, Shapira Y. The impacted maxillary canine. I:

- review of concepts. *ASDC J Dent Child*. 1995;62:317-24.
44. Jacobs SG. Localization of the unerupted maxillary canine: how to and when to. *Am J Orthod Dentofacial Orthop*. 1999;115:314-22.
 45. Bjork A, Helm S. Prediction of the age of maximum puberal growth in body height. *Angle Orthod*. 1967;37:134-43.
 46. Haegg U, Taranger J. Maturation indicators and the pubertal growth spurt. *Am J Orthod*. 1982;82:299-309.
 47. Baccetti T, Franchi L, De Lisa S, Giuntini V. Eruption of the maxillary canines in relation to the skeletal maturity. *Am J Orthod Dentofacial Orthop*. 2008;133:748-51.
 48. Demirjian A, Goldstein H, Tanner JM. A new system of dental age assessment. *Hum Biol*. 1973;45:211-27.
 49. Broadbent BH. Ontogenic development of occlusion. *Angle Orthod*. 1941;11:223-41.
 50. Dewel BF. The upper cuspid: its development and impaction. *Angle orthod*. 1949;19:79-90.
 51. Kay LW. The impacted maxillary canine part 1. *Dent Update*. 1977;4:335-9.
 52. Moss JP. The unerupted canine. *Dental Practitioner*. 1972;22:241-8.
 53. Coulter J, Richardson A. Normal eruption of the maxillary canine quantified in three dimensions. *Europ J Orthod*. 1997;19:171-183.
 54. McSherry P, Richardson A. Ectopic eruption of the maxillary canine quantified in three dimensions on cephalometric radiographs between the ages of 5 and 15 years. *Europ J Orthod*. 1999;21:41-48.
 55. Fearn J, Lee RT. Favourable spontaneous eruption of severely displaced maxillary canines with associated follicular disturbance. *Br J Orthod*. 1988;15:93-8.
 56. Brown N, Sandy J. Spontaneous improvement in position of canines from apparently hopeless positions. *Int J Paediatr Dent*. 2001;11:64-8.
 57. Silvola A, Arvonen P, Julku J, Lahdesmaki R, Kantomaa T, Pirttiniemi P. Early headgear effects on the eruption pattern of the maxillary canines. *Angle Orthod* 2009;79:540-5.
 58. Bruks A, Lennartsson B. The palatally displaced maxillary canine a retrospective comparison between an interceptive and a corrective treatment group. *Swed Dent J*. 1999;23:149-61.
 59. Buchner HJ. Root resorption caused by ectopic eruption of maxillary cuspid. *International J Orthod*. 1936;22:1236-7.
 60. Shapire Y, Kuftinec MM. Early diagnosis and interception of potential maxillary canine impaction. *J Am Dent Assoc*. 1998;129:1450-4.
 61. Olive R. Factors influencing the non-surgical eruption of palatally impacted canines. *Aust Orthod J*. 2005;21:95-101.
 62. Bonetti AG, Parenti SI, Zanarini M, Marini I. Double vs single primary teeth extraction approach as prevention of permanent maxillary canines ectopic eruption. *Pediatr Dent*. 2010; 32:407-12.
 63. Parenti SI, Gatto MR, Gracco A, Bonetti AG. Reliability of different methods for measuring the inclination of the maxillary canines on panoramic radiographs. *Orthod Craniofac Res*. 2013;16:177-84.
 64. Baccetti T, Leonardi M, Armi P. A randomized clinical study of two interceptive approaches to palatally displaced canines. *Eur J Orthod*. 2008;30:381-5.
 65. Leonardi M, Armi P, Franchi L, Baccetti T. Two interceptive approaches to palatally displaced canines: a prospective longitudinal study. *Angle Orthod* 2004;74:581-6.
 66. Fernandez E, Bravo LA, Canteras M. Eruption of the permanent upper canine: a radiologic study. *Am J Orthod Dentofacial Orthop*. 1998;113:414-20.
 67. Bonetti AG, Zanarini M, Danesi M, Parenti SI, Gatto MR. Percentiles relative to maxillary permanent canine inclination by age: a radiologic study. *Am J Orthod Dentofacial Orthop*. 2009;136:486.e1-6.
 68. Parenti SI, Marini I, Ippolito DR, Bonetti AG. Preeruptive changes in maxillary canine and first premolar inclinations: a retrospective study on panoramic radiographs. *Am J Orthod Dentofacial Orthop*. 2014;146:460-6.
 69. Newcomb MR. Recognition and interception of aberrant canine eruption. *Angle Orthod*. 1959;29:161-8.
 70. Alqerban A, Storms AS, Voet M, Fieuws S, Willems G. Early prediction of maxillary canine impaction. *Dentomaxillofac Radiol*. 2016;45(3).