

## Clinical Pearl

**To cite:** Kumar Mukesh, Goyal Manish, Kushwah Ashish - Quick assessment of dento-skeletal asymmetry by a Customized Transparent Graphed Jig (CTGJ) - A Diagnostic Tool 2019;3(1): 45-47.

**Received on:** 20-01-2019

**Accepted on:** 23-02-2019

**Source of Support:** Nil

**Conflict of Interest:** None

# Quick assessment of dento-skeletal asymmetry by a Customized Transparent Graphed Jig (CTGJ) - A Diagnostic Tool

**<sup>1</sup>Kumar Mukesh, <sup>2</sup>Goyal Manish, <sup>3</sup>Kushwah Ashish**

<sup>1</sup>MDS in Orthodontics, Professor, <sup>2</sup>MDS, PhD - Principal and Head of Department, <sup>3</sup>MORTH RCSEd (UK), MDS in Orthodontics - Post graduate student

<sup>1-3</sup>Department of Orthodontics and Dentofacial Orthopaedics Teerthanker Mahaveer Dental College, Moradabad, Uttar Pradesh.

## ABSTRACT

Various methods are available today to evaluate dento-skeletal asymmetry but none seems to be efficient to the tune of Customized Transparent Graphed Jig (CTGJ). Furthermore in Class II subdivision cases where molar is in Class II relation on one side and Class I on the other. It becomes real testing point for the clinician to diagnose the faulty molar. Supplementary diagnostic aids in the form of PA cephalogram also fail to categorically define the malocclusion site a part from an extra radiographic exposure to the patient. The need for precise and accurate measurement of the dento-skeletal asymmetry without any hazard of extra radiation led us to the fabrication of a Customized Transparent Graphed Jig (CTGJ) whose results could be calibrated even to the tune of 0.5mm. This article shows a fabrication and method of application of a Customized Transparent Graphed Jig (CTGJ) to measure dento-skeletal asymmetry of maxillary and mandibular arch.

**Keywords:** Class II subdivision, dentoalveolar asymmetry, Customized Transparent Graphed Jig (CTGJ), skeleton-dental asymmetry.

## INTRODUCTION

Class II subdivision malocclusions characterized by dentoalveolar asymmetry which occurred due to skeletal component, disk displacement, or pathological condition of the TMJ with dentoalveolar asymmetries. Some Class II subdivision problems are created by distal positioning of the mandibular first molar or mesial positioning of the maxillary first molar on the Class II side.<sup>1-4</sup>

Asymmetry of arch form may also be present even if the face looks symmetric. This condition will be present especially in subdivision cases. In other words finding symmetry related to basal jaw structures, unilateral Class II malocclusion must be attributed to asymmetrical position of one of the dental arches upon its skeletal base. Accurately trimmed dental casts are a necessity if the asymmetry is to be most easily recognized.<sup>5-6</sup>

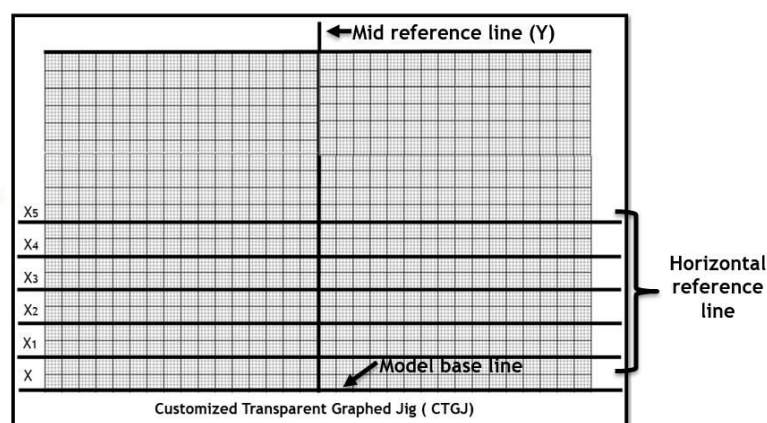
This article shows a use of a Customized Transparent Graphed Jig (CTGJ) to measure skeleton-dental asymmetry of maxillary and mandibular arch which is helpful in analysis of relative symmetry of molar position on subdivision side in relation to molar of contralateral side, which helps the clinician to diagnose that subdivision created by maxillary molar or by mandibular molar.

## DESIGN AND FABRICATION

A 2 mm thick transparent polyvinyl sheet used for fabrication of "Customized Transparent Graphed Jig (CTGJ)".

Thickness of sheet should be 2 mm or more to provide sufficient rigidity during assessment of relative arch symmetry. Dimension of sheet was 12 mm X 18 mm (height and width). A 10 mm X 16 mm sized graph printed on transparent sheet. A thick black vertical line was drawn from the center of the graph that is "Mid reference line" or "Y-Line" and six horizontal thick black lines were drawn. Upper 5 horizontal lines represent as "Horizontal reference lines" ( $X_1$  to  $X_5$ ) and last sixth horizontal line can be referred as "Model base line" or "X-Line" (Figure 1).


The mid reference line or "Y-Line" is used for coinciding the upper arch with mid palatal raphe, the horizontal reference lines are used for the assessment of first molar and canine position while the model base line is used for coinciding the lower border of model or cast.



## METHOD OF APPLICATION

Before assessment of the relative symmetry of the maxillary and mandibular arch, place the maxillary or mandibular cast on a flat surface then place the CTGJ on the cast and adjust it so X-line should be parallel with lower border of cast while mid reference line coincides with the mid palatal raphae/lingual frenum (maxillary/mandibular arch).

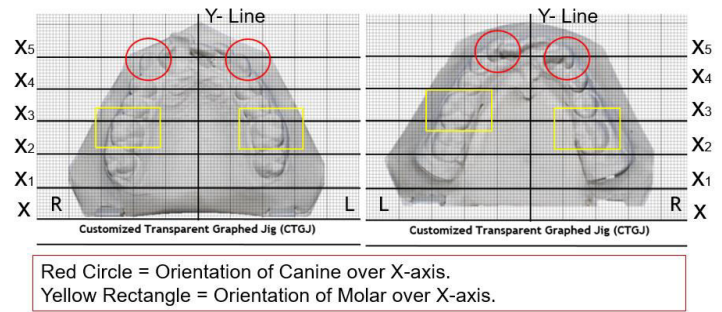
An ideal maxillary and mandibular study model used for assessment of relative symmetry is shown in Figure 2. The “X<sub>5</sub> – line” passes through canine cusp tip and “X<sub>3</sub> – line” passes through mesio-buccal cusp tip of first molar.



**Figure 2.** Application of Customized Transparent Graphed Jig on Ideal maxillary and mandibular study model

## APPLICATION ON PATIENT’S MODEL

Customized transparent graphed jig assessment showed that maxillary arch and mandibular arch were relatively asymmetrical. Left maxillary cusp tip of canine is 2 mm behind to the “X<sub>5</sub> – line” in respect to right maxillary canine in CTGJ (red circle in figure 3). Right and left maxillary first molar are coinciding to each other to the “X<sub>3</sub> – line” in CTGJ (yellow rectangle in figure 3). Upper midline was found to be shifted 2 mm towards right side with respect to the “Y – line” (Figure 3). Left mandibular cusp tip of canine is 3 mm ahead to the “X<sub>5</sub> – line” in respect to right mandibular canine in CTGJ (red circle in figure 3). Left mandibular first molar is 9 mm ahead to the “X<sub>3</sub> – line” in respect to right mandibular first molar in CTGJ (yellow rectangle in figure 3) which has remarkable effect on subdivision. So mesial positioning of left mandibular first molar is responsible for development of subdivision in this case. The lower midline was found to be shifted 2 mm towards right side with respect to the mid reference line (Figure 3).



**Figure 3.** Assessment of relative symmetry of maxillary and mandibular arch by Customized Transparent Graphed Jig on patient’s model.

## ADVANTAGE

1. No extra radiographic exposure required.
2. Patient chair-side time reduce markedly.
3. Intra operator bias can be eliminated.
4. Accurate prediction up to the 0.5 mm.
5. Precise treatment planning without the need of any midterm changes.

## DISCUSSION

In this article relative symmetry was well explained to its maximum precision by the customized transparent graphed jig. The graphic representation of the asymmetry was helpful to determine and quantify the asymmetry to the tune of 0.5 mm.

Rose et al found in his study that the mandibular first molar is responsible for development of Class II subdivision. He measured mandibular position relative to the cranium floor or to the mandibular condyle and found that the mandibular first molar are located more anteriorly on the Class I side.<sup>7</sup>

In most patients with Class II subdivision malocclusion, the maxillary dental midline is coincident to the mid-sagittal plane and mandibular dental midline has a minimal deviation. Correcting the interdental midline deviation with asymmetric premolar extraction (three premolar extraction) is easier, because it is achieved simultaneously with closing the extraction space in the mandibular arch. The asymmetric-extraction choice tends to be more successful in obtaining midline correction.<sup>8-10</sup>

## CONCLUSION

Diagnosis plays an important role in the treatment planning. As there is so many options are available for a clinician to treat a class II subdivision malocclusion case, it becomes the clinician’s duty to opt for the best modality fitting for a specific case. Before planning orthodontic treatment to correct subdivision problems, the location of the asymmetry must be identified. This customized transparent graphed jig helps clinician to locate the relative asymmetry. This jig also helps to compare the pre and

post treatment results.

## REFERENCES

1. Alavi DG, Begole EA, Schneider BJ. Facial and dental archasymmetries in Class II subdivision malocclusion. *Am J Orthod Dentofacial Orthop* 1988;93:38-46.
2. McNamara JA. Components of Class II malocclusion in children 8-10 years of age. *Angle Orthod.* 1981; 51:177-202.
3. Graber TM. Current orthodontic concepts and techniques. Philadelphia: W. B. Saunders Company; 1969.
4. Lewis EA, Albino JE, Cunat JJ, Tedesco LA. Reliability and validity of clinical assessments of malocclusion. *Am J Orthod* 1982;81:473-7.
5. Proffit WR, Field HW, Sarver DM. Contemporary Orthodontics 5th edition, C.V. Mosby Co; 2013. p. 180-181.
6. Wertz RA. Diagnosis and treatment planning of unilateral Class II malocclusion. *Angle Orthod* 1975 Apr;45(2):85-94.
7. Rose JM, Sadowsky C, BeGole EA, Moles R. Mandibular skeletal and dental asymmetry in Class II subdivision malocclusions. *Am J Orthod Dentofacial Orthop* 1994;105:489-95.
8. Janson GRP, Metaxas A, Woodside DG, Freitas MR, Pinzan AP. Three-dimensional evaluation of skeletal and dental asymmetries in Class II subdivision malocclusions. *Am J Orthod Dentofacial Orthop* 2001;119:406-18.
9. Janson G, Dainesi EA, Henriques JFC, de Freitas MR, de Lima KJRS. Class II subdivision treatment success rate with symmetric and asymmetric extraction protocols. *Am J Orthod Dentofacial Orthop* 2003;124:257-64.
10. Janson G, Cruz KS, Woodside DG, Metaxas A, de Freitas MR, Henriques JFC. Dentoskeletal treatment changes in Class II subdivision malocclusions in submentovertex and posteroanterior radiographs. *Am J Orthod Dentofacial Orthop* 2004;126:451-63.