

Case Report

To cite: Maharabam Gyanada, Amit KumarKhera, Sourabh Jindal, Preeti Rai, Varun Mehra- Treatment of class II division 1 malocclusion with combined surgical and orthodontic treatment: A Case Report 2019;3(1): 50-53.

Received on:
15-01-2019

Accepted on:
20-03-2019

Source of Support: Nil

Conflict of Interest: None

Treatment of class II division 1 malocclusion with combined surgical and orthodontic treatment: A Case Report

¹Maharabam Gyanada, ²Amit Kumar Khera, ³Sourabh Jindal, ⁴Preeti Rai, ⁵Varun Mehra

² reader

^{1, 3-5} post graduate students

¹⁻⁵ Subharti dental college, swami vivekanand subharti university, meerut, U.P.

ABSTRACT

This case report shows the management of a patient with skeletal Class II relationship with increased overjet by combined surgical and orthodontic treatment. When this patient reported to us, his maxillary first premolars were already extracted during unsuccessful orthodontic treatment 2 years back. Pre-surgical orthodontic treatment involving consolidation of spaces and creation of sufficient overjet was done. The bilateral sagittal mandibular advancement osteotomy with reduction genioplasty was performed by oral and maxillofacial surgeon. Skeletal and occlusal relationships reconstruction resulted in a more desirable facial profile and stable occlusion for this patient.

INTRODUCTION

Orthognathic surgery is a good treatment approach for patients with severe skeletal discrepancies beyond the reach of conventional orthodontic treatment. Combined surgical-orthodontic treatment aims to obtain a more harmonious facial, skeletal and soft tissue relationship as well as to improve occlusal function. It has been demonstrated that facial and dental abnormalities that affect facial appearance may result in social disadvantage. Hence patients undergoing orthognathic surgery may experience psychosocial benefits and improve their self-confidence, facial image and social adaptation.¹

A very important factor to be considered for surgical-orthodontic treatment is the paradigm of the soft tissues. It establishes that both the objectives and limitations of modern orthodontic and orthognathic treatment are determined by the facial soft tissues, not by teeth or bones.²

This case report illustrates the benefit of the team approach in correcting a class II skeletal deformity. A cosmetic correction was achieved by mandibular advancement with bilateral sagittal split osteotomy (BSSO) along with orthodontic treatment. The patient's facial appearance was markedly improved along with functional and stable occlusion

CASE REPORT

HISTORY AND CLINICAL EXAMINATION

A 18 years old male patient reported to the OPD with a chief complaints of spacing and backwardly placed lower jaw. Patient gave the history of previous fixed orthodontic treatment with extraction of all first premolars 2 years back.

On extra-oral examination patient had severely convex profile incompetent lips with eversion of the lower lip. On intra-oral examination there was angle class II molar and canine relation bilaterally, overjet of 10mm, deepbite, proclined upper incisors and spacing between upper teeth.

DIAGNOSIS

On cephalometric analysis the patient had class II skeletal pattern (ANB = 7°) with retruded mandible (SNB=72°), horizontal growth pattern (FMA= 20°) and the mandibular length was short (Go-Me) by 8mm. The maxillary incisors were protrusive, whereas the mandibular incisors were slightly retruded.

TREATMENT OBJECTIVES

- To achieve acceptable facial profile and an improvement in lip balance.
- To achieve normal overbite by leveling the curve of Spee and intrusion of upper anteriors.
- Retraction of the maxillary incisors while closing the maxillary anterior spacing.
- Correction of overjet by mandibular advancement

TREATMENT PLAN

As patient had already undergone extraction of all first premolar, when he reported to the OPD. Thus, after cephalometric evaluation and considering the soft tissues profile of the patient, the treatment plan included advancement BSSO with reduction Genioplasty. The decision was made to start presurgical orthodontic treatment with the aim of achieving a

good decompensation and preparing the patient for surgery.

TREATMENT PROGRESS

Pre-Surgical treatment

A full fixed preadjusted appliance (MBT .022x.028 3M Unitek) was placed. Alignment & leveling of maxillary &

The mandible was advanced to the desired position and a squash bite was taken. The presurgical cast was articulated in the advanced bite and a surgical acrylic splint was prepared, to be used during the surgery to position the mandible in the correct position (Fig 3).

SURGICAL TREATMENT

Cephalometric record Parameter	Norms	Pre-treatment	Post-treatment
SNA	82	79	79
SNB	80°	72°	77°
ANB	2°	7°	2°
GoGn-Sn	32°	26°	28°
U1- SN	105°	110°	107°
U1 – NA	22°	27°	24°
L1 – NB	25°	18°	19°
IMPA	90-110°	99°	91°
S-Line-Upper Lip	0mm	2mm	0mm
S-Line-Lower Lip	0mm	-4mm	0mm
FMA	25	23°	25°
Go - Pg	74mm	66mm	72mm
B - Pg	7mm	10mm	7mm

Table 1: pre-treatment & post-treatment cephalometric comparison

mandible arches were done with .014Niti, .016 Niti & .016x.022Niti. Space closer of generalized spacing in maxillary arch was initiated by sliding mechanics with active module tie on .019x.025 SS wire, upper and lower arches were coordinated and ask the patient to bring his mandible forward and check for any occlusal interferences.

Prior to surgery the patient had class II molar and canine relationship and overjet of 7mm. Mock advancement BSSO was performed using NemoCeph software and it was decided to advance mandible by 6mm. It was found that the chin became too prominent so it was decided to reduce the chin prominence by reduction genioplasty by 3mm to achieve a straight profile. Patient was convinced for the treatment with the help of the results of the mock surgery performed.

Advancement BSSO, with 6mm of mandibular advancement was performed along with 3mm of reduction genioplasty was performed by oral surgeon under general anesthesia surgical split was placed in patient mouth and Intermaxillary fixation was done for a period of 14 days.

POST-SURGICAL TREATMENT

The patient was shifted to 0.016” Niti wire and Box elastics were given for a period of 3 months in posterior region leading to extrusion of posteriors and closing of bite.

Final settling of occlusion was done with 0.016” Australian wire in upper and lower arch with the help of triangular elastics. (Fig 4).

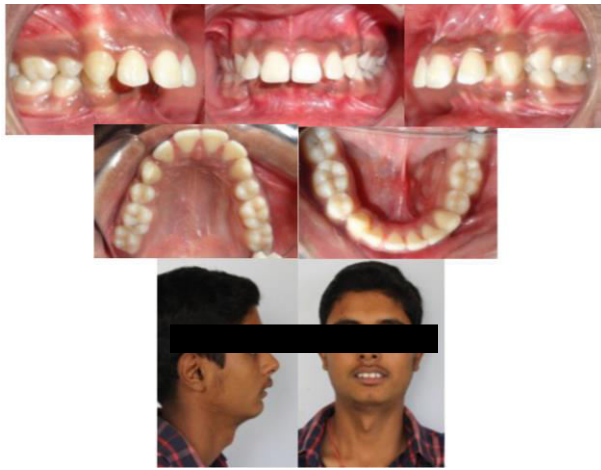

Fig 1: Pre-treatment photographs Extra-oral & Intra-oral

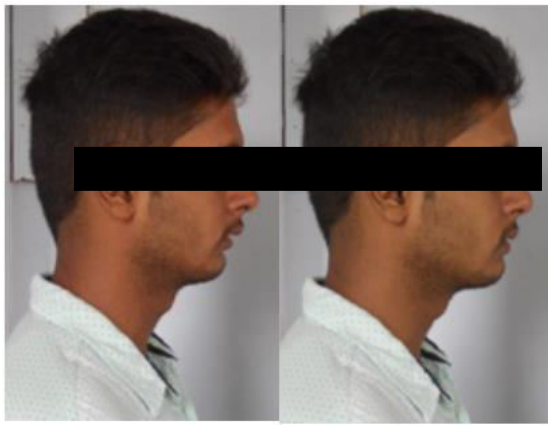

Fig 2: VTO

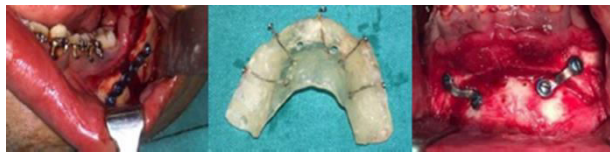

Fig 3: surgical splint

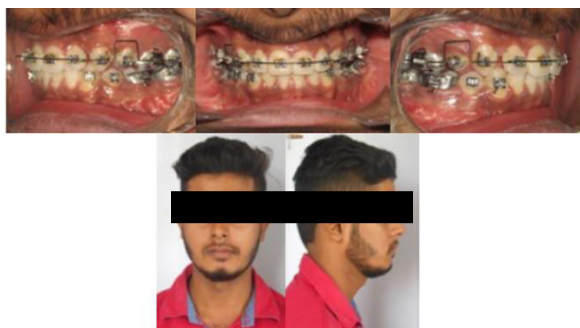


Fig 4: Post-surgical Photograph

RESULTS

Post treatment patients profile showed marked improvement. The patient had a well settled occlusion with Class I molar and canine relationship, ideal overjet and overbite. Superimposition of pre- and post-treatment lateral cephalograms showed that the treatment goals have been

achieved (Fig 5). The patient was pleased with the treatment outcome. The patient was debonded and was given beggs retainer for the upper arch and lingual bonded retainer for the lower arch. The occlusion remained stable and showed no relapse till 6 months after the treatment (Fig 6 & 7).

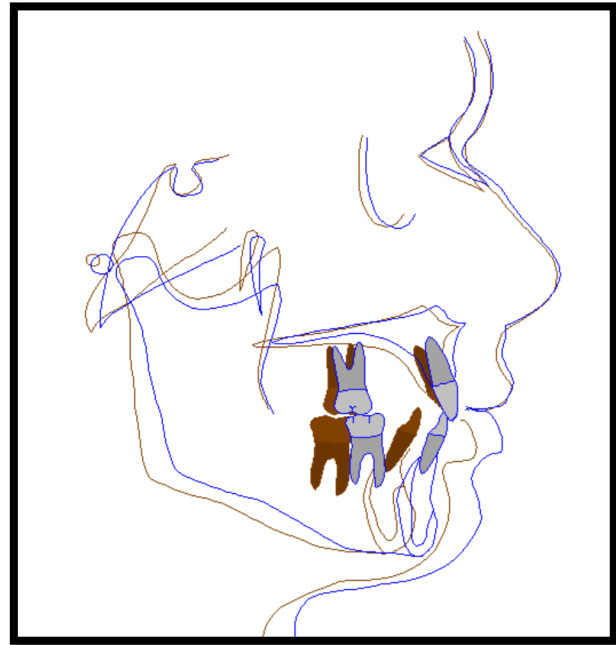


Fig 5: Pre and Post Superimposition

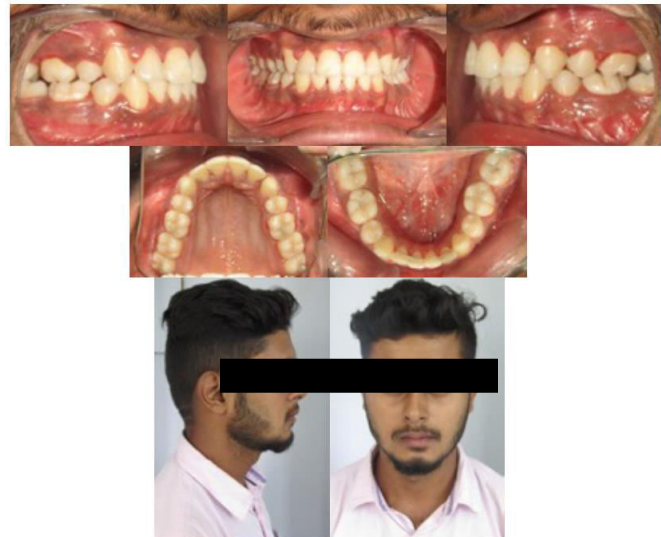

Fig 6: Post treatment photographs

DISCUSSION

Adult patients with skeletal Class II malocclusion can be treated using orthodontic (camouflage) or combined orthodontic-orthognathic surgery procedures depending on growth status and severity of the case^{3,4}. Orthodontic camouflage treatment includes upper incisor retraction with maximum anchorage to reduce the increased overjet thus flattening the nasolabial angle, lengthening lips and improving profile. A significant

improvement in the soft tissue profile is not possible because the dental movement limits the effectiveness of camouflage treatment; in some cases, the situation may worsen⁵. The camouflage treatment is limited to tooth movement, there will not be a pronounced improvement in the soft tissue profile, and it may also worsen in some cases. Besides, when attempting to fit the dental structures to the abnormal skeletal bases, the teeth move away from their ideal position within the jaw, resulting instability and health problems⁶. When all these limitations and disadvantages of camouflage treatment are taken into account, the orthodontic-orthognathic surgery combined treatment will be the best option in severe skeletal discrepancy cases.

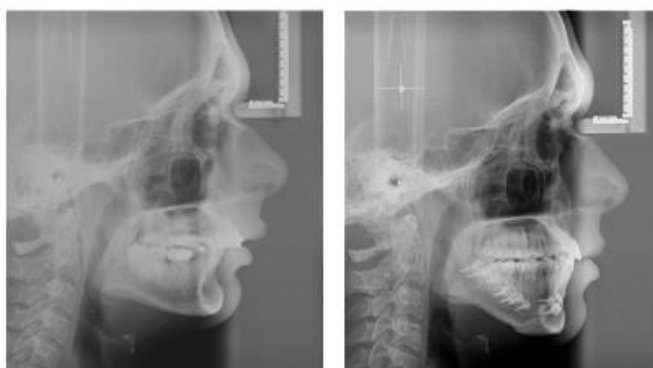


Fig 7: Pre & Post surgical lateral cephalogram

In patients with retrognathic mandible bilateral sagittal split osteotomy is the most commonly performed jaw surgery, either with or without upper jaw surgery⁷

Success in the surgical correction of dental-skeletal anomalies is determined by both the presurgical orthodontic treatment that eliminates dental compensation, and the correct surgical planning⁸.

In this case, upper arch had generalized spacing (3-4mm) and there was increased overjet of 10mm and the patient had very convex profile. As all first premolars had already been extracted, so we cannot correct all the problems with orthodontic camouflage treatment alone, so we decided orthodontic-orthognathic surgery combined treatment will be the treatment option in this patient. Since the mandibular length (Go-Pg) was short by 8mm, it was decided to advance the mandible by bilateral sagittal split osteotomy by 6mm to achieve an overjet of 2mm. As it had already been visualized in the NemoCeph tracing, that the chin became too prominent on mandibular advancement, reduction genioplasty was planned to reduce the chin prominence by 3mm.

CONCLUSION

It is of the utmost importance to have an interdisciplinary approach during the planning of the surgical-orthodontic treatment for establishing objectives and obtain good results.

REFERENCES

1. Hodge TM, Boyd PT, Munyombwe T, Littlewood SJ. Orthodontists' perceptions of the need for orthognathic surgery in patients with Class II Division 1 malocclusion based on extraoral examinations. *Am J Orthod Dentofacial orthop.* 2012; 142 (1): 52-59.
2. Khan L, Halwai HK, Yadav R, Birring OJ. Orthodontic Camouflage Treatment of Class II Malocclusion in Non-growing Patient-A Case Report. *Orthod J Nepal.* 2015;5(1):46-9.
3. Proffit WR, Sarver DM. *Treatment in Adults in Contemporary Orthodontics: Combined Surgical and Orthodontic Treatment.* 4th Edition. St Louis, Mosby; 2007.
4. Khera AK, Kumar A, Reddy CM, Singh K, Joshi D. Early Intervention of skeletal Class II Malocclusion by Twin Block Appliance Therapy. *J Contemp Orthod.*2017;4:54-63
5. Arnett GW, McLaughlin RP. *Facial and dental planning for orthodontists and oral surgeons.* Mosby, An imprint of Elsevier Limited; 2004.
6. Tucker MR. Orthognathic surgery versus orthodontic camouflage in the treatment of mandibular deficiency. *J Oral Maxillofac Surg.* 1995; 53:572-578
7. Ow A, Cheung L K. Skeletal stability and complications of bilateral sagittal split osteotomies and mandibular distraction osteogenesis: an evidence-based review. *J Oral Maxillofac Surg.* 2009;67(11):2344–2353
8. Proffit WR, Fields HR, Jr, Sarver DM. *Diagnosis and treatment planning in Contemporary Orthodontics: Orthodontic Treatment Planning: Limitations, Controversies, and Special Problems.* 4th Edition. St Louis, Mosby; 2007. pp. 302–307.