

To cite: Mitali Bora, Shweta Singh Bijay, Kuldeep Phukon - A Comparative Study of External Gonial Angle Between Panoramic and Lateral Cephalometric Radiograph of Adult Patients with Class – 1 Malocclusion and to Determine It's Cephalometric Value in Assamese Population. *Journal of Contemporary Orthodontics*, April-June 2019 2019;3(2): 15-19.

Received on:
26-04-2019

Accepted on:
15-05-2019

Source of Support: Nil

Conflict of Interest: None

A Comparative Study of External Gonial Angle Between Panoramic and Lateral Cephalometric Radiograph of Adult Patients with Class – 1 Malocclusion and to Determine It's Cephalometric Value in Assamese Population

¹Mitali Bora, ²Shweta Singh Bijay, ³Kuldeep Phukon

¹ Professor, Department of Orthodontics and Dentofacial Orthopaedics B.D.S, M.D.S, FWHO.
^{2,3}postgraduate student Regional dental college and hospital.

ABSTRACT

INTRODUCTION: The external gonial angle which plays significant role in the diagnosis of craniofacial disorders is routinely measured from lateral cephalogram and orthopantomogram. But how far these radiograph methods are reliable for the measurements of external gonial angle is a question which has been of much interest to investigators.

AIMS AND OBJECTIVES: To compare and discover any difference between the values of gonial angle obtained from the lateral cephalogram and orthopantomogram and also between the values of the male and female. To determine the value of external gonial angle in Assamese population.

MATERIALS AND METHOD: The study was conducted on the lateral cephalogram and orthopantomogram of 30 female and 30 male patients having Class-I skeletal malocclusion within the age group of 18-30 years. Each lateral cephalogram and orthopantomogram was traced twice and average value of each parameter was taken as the data.

RESULTS: In the study, the mean values of external gonial angle was 120.18 degree in panoramic radiograph and 121.75 degree in lateral cephalogram with no significant difference found in gonial angles obtained from lateral cephalogram and orthopantomogram between two genders.

CONCLUSION: The Gonial angle is an important parameter of the craniofacial complex which gives an indication about the vertical parameters and symmetry of the facial skeleton which can be correctly measured by both lateral cephalogram and orthopantomogram (OPG)

Key words: Gonial angle, lateral cephalogram, orthopantomogram(OPG), Assamese population.

INTRODUCTION

The external gonial angle is an important angle of the craniofacial complex¹. It is significant for the diagnosis of craniofacial disorders. For routine orthodontic diagnosis and treatment planning, lateral cephalogram and orthopantomogram were used. External gonial angle can be measured from both these radiographs. But how far these radiograph methods are reliable for the measurements of external gonial angle is a question which has been of much interest to investigators. The reliability of measurements of the gonial angles measured from lateral cephalograms is doubtful because of superimposed images appearing on lateral cephalograms. This disadvantage is not encountered in orthopantomogram which is being used increasingly for jaw examination. Mattila et al.² reported that the size of the gonial angle can be determined from the orthopantomogram with the same degree of accuracy as from the generally used lateral cephalogram, others stated that there was a great variation in gonial angle distortion and showed that the gonial angle differs by age and in different types of malocclusion.

The size of the gonial angle or mandibular angle, depends on the method of landmarks being used, i.e., whether the horizontal side of the gonial angle is formed by the tangent of the lower border of the mandible or by the straight line passing through gnathion². Both planes can be easily determined from a lateral cephalogram, whereas the determination of gnathion from an orthopantomogram involves possible inaccuracy in the gonial angle. Fischer- Brannides et al³. stated that in determining the gonial angle, the lateral cephalometric radiograph is preferred. However, Larheim and Svanaes⁴ indicated that lateral cephalograms did not permit reliable registration of the gonial angle, and the superimposed images created difficulties in recognition and measurement of the individual angles, whereas the gonial angle assessed from a panoramic film was almost identical to that measured on the dried mandible. This prompted the present study to compare the accuracy of gonial angle measures and also to determine cephalometric value of external gonial angle in Assamese

population.

In this present study, the external gonial angles were measured and compared to find out any differences between the values of gonial angles obtained from orthopantomogram in both right and left side and lateral cephalogram. Comparison was also done to find out any difference between the values of gonial angle obtained from orthopantomogram and lateral cephalogram in both male and female patients and to determine cephalometric value of external gonial angle in Assamese population. As no such study was conducted in this region, so it was thought pertinent to carry out this study in adult patients with class I skeletal malocclusion who have reported for treatment to the department of Orthodontics, Regional Dental College, Guwahati.

MATERIALS AND METHODS

The study was conducted on lateral cephalogram & Orthopantomogram of 30 male and 30 female patients having Class –I skeletal malocclusion within the age group of 18-30 years. Standard orthopantomographs and lateral cephalometric radiographs were done with same magnification, all the radiographs being taken with the same machine and by the same operator. The radiographs were taken with Advapex Panoramic system in natural head position. The film distance to the X-Ray tube was fixed at 5 feet. The distance from the film to the mid sagittal plane of the patient’s head was also fixed at 15 cm. Films were exposed at 75KV, 10mAs and a filter of 2.5mm aluminium equivalent was also used. The selected radiographs have been traced onto a sheet of cellulose acetate by using a 2H pencil. The Cephalometric landmarks were located, identified and marked. The lines and angles were drawn and measured using a cephalometric protactor and calipers. The Assamese ethnicity of the patient were traced down to two generation

For determination of Skeletal class I malocclusion, the following parameters were used. 1.SNA, SNB & ANB angle, 2.FMA, 3. FACIAL angle, 4. WITS analysis

In panoramic radiograph, the gonial angle was drawn by the line tangent to the posterior border of the mandible and the

light box. Therefore, the right and left gonial angles were obtained and measured with protactor. The Measurement error was determined by re-measuring the panoramic parameters. (Fig 1) In lateral cephalogram, this angle was drawn by the ramus line (RL) and the mandibular line (ML), where RL was the tangent to the posterior border of the mandible and ML tangent to the posterior border of the mandible. In fig-2 the point was measured with the help of calliper and traced on acetate paper by using 2H pencil on illuminated light box and the gonial angles were measured with protactor. The measurement error was determined by re-measuring the cephalometric parameters. (Fig 2)




Fig 1. External gonial angle Rt& Lt in orthopantomogram

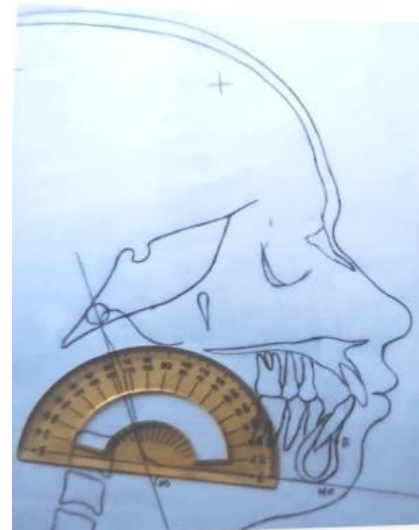


Fig 2. External gonial angle in the lateral cephalogram

RESULTS AND DISCUSSION

Variabes	Mean	Standard Deviation	Range
Gonial angle in cephalogram	121.75	7.68	105-136
Gonial angle in OPG	120.18	7.30	104-136
Right Gonial angle in OPG	120.45	7.64	104-136
Left Gonial angle in OPG	119.92	7.50	102-135

tangent of the lower border of the mandible. In fig-1 this was drawn by using a 2H pencil on acetate paper on illuminated

The collected data were subjected to different statistical analysis

to find the differences of lateral cephalometric measurements and OPG, both right and left side and also to find the differences among male and female subjects. Statistically significant differences between different parameters were evaluated with the Student's T test and Regression and Correlation analysis. These analyses were performed using SPSS (Version 17.0, Chicago, IL), with a probability level of $P < 0.05$ considered to be statistically significant and a level of $P < 0.01$ considered to be highly significant.

Following result were observed: - (Table 1, 2 and fig 3,4,5)

Gonial Angle	N	Mean	SD	T	P Value	Mean Differ.
LAT.CEPH	60	121.75	7.68	1.146	0.254	1.56667
OPG	60	120.18	7.30			
OPG-RT	60	120.45	7.64	0.386	0.7	0.53333
OPG-LT	60	119.92	7.50			
LAT.CEPH(Male)	30	121.67	7.69	0.921	0.361	1.83333
OPG (Male)	30	119.83	7.73			
LAT.CEPH(Female)	30	121.83	7.80	0.682	0.498	1.3
OPG(Female)	30	120.53	6.95			
LAT.CEPH.	60	121.75	7.68	0.93	0.355	1.3
OPG.RT	60	120.45	7.64			
LAT.CEPH.	60	121.75	7.68	1.323	0.188	0.1883333
OPG-LT	60	119.92	7.50			

Table2. Statistical evaluation to determine the difference in values of gonial angle as measured in OPG (Right &Left). Lateral cephalogram and also the difference between male and female

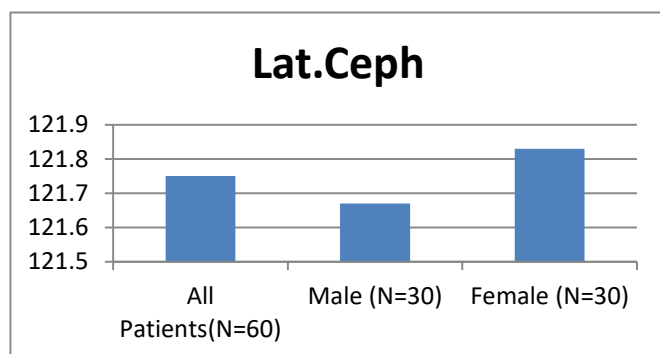


Fig3. Gonial angle in lateral cephalogram. in degrees

The average gonial angle of Assamese population found to be 121.75 with no significant difference with other population. The mean age of the patients recorded in years were 21.88 ± 3.55 , male patients were 21.67 ± 3.75 and female patients recorded 22.10 ± 3.38 . The mean value of the gonial angle in lateral cephalograms was 121.75° with a standard

deviation of 7.68° . The gonial angle in female was 121.83° and that in males 121.67° with no statistically significant difference between the two genders. The mean value of the gonial angle in panoramic radiographs was 120.18° with a standard deviation of 7.30° . The gonial angle in female was 120.53° and that in males 119.83° with no statistically significant difference between the two genders. This present study was conducted on lateral cephalogram and orthopantomogram which were obtained in natural head position by the same operator and not show any significant difference between the two radiographs ($P = 0.254$).

The study has shown less mean values of external gonial angle in both the panoramic and lateral cephalogram as compared to that of the previous values studied by Shahabi¹.

Shahabi et al¹ compared the external gonial angle determined from the lateral cephalograms and panoramic radiographs in Class I patients. Based on the obtained results, they concluded that panoramic radiography can be used to determine the gonial angle as accurately as a lateral cephalogram. Mattila et al² reported a gonial angle of 127.8° in the panoramic radiograph and 128.6° in the lateral cephalogram. Although both means were also greater than the present study, the differences between the two means in his study was also insignificant. Ongkosuwito et al. (2009)⁵ concluded that an OPG is as reliable as a lateral cephalogram for linear measurements of the mandible, i.e., condylion-gonion, gonion-menton and condylion-menton.

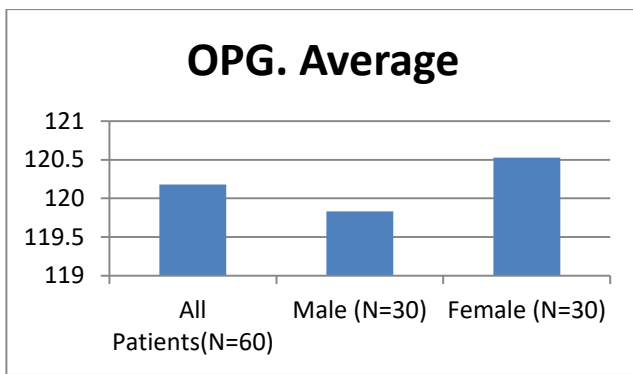


Fig4. Gonial angle in OPG in degrees

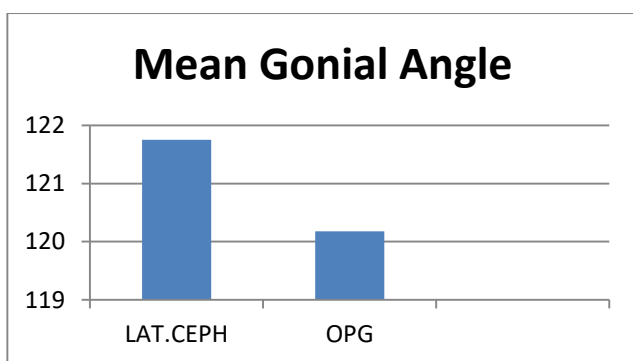


Fig5. Gonial angle in lateral cephalogram and OPG in degree

In conclusion, Keijo Mattila et al, in their study demonstrated that the size of gonial angle can be determined from the orthopantomogram with the same degree of accuracy as from the commonly used lateral cephalogram, the gonial angle being formed by the tangent of the lower border of the mandible and the distal border of the ascending ramus and the condyle on each side. They also showed that the right and left gonial angles can be easily determined individually from the orthopantomogram, thus avoiding the disturbing influences of the superimposed images found on lateral cephalogram. It proves conclusively that the orthopantomogram is the more obvious choice for determination of the gonial angle. The present study also showed no significant difference in the values of gonial angle in both panoramic and lateral cephalograms.

The result of this study present showed that there were no significant differences between the mean values of the external gonial angle in the panoramic radiograph and lateral cephalogram (1.57°) and the mean values of the right and left gonial angles in panoramic radiographs (0.53°). According to t-test, there were no significant differences between panoramic radiographs and lateral cephalogram methods in determination of the gonial angle. In addition, gender did not have a considerable effect on the gonial angle in both radiographs. It may be concluded that both the radiographs

can be used to determine the gonial angle as accurately. Although, in panoramic radiography the right and left gonial angles can be measured easily without superimposition of anatomic landmarks, which occurs frequently in a lateral cephalogram.

The average Gonial angle in panoramic radiograph in study shown 120.18°. It is worth mentioning that the mandibular angle varies in different human population groups where the average values were (119°) in Indian, Chinese and Peruvian mandibles, (110°) in that of the Neanderthals, (128°) in the European population, (120°) in Xanthoderms and African Negroes¹⁸ and (124°) in Jordanians¹⁷. In the present study, the mean gonial angle was (123.6°) for the included Egyptian population sample. The small the difference in mandibular angle measurements between different population groups indicates some degree of homogeneity between these groups; however, when this difference is relatively high, it may be considered for racial/population identification.⁶

CONCLUSION

The following conclusion can be drawn from this study:

- There were no statistically significant differences found in gonial angles obtained from lateral cephalogram between two genders.
- There were no statistically significant differences found in gonial angles obtained from orthopantomogram between two genders.
- There were no statistically significant differences in orthopantomogram of both sides (Rt. and Lt.) in male patients.
- There was also no statistically significant difference in orthopantomogram of both sides (Rt. and Lt.) in female patients.
- There is no statistical significance found in the accuracy of measurement of gonial angle between lateral cephalogram and orthopantomogram.
- The average gonial angle of Assamese population found to be 121.75 with no significant difference with other population.

REFERENCES:

1. Mostafa Shahabil, Barat-Ali Ramazanzadehl and NimaMokhber. Comparison between the external gonial angle in panoramic radiographs and lateral cephalograms of adult patients with Class I malocclusion. *Journal of Oral Science*; 2009, Vol. 51, No. 3: 425-429.
2. Mattila K, Altonen M and Haavikko K (Angle Ortho. 197:vol. 47, No. 2, P- 107- 110).

3. Fisher -Brandies H, Fischer -Brandies E, Dielert E. The mandibular angle in the orthopantomogram . Radiologe. 1984; 24, 547-549. (in German).
4. Larheim TA, SvanaesDB.Reproductibility of rotational panoramic radiography: mandibular linear dimensions and angles. Am J Orthod Dentofacial Orthop.1986; 90, 45-51.
5. Izard G. The Goniomandibular angle in dentofacial orthopedia. Int. J. Orthodontia.1927; 13, 578.
6. Wylie, Wendell L.The Assessment of Anteroposterior Dysplasia. Angle Orthodontist. 1949; 17, 97- 109.

measurements: Comparison Between orthopantomograms and lateral cephalograms. Cleft Palate Craniofac J 2009;46:147-53.

17. Al-Shamout R, Ammouh M, Alrbata R, Al-Hababba A