

Geometric Morphometrics of Maxillofacial Anatomy, Growth and Anomalies: Clinical and Research Application

¹Kusum Lata Agarwal, ²Mani Dwivedi, ³Ram Autar, ⁴Shantanu Khattri, ⁵Madhvi Bhardwaj

To cite: kusum Lata Agarwa , Mani Dwivedi, Ram Autar, Shantanu Khattri, Madhvi Bhardwaj- Geometric Morphometrics of Maxillofacial Anatomy, Growth and Anomalies: Clinical and Research Application, Journal of Contemporary Orthodontics, April-June 2019;3(2): 26-32.

^{1,2}M.D.S Orthodontist
^{3,4,5}Prof., Orthodontist,
^{3,4,5}Career Post Graduate Institute Of Dental Sciences & Hospital

ABSTRACT

Morphometrics is used to describe the size, shape and form of any object as well as organisms or a part of organism. Geometric morphometrics is the quantitative representation and analysis of morphological shape using geometric coordinates instead of measurements. The use of geometric morphometrics in clinical orthodontics is to accurately locate the landmark matrices of each of the individuals into morphometric space created around the consensus .The relative location in this space, defined by the two main components explaining biggest shape variation within a given population , represents , the skeletodental diagnosis . Thus, the morphometrics distance of each case will be indicative of the clinical severity of case. Therefore, each diagnostic case would have a precise location into morphometrics space in relation to its expression of skeletal malocclusion as well as its expression of skeletal vertical pattern. Thus this article aims to review the application of geometric morphometrics: clinical and research; in an effort to provide a better understanding of the subject for an interpretation that will stimulate researches in this field of study.

Key words: Geometric Morphometrics, Maxillofacial Anatomy, Growth, Anomalies.

Received on:

05-04-2019

Accepted on:

13-05-2019

Source of Support: Nil

Conflict of Interest: None

INTRODUCTION

“The study of form may be descriptive merely, or it may become analytical. We begin by describing the shape of an object in the simple words of common speech: we end by defining it in the precise language of mathematics; and the one method tends to follow the other in strict scientific order and historical continuity” by D’Arcy Wentworth Thompson (1915).

Morphometrics is used to describe the size, shape and form of any object as well as organisms or a part of organism .Morphometrics is important as it allows us to compare shapes of different organisms much better than word descriptions. The main goal of morphometrics is to study how shapes vary and their covariance with other variables. This shift to quantitative descriptions is in part due to advances in statistical analysis methods and software development that allowed interpreting collected data.

First method of morphometrics was called as *Traditional morphometrics* involved linear distances (such as length, width, and height) and multivariate statistical tools to describe patterns of shape variation within and among groups. However, the biggest problem was its inefficiency in describing the shape of an object as linear distances are highly

correlated with size of an object which makes the shape analysis difficult. To overcome these problems a more sophisticated method called *Geometric morphometrics* was created.

Geometric morphometrics is the quantitative representation and analysis of morphological shape using geometric coordinates instead of measurements. The use of geometric morphometrics in clinical orthodontics is to accurately locate the landmark matrices of each of the individuals into morphometric space created around the consensus .The relative location in this space, defined by the two main components explaining biggest shape variation within a given population , represents , the skeletodental diagnosis . Thus, the morphometrics distance of each case will be indicative of the clinical severity of case. Therefore, each diagnostic case would have a precise location into morphometrics space in relation to its expression of skeletal malocclusion as well as its expression of skeletal vertical pattern¹.

Diagnostic procedures in orthodontics have remained relatively unaltered since the advent of cephalometrics in the early 30’s and 40’s. Two scientific fields are making a discernible impact on orthodontics. One field is the theoretical domain of Geometric Morphometrics (GM), which provides new mathematical tools for the study of shape, and the other is the technological field of computed tomography (CT) which provides data for three dimensional visualization of craniofacial structures.

Orthodontists till date prefer simulations of 2D cephalograms from 3D CBCT data, in an effort to retain compatibility with old diagnostic methods instead of developing newer techniques. Accuracy and re of measurements and thus their diagnostic interpretation remains of questionable value. A 3D cephalometric analysis should be developed starting from a complete over of current practices and should incorporate geometric morphometrics methods for incorporation of shape. Currently no such analysis exists, although efforts have been made ². Thus, whereas CBCT imaging is incredibly being used, most of the available information remains unexploited; evaluated either in a quantitative manner or by regressing it.

Thus this article aims to review the application of geometric morphometrics: clinical and research; in an effort to provide a better understanding of the subject for an interpretation that will stimulate researches in this field of study.

ADVANCES OVER THE PAST DEACDE

Evaluating the relationship of the structural components of the human face is an important diagnostic factor in Orthodontics, Maxillofacial, Craniofacial and Plastic surgery and dysmorphological genetics. In order to accomplish this task, radiographic techniques have been used for abstracting the human head into a measurable geometric scheme allowing for comparison of morphology. This task of measuring the degree of similarity between forms is based on the theories of Morphometrics. It has a long history propelled by the desire to abstract form from the variety of organisms, dating from ancient Greece to a more modern study by D'Arcy Thompson.

The dawn of the 21st century brought with it the maturation phase of geometric morphometrics and the emergence of the Procrustes paradigm as the standard methodological approach for analyzing shape characterized by landmark data. According to Rohlf , this was due to the realization that Procrustes-based approaches outperformed alternative methods from a statistical perspective .However, despite the pre-eminence of this approach to shape analysis, much theoretical progress continues in the discipline. Particularly active work has been the development of more specialized applications to address particular biological problems and hypotheses ³.

One major change in geometric morphometrics from a decade ago has been the rapid increase in the use of three-dimensional data. Interestingly, there are generally no mathematical limitations for handling data in three dimensions. Indeed the algorithms commonly used for superimposition, projection and statistical analysis are all generalized to accommodate data of any dimensionality. Instead, the restriction to two dimensional data has been decidedly more practical. Until recently, acquiring three-dimensional data required specialized

equipment and was prohibitively expensive and the use of many three-dimensional devices was limited to specimens in a restricted size range. However, over the past decade a number of lower-cost options have become available, including surface scanners and other data-collection devices. These devices are now more accessible to the research community.⁴

Geometric morphometric analysis are typically performed on landmark coordinates describing specific anatomical locations (i.e., “fixed” anatomical points), yet the shape of other anatomical features may also be of interest. For example, semilandmarks can be used to capture the shape of boundary curves, which can then be included with a set of fixed landmarks in a Procrustes-based shape analysis .With this approach, a series of locations along the curve are digitized, and an additional step may be incorporated in the Procrustes algorithm which slides these points along vectors tangent to the curve until their positions align as closely as possible with the semilandmarks. Gunz et al ⁵ used this algebra for semilandmarks and have extended to three dimensions, so that the shapes of both curves and surfaces can be quantified. Oxnard and O'Higgins ⁶ said that care must be taken when placing semilandmarks relative to other structures. Additionally, these methods tend to work best when used on relatively smooth curves and surfaces, or when many points are included. Nevertheless, by using both landmarks and semilandmarks, information from points, curves, and surfaces may be combined for a more comprehensive quantification and analysis of biological shape variation.

STEPS IN GEOMETRIC MORPHOMETRICS

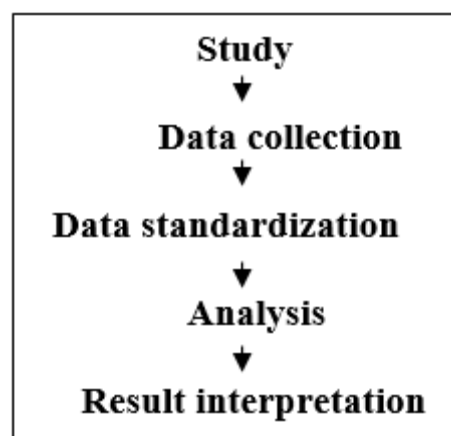


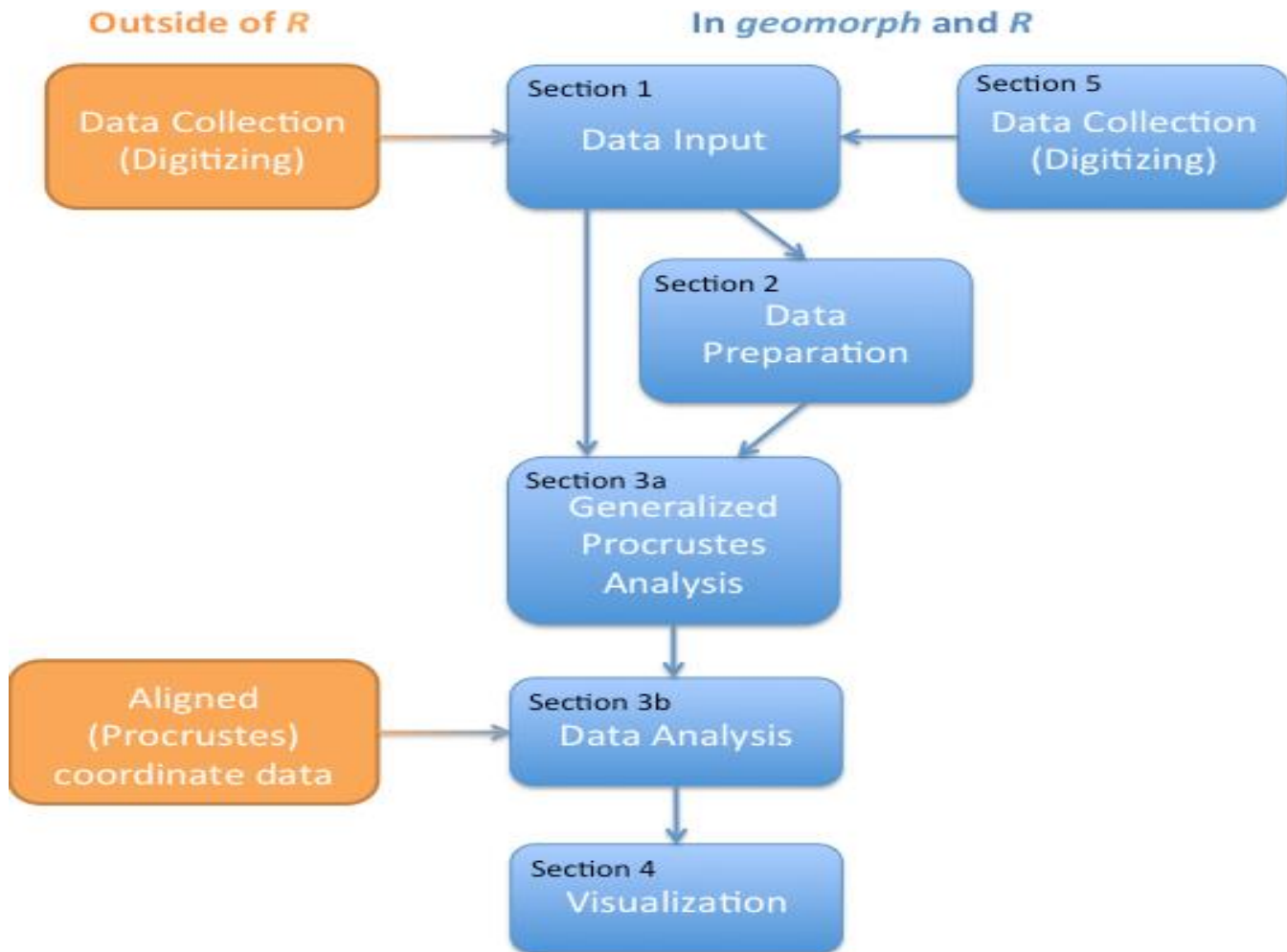
Fig 1: Overview of the morphometric analysis process

APPLICATIONS

In recent past years has provided new methods for the 3D analysis of human facial morphology. Although the use of geometric morphometrics (shape analysis) is not appreciated in clinical dentistry yet, valuable insights in shape changes and

variations ,applicable in the field of orthodontics,clinical genetics ,maxillofacial and plastic surgery, anthropometrics, descriptive medicine and forensic medicine may so be

provided by a set of inter landmark distances. One of the most recent fields of application is the biological analysis of statistical outlines that is of abnormal morphologies that can



appreciated in near future. It is also ideal for studying growth ageing or other changes in shape of structures anticipated because of an identified biomechanical stimulus e.g. shape analysis of the growth of the mandible. Techniques applied in the 3D structure analysis can also be applied to 2 D structure analysis.

Some of the application are as follows:

Esthetic Indices:

One of the applications of 3D geometric morphometrics is the definition of aesthetic index. In the quest for mathematical definition of facial beauty and attractiveness, 3D facial evaluation is considered to be more accurate.⁷

Craniofacial Abnormalities:

Several human syndromes are characterized by a destructive set of craniofacial abnormalities and their objective analysis could help the clinician treating with distortive patients. Additionally 3D surface (laser scans, stereophotogrammy) or volumetric (CT, MRI) data permits a better analysis of facial configuration than that

derive from congenital or acquired malformations, trauma or surgery. In these instances, common methods fail to provide a correct representation and quantification of the allied morphology and dedicated algorithms are necessary.⁸

Facial Ageing:

The assessment of the normal patterns of facial aging is a current matter of interest, where both the modifications in facial dimensions and the variations in facial motion are being considered. For instance, as recently reviewed by Rosati et al. (2012), with age there is a decreasing display of maxillary incisors coupled with a concomitant increase in exposure of mandibular anterior teeth: increments in upper lip length, decrements in the muscular ability to perform a smiling task, and thinning of upper lip muscles can all contribute to these modifications. Thus, geometric morphometrics plays an important role in evaluating dentolabial relationships, adding the effect of motion (time dimension) to the 3D assessment of facial structures.⁹

Facial Reconstruction:

In the field of facial reconstruction, reference values for both sexes from selected ethnic groups and ages are necessary. 3D facial images can be usefully employed with the current 3D computerized methods, finding applications in the dentistry, forensic and archaeological fields. Lee et al.¹⁰ proved the efficacy of facial reconstructions made starting from CBCT 3D facial scans of living subjects. Considering that the subjects are scanned in an upright position, these instruments are likely to perform better than conventional CT, where the subjects are supine.

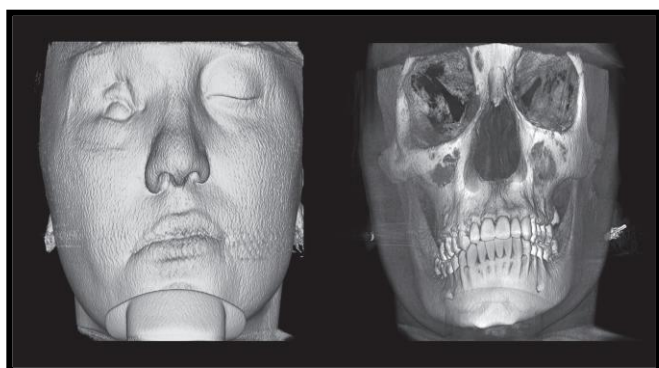


Fig 2: Three-dimensional reconstruction of craniofacial hard and soft tissues in a 24 years old woman. The images were obtained with cone beam computerized tomography (White Fox, De Goetzen, Olgiate Olona, Varese, Italy; X-ray tube voltage 105 KV, X-ray tube current 8 mA). A cephalometric, expanded field of view was used (diameter 200 mm, height 170 mm). A: soft tissue reconstruction. A notable facial asymmetry can be observed (the left labial commissure is more cranial than the right one, the right nasal ala is bigger than the left one), together with alterations in the right orbital area. B: hard tissue reconstruction. The occlusal plane is asymmetric, and the right orbital cavity altered

FACIAL MUSCLE MOTION:

The influence of facial muscles motion on facial morphology has been investigated by Maal et al. who found that intentional laughing increased the mean registration error between repeated 3D facial images by 300-400%. Involuntary facial muscle movements were analyzed by Lübbers et al. (2012), who found a mean error of 0.32 mm in adult healthy subjects. Facial modifications may also pose problems for automatic individual identification and recognition and a possible solution was proposed by Aeria et al. (2010) by mathematically decomposing the effects of facial motion. Hence geometric morphometrics was useful in assessing dynamic functions such as facial muscle motions¹¹.

3D Diagnostics In Orthodontic And Orthognathic Surgery:

Orthodontists and orthognathic surgeons can finally assess the case in 3 D without any simplifications and image distortions. 3D diagnostic possibilities in the field of orthognathic surgery and complex skeletal defects diagnostics need to be treated in a slightly different way. Simulation of surgery in virtual

operating room, assessment of virtual final outcome in relation to esthetics and occlusal function has long been postulated. Such preclinical data could contribute to creating new procedures and improve the efficacy and predictability of currently used surgery protocols. The effect of surgery by 3D supported planning and diagnostic procedures are bound to improve as compared to the conventional one.

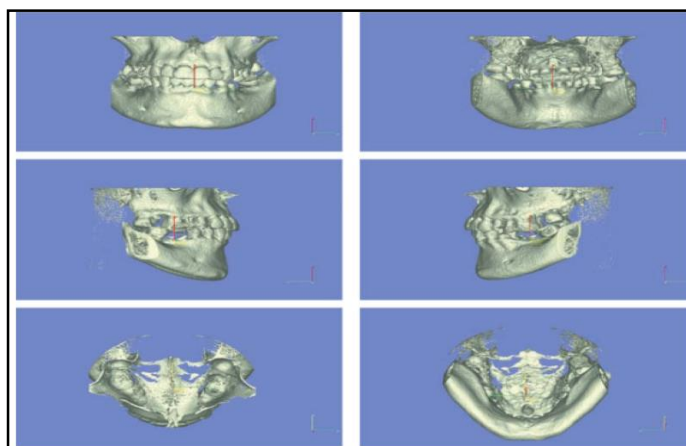


Fig 3: Comparison between 3D digital model created on the basis of MSCT and CBCT

Evaluation Of Dental Morphometrics During The Orthodontic Treatment:

Nowadays we try to replace standard plaster casts by scanned objects and digital models. Geometrically calibrated images aid in the comparison of several different steps of the treatment and show the variation of selected features belonging to individual biomedical objects. Geometric morphometrics represents a new approach to the evaluation of variability. Its methods based mainly on the 3D co-ordinates of homologous landmarks that describe the studied object. The co-ordinates thus represent a complete set of geometric information related to the object under study. This system enables the differentiation of variability by both size and shape. The quantification of shape and size specifies and renders more accurate results than those that have been obtained to date with other methods, thus increasing the reliability and accuracy of dental geometry measurements in clinical practice.¹²

To Study Skull Morphology During Growth:

Geometric morphometrics is a powerful tool for the study of morphological variation that possesses numerous advantages over the more traditional approach based on linear measurements. Geometric morphometrics appeared more sensitive than the traditional method in detecting variation in skull morphology, but both approaches led to very comparable conclusions. Phenotypic plasticity is an alternative explanation to local adaptations for eco geographical morphological variation.¹³

Skeletodental Diagnosis Using Geometric Morphometric

Approach:

In orthodontics and maxillofacial surgery, dentoskeletal diagnosis is essential for treatment planning. In order to study the variation of dentoskeletal pattern in Chilean population, Alejandro Díaz Muñoz & Germán Manríquez Soto (2014) used standard methods of geometric morphometrics to a sample of 150 lateral radiographs of classes I, II division 1 and III were applied. They found that classes I, II and III show statistically significant differences associated to a greater degree, with a sagittal maxillo-mandibular relationship, and to a lesser degree with a vertical growth pattern, allowing positive discrimination of intermediate phenotypes. Thus they concluded that tools of geometric morphometrics constitute a complementary and effective approach to address unresolved problems associated with conventional cephalometric analysis. Geometric morphometrics is used in clinical orthodontics to accurately locate the landmarks matrices of each of the individuals into morphometric space created around the consensus or average. The relative location in this space, defined by the two main components explaining the biggest shape variation within a given population, represents, in our opinion, the skeletodental diagnosis. Thus, the morphometric (Procrustes) distance of each case with respect to the consensus (at the intersection of the two principal axes) will be indicative of the clinical severity of the case. Therefore, Díaz & Manríquez said that each diagnostic case would have a precise location into the morphometric space in relation to its expression of skeletal malocclusion as well as its expression of skeletal vertical pattern.¹⁴

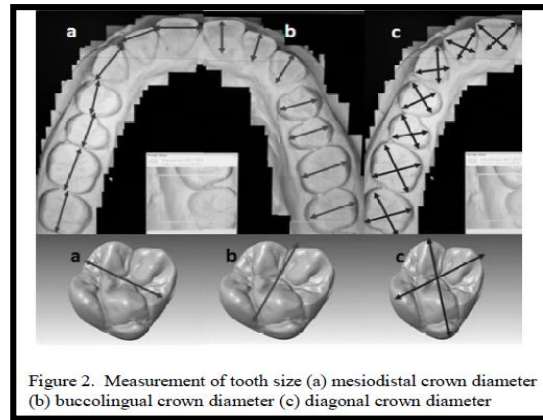

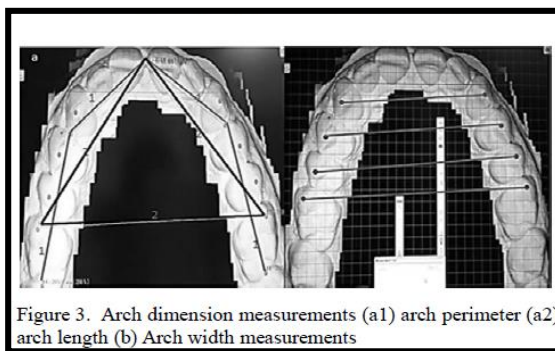


Fig 4 : Geometric morphometrics of tooth size and arch dimension

To Evaluate Posterior Airway Space Following Biobloc Therapy:

Geometric morphometrics can also be used to evaluate changes in the posterior airway space in patients. Functional changes in the posterior airway space, as well as dentofacial improvements, are associated with Biobloc treatment.¹⁵

Fig 5: MorphoStudio software showing finite-element analysis. Using the pseudo-color scale, a 31% increase in relative size (orange color) is found in the nasopharyngeal area above and behind the dorsum of the soft palate, post-treatment. In addition, a 23% increase in relative size (light orange color) is located in the oropharyngeal behind the base of the tongue, and a 9% increase in relative size (yellow color) is identifiable in the hypopharyngeal area near the level of the hyoid bone following Biobloc treatment.

Geometric Morphometric Evaluation Of Cervical Vertebrae Shape And Its Relationship To Skeletal Maturation:

Cervical vertebrae shape has been proposed as a diagnostic factor for assessing skeletal maturation in orthodontic patients.

However, evaluation of vertebral shape is mainly based on qualitative criteria. Studies were done to measure vertebral shape by using the tools of geometric morphometrics and to evaluate the correlation and predictive power of vertebral shape on skeletal maturation¹⁶.

CONCLUSION

Morphometrics is one of the most dynamic and popular fields in the contemporary biology seen in general and orthodontics in particular. 2D data has long been a major data type in geometric morphometrics. The hyper capability of geometric morphometrics in scientific computing and problem solving based on 2D data has been well demonstrated. However, there are still special scientific problems which cannot be easily investigated with 2D data. The 3D data on a large scale and in a greater amount would be a better alternative for this mentioned issue.

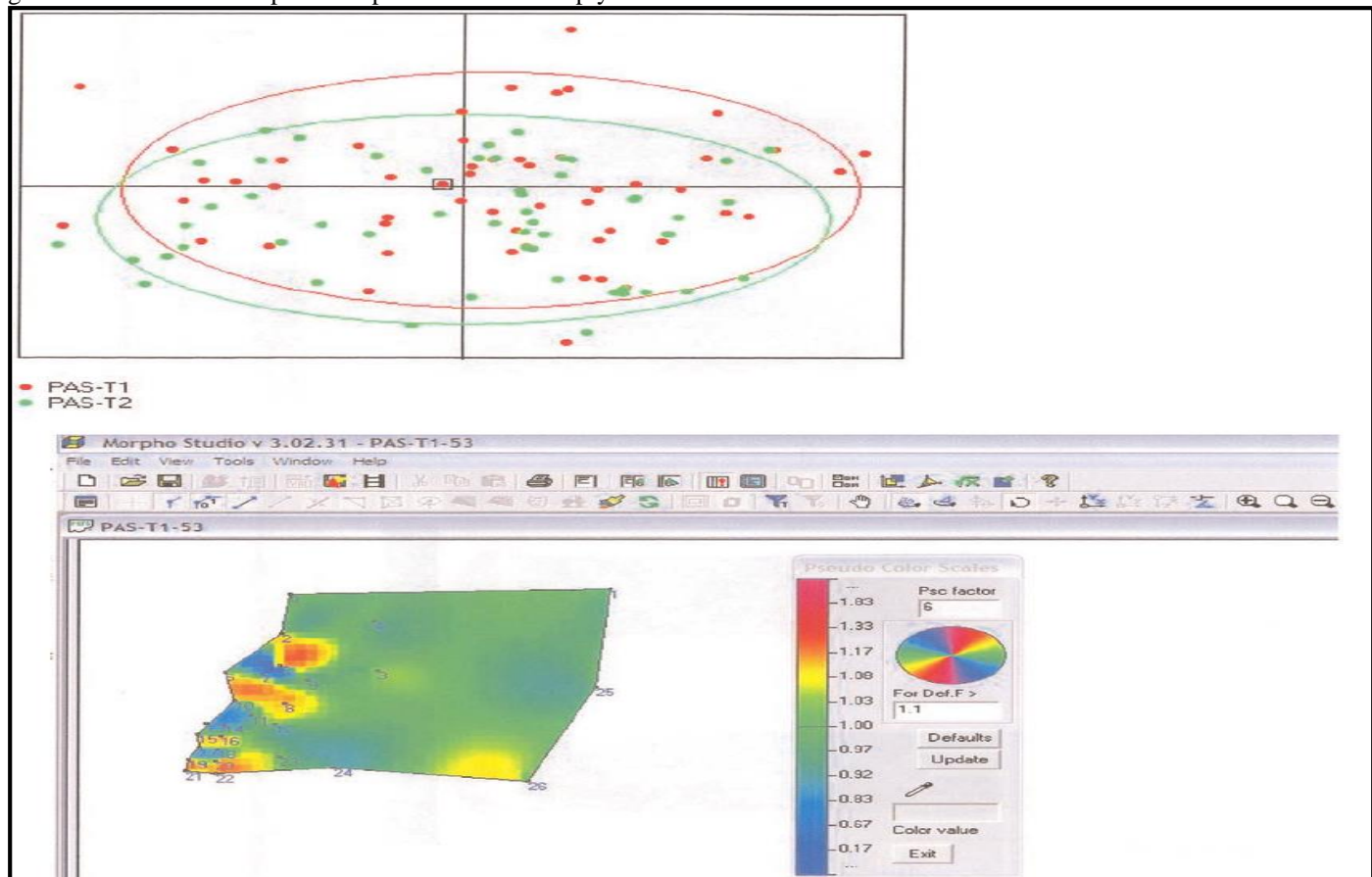
FUTURE DIRECTION

Recent studies have used morphometrics and 3D imaging to quantify variations in craniofacial morphogenesis contributing to mechanistic studies of embryo development. Therefore, morphometrics and 3D imaging of embryo have significant importance for developmental biology. The wider opportunity for

combining 3D imaging and morphometrics lies in the challenge of quantitative integration across the phenotype and genotype map, i.e. the development of techniques and statistical methods that quantify morphology in combination with molecular and cellular data.

Combining data on cellular dynamics and morphology offers tremendous potential to study mechanics of morphogenesis and their relationship to structural birth defect. Micro CT and OPT are steps towards this goal.

Personalized /precision of medicine are unlikely to make significant inroads for structural birth defects based on genomic alone. Developmental processes are simply too



complex for prediction to bypass quantitative understanding of the role of development in genotype and phenotype map. This can only be realized through significant investment in imaging and morphometrics as applied to development.

REFERENCES

- 1) Díaz, A., Manríquez, G. Diagnóstico ortodóncico mediante morfometría geométrica. Libro de resúmenes 53 Reunión de la Sociedad Española de Ortodoncia. Cádiz, España, 2007
- 2) Swennen G, Schutyser FAC, Hausamen J-E. Three-dimensional cephalometry. A color atlas and manual. Berlin/Heidelberg: Springer 2005: 320
- 3) Dean C. Adams, F. James Rohlf, Dennis E. Slice. A field comes of age: geometric morphometrics in the 21st century. *Hystrix, the Italian Journal of Mammalogy* 2013; Volume 24 (1): 7–14
- 4) Bookstein F.L. The Measurement of Biological Shape and Shape Change. Springer Science & Business Media 2013 Mar; 1-360
- 5) Gunz P, Mitteroecker P, Bookstein F L. landmarks in three dimensions. In: Slice D.E. (Ed). *Modern morphometrics in physical anthropology*. Kluwer Academic/Plenum, New York 2005 :73-98
- 6) Oxnard C., O'Higgins P., 2011. Biology Clearly Needs Morphometrics. Does Morphometrics Need Biology? *Biol. Theory* 4: 84–97.
- 7) Kochel J, Meyer-Marcotty P, Strnad F, Kochel M, Stellzig-Eisenhauer A. 3D soft tissue analysis--part 1: sagittal parameters. *J. Orofac. Orthop* 2010;71: 40-52.
- 8) Boehringer S, vander Lijn F, Liu F, Gunther M, Sinigerova S, Nowak. Genetic determination of human facial morphology: links between cleft-lips and normal variation. *Eur. J. Hum. Genet* 2011;19 : 1192-1197

- 9) Trotman C.A. Faces in 4 dimensions: Why do we care, and why the fourth dimension? *Am. J. Orthod. Dentofacial Orthop* . 2011; 140: 895-899.
- 10) Lee WL, Wilkinson CM, Hwang HS. An accuracy assessment of forensic computerized facial reconstruction employing cone-beam computed tomography from live subjects. *J Forensic Sci* 2012;57:318-27.
- 11) Seeberger R., Kane G., Hoffmann J. & Eggers G. 2012. Accuracy assessment for navigated maxillo-facial surgery using an electromagnetic tracking device. *J. Craniomaxillofac. Surg.*, 40: 156-161
- 12) Kašparová M, Procházka A, Grajciarová L, Yadollahi M, Vyšata O, Dostálová T. Evaluation of dental morphometrics during the orthodontic treatment. *Biomed Eng Online*. 2014 Jun 3;13:68.
- 13) Breno M, Leirs H, Dongen S. Traditional and geometric morphometrics for studying skull morphology during growth in *Mastomys natalensis* (Rodentia : Muridae). *Journal Of Mammology* 2011; 331.11395-1406
- 14) Muñoz A D, Soto G M. Skeletodental Diagnosis Using a Geometric Morphometric Approach . *Int. J. Odontostomatm* 2014; 8(1):5-11
- 15) Singh GD, Garcia-Motta AV, Hang WM. Evaluation of the posterior airway space following Biobloc therapy : geometric morphometrics. *Cranio* 2007 Apr; 25(2):84-9.
- 16) Chatzigianni A, Halazonetis DJ . Geometric morphometric evaluation of cervical vertebrae shape and its relationship to skeletal maturation. *Am J Orthod Dentofacial Orthop* 2009 Oct;136(4):481.e1-9