

Non-Surgical Non-Extraction Orthodontic Treatment Of An Adult With Facial Asymmetry

¹Raj kumar singh, ²Anil kumar Jangid, ³Sandhya Maheshwari, ⁴Sanjeev kumar Verma, ⁵Varun goyal, ⁶Gurkeerat singh

To cite: Raj kumar singh, Anil kumar Jangid, Sandhya Maheshwari, Sanjeev kumar Verma, Varun goyal, Gurkeerat singh - Non-Surgical Non-Extraction Orthodontic Treatment Of An Adult With Facial Asymmetry

2019;3(2): 39-43.

Received on:
12-03-2019

Accepted on:
19-06-2019

Source of Support: Nil

Conflict of Interest: None

¹Reader, Sudha Rustagi College of Dental Sciences and Research, Faridabad, Haryana

²Private practitioner, Ex Junior Resident , Z.A.D.C, A.M.U, Aligarh,

^{3,4}Professor, Z.A.D.C, A.M.U, Aligarh,

⁵Reader, Sudha Rustagi College of Dental Sciences and Research, Faridabad, Haryana

⁶Professor and Head, Sudha Rustagi College of Dental Sciences and Research, Faridabad, Haryana

ABSTRACT

An 18 year male patient presented with mandibular asymmetry with asymmetric mandibular and maxillary arches with midline shift and unilateral anterior crossbite. There were dental compensations in association with skewed mandibular arch. The patient was treated nonsurgically without any extractions and asymmetric orthodontic mechanics. Pretreatment and post treatment records are shown and the treatment strategy was discussed.

Key words: Asymmetry, Condylar hyperplasia, Crossbite.

INTRODUCTION

An ideal face is characterized by equal dimensions on one side compared to the structures on the opposite side.¹ Any difference in the size or shape of the sides of the face is termed as facial asymmetry. Asymmetry of the face and dentition is a natural phenomenon as even beautiful faces exhibits mild degrees of asymmetry. Severe form of asymmetry can cause both functional and esthetic impairment which require treatment necessary to correct asymmetry. Although the etiology of facial asymmetries and their mechanisms have not been completely understood², but it is well established that facial asymmetries often worsen with growth. The management of such asymmetry usually requires a combined surgical and orthodontic approach in adults.^{3,4,5}

Although these procedures improve both the esthetic and functional problems, but are associated with many disadvantages namely high medical costs, long surgeries, and severe postoperative discomfort for patients.⁶ Besides this all adult facial asymmetry patients do not benefit from surgical correction. Therefore patient assessment and selection remains a major issues in diagnosis and treatment planning. This case report presents the nonsurgical, nonextraction orthodontic treatment of a patient with laterognathia, facial asymmetry and dentofacial deformity. This article attempts to deal with essentials like the camera controls, equipment and accessories required for clinical photography, procedure for acquiring the right photographs, common errors and editing guidelines. 'Hot Tips' too are suggested to allow the best possible results to be consistently achieved.

DIAGNOSIS AND ETIOLOGY

An 18year male patient was referred to the department with the chief complaint of deviated chin and facial asymmetry which was consistently increasing since early childhood (Fig 1). There was no history of any trauma to the facial structures.

Extraoral examination revealed significant facial asymmetry with chin deviated to right and mandibular skeletal laterognathism to the right side. He had mesoprosopic face, concave profile, competent lips, canted smile line without any incisor visibility and midface growth deficiency; however there were no limitations of movements during jaw opening (Fig 2).

There was 5mm mandibular midline deviation to the right side in relation to facial midline. Maxillary arch was asymmetric with narrowing on left half and Mandibular arch with narrowing on right half. No discrepancy in centric occlusion and centric relation was evident There was crossbite on the right side extending from the right central incisor till the premolars. The molar and canine relationships were Class I on the right and Class III on the left side (Fig 3).

The cephalometric analysis (Table 1) presented a skeletal Class III pattern, with proclined maxillary anterior teeth. Dental compensations in the form of angulated (left side) mandibular anteriors were evident in panoramic radiograph along with enlarged left condylar neck (Fig 5). The pretreatment posteroanterior radiograph confirmed the skeletal mandibular asymmetry with deviation of the mandible to the right by 30° (Fig 10A).

The etiology of the patient's malocclusion was probably a

genetic predisposition that might have been complicated by environmental changes.

The mandibular arch was then banded and bonded. A few months later, .019 ×.025-in stainless steel wire was placed to

Measurement	Pretreatment	Post treatment
SNA (°)	85°	85°
SNB (°)	86°	85°
ANB (°)	-1°	0°
Upper incisor to NA (mm)	8 mm	8 mm
Upper incisor to NA (°)	35°	37°
Lower incisor to NB (mm)	6 mm	5 mm
Lower incisor to NB (°)	31°	26°
Interincisal angle (°)	113°	120°
GoGn: SN (°)	25°	27°
IMPA (°)	97°	94°
Mandibular rotation	30°	20°

Table 1: Cephalometric parameters

TREATMENT OBJECTIVES

The treatment objectives were to improve the asymmetric mandibular position, facial asymmetry, correct the associated dental malocclusion, eliminate the unilateral crossbite, and achieve a normal occlusion with ideal overbite and overjet.

TREATMENT ALTERNATIVES

To address the mandibular asymmetry and the underlying skeletal problem, the first option was a combination of orthognathic surgery and orthodontic treatment which would also take into account maxillary constriction and unilateral crossbite. The invasive procedure however was rejected by the patient. Other alternative treatment plan was extracting a single lower central incisor and using that space to achieve a positive overjet, but the patient was very apprehensive and did not want any of his tooth to be extracted. So based on the diagnostic data and according to the patient decision, nonextraction fixed mechanotherapy with preadjusted edgewise appliance was planned using asymmetric mechanics.

TREATMENT PROGRESS

First the maxillary arch was bonded with MBT preadjusted edgewise appliance using 022 inch slot. Levelling and alignment progressed starting with a .016-in nickel titanium wire up to working .019 × .025 in SS wire.

help establish arch form coordination. The maxillary and mandibular wires were adjusted by skewing them to 1 side to maintain adequate arch form. The maxillary wire was expanded and the mandibular constricted on the right side to correct the unilateral crossbite. When both the arches had heavy SS wire, a posterior bite plate was delivered and class III elastics were started, However the force used for class III elastics was asymmetric. On the right side light class III and on left heavy class III elastics were used.

After approx 2 years and 5 months of active treatment, upper and lower fixed appliances were removed. In the maxillary and mandibular arch, the patient was given Hawley's retainer and was instructed to wear it full-time for first year and then during night only.

TREATMENT RESULTS

After the completion of active treatment the post treatment records conclude that normal occlusion was achieved with optimal overbite and overjet (Figs 6 and 7). Crossbite was corrected which improved patient's smile esthetics. The dental midline deviation was largely improved, although the mandibular midline was slightly off to the right side. The cant in the smile line was reduced with good incisor visibility. The post-treatment cephalometric tracing showed an increase in ANB angle by 1°, an increase in mandibular plane angle and slight uprighting of the mandibular incisors as a consequence of class III elastics (Fig 9, Table1).The panoramic radiograph confirmed

the correction of the angulated mandibular incisors. The hard tissues were healthy with no evidence of root resorption

DISCUSSION

A condition in which both sides of the face are perfectly related and present same size, shape and position bilaterally, the face is said to be in a state of balance. On the contrary, an imbalance between the homologous parts of the dentofacial complex is termed as asymmetry.⁷ The facial skeletal asymmetry may be because of isolated mandibular asymmetries or maxillomandibular asymmetries. An excessive or deficient growth of the mandibular body and/or ramus results in mandibular asymmetries in which the mandible may be deviated from the midline i.e mandibular laterognathism. Although H. Peck⁸ and S. Peck⁹ in cases of mandibular skeletal asymmetry did not reveal significant differences on the side of mandibular deviation. A correlation of Class III malocclusion to skeletal asymmetries have been suggested by some authors concluding that 40% of such malocclusions are associated with some degree of facial asymmetry.¹⁰

The management of asymmetry is considered to be most challenging treatment in orthodontics. Usually surgery is the only option for the correction of severe facial skeletal asymmetries^{10,11}. However, mild or developing cases may require less invasive techniques¹². Based on patient's preference and treatment objectives it was decided to treat the case by non surgical and non extraction approach. Since the case was treated by non extraction approach, precise midline correction was not obtained. Kokich et al¹³ however concluded that a maxillary midline deviation as much as 4-mm was not detected by dentists or laypersons. Hence minor deviation in midline would most likely be unnoticed and acceptable in the present patient.

The fact that left condylar neck was elongated might suggest it to be a case of hemimandibular elongation as suggested by Obwegeser and Makek¹⁴ who classified asymmetries as either hemimandibular elongation or hemimandibular hyperplasia. There is elongation of either the condyle or the ramus in the vertical plane, or the mandibular body in the horizontal plane in case of Hemimandibular elongation, where as hemimandibular hyperplasia is characterized by enlargement of half of the entire mandible. Besides this, these two types of asymmetry also differ regarding growth cessation¹⁵, as the cases of hemimandibular hyperplasia tends to grow even after the cessation of active growth. It has been seen that patients with facial asymmetry are more prone towards morphological changes and internal derangement in the TMJ of the shifted side compared to the other side^{16,17}, hence the incidence of TMJ symptoms on the deviated side are higher

compared to the non-deviated side. However in the present case, no symptoms of TMJ disorder were observed either before or after the treatment.

The orthodontic management of a malocclusion with asymmetry requires asymmetric mechanics in the dental arches to achieve acceptable correction. However significant undesirable effects of asymmetric mechanics can occur if a detailed and precise force systems in three dimensions is not used. In the present case asymmetric mechanics in the form of light class III elastics on the right and heavy class III elastics on the left side were used without any detrimental effect.

CONCLUSION

Excellent results regarding improvement in esthetics and functions were achieved through non surgical and non extraction approach despite the fact that orthognathic surgery was indicated in the present case. Although some amount of mandibular deviation and dental midline shift to the right were still present, a perfect camouflage and compensation of class III malocclusion were achieved.

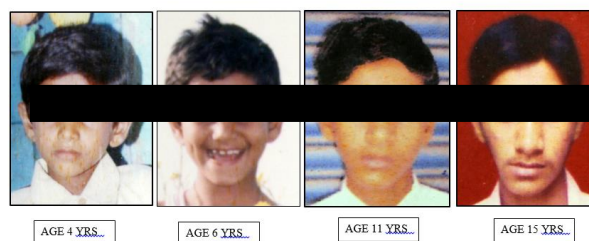

Fig.1 Progression of asymmetry at different ages




Fig.2 Pretreatment extra oral photographs

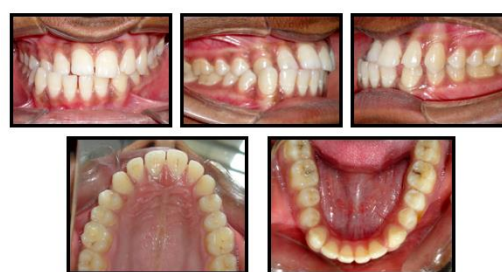

Fig.3 Pretreatment intra oral photographs

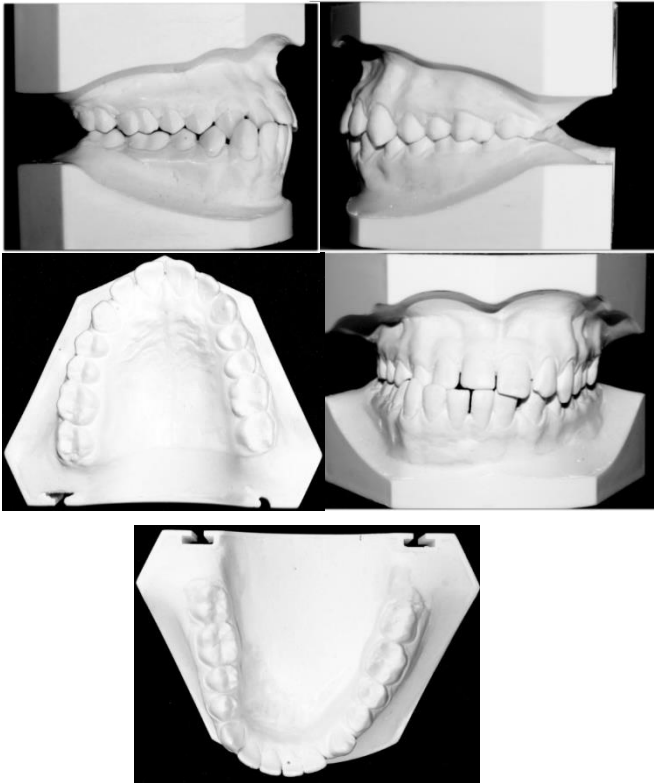


Fig. 4 Pretreatment dental casts

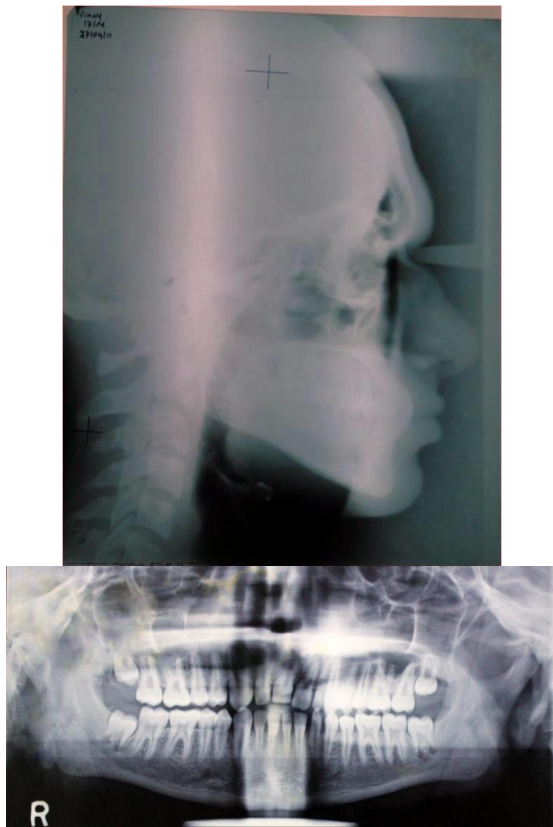


Fig 5 Pretreatment Radiographs (Lateral Ceph and OPG)

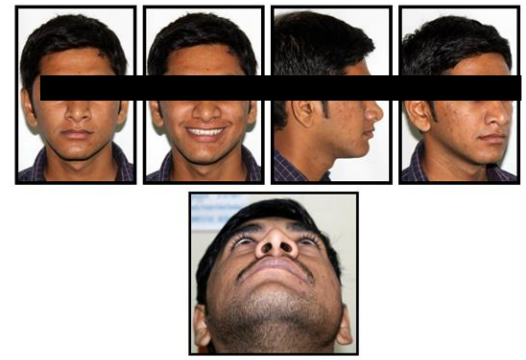


Fig. 6 Post treatment extra oral photographs

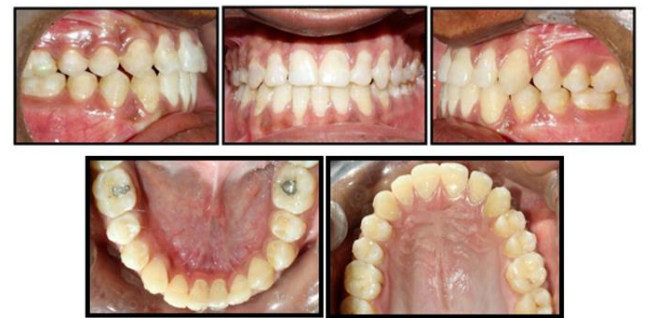

Fig.7 Post treatment intra oral photographs

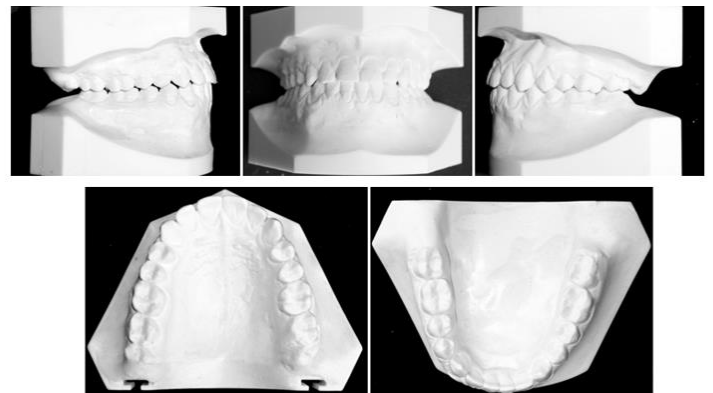

Fig.8 Posttreatment dental casts

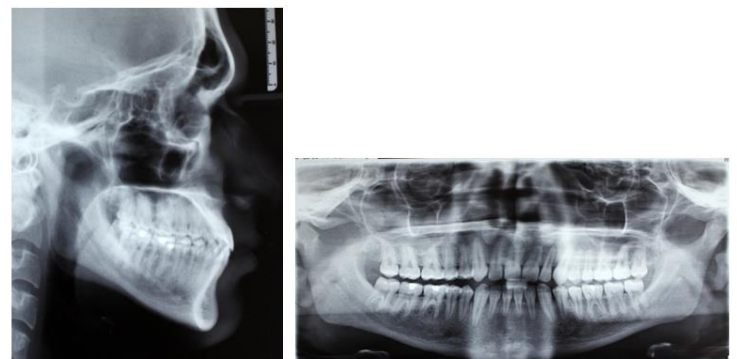

Fig. 9 Post treatment Radiographs (Lateral Ceph and OPG)

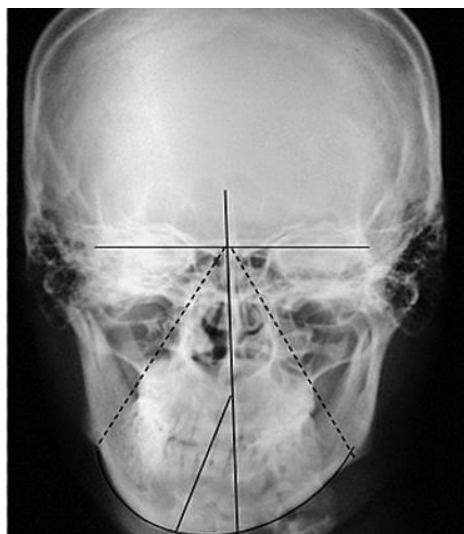


Fig 10A: Pretreatment P A Ceph

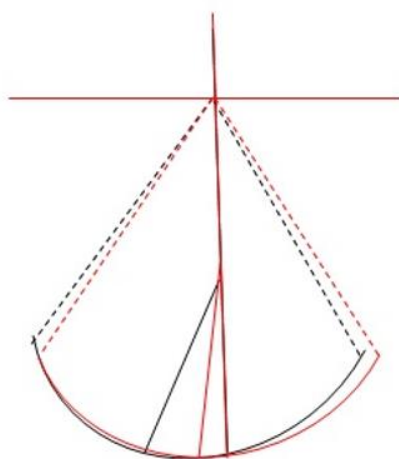


Fig 10B: Mandibular Rotation

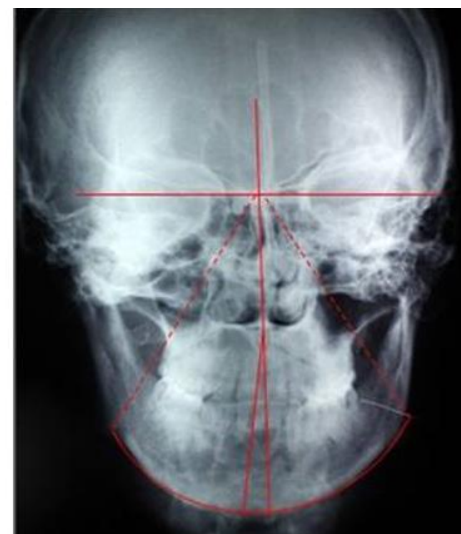

Fig 10C: Post treatment P A Ceph

Fig 10 Comparison of mandibular deviation before and after treatment

REFERENCES

1. Shah S, Joshi M. An assessment of asymmetry in the normal craniofacial complex. *Angle Orthod.* 1978; 48(2):141-8.
2. Haraguchi S, Takada K, Yasuda Y. Facial asymmetry in subjects with skeletal Class III deformity. *Angle Orthod.* 2002;72(1):28-35
3. Proffit WR, White RP, Sarver DM. Contemporary treatment of dentofacial deformity. 2003. Mosby; St Louis: p. 574-644.
4. Guyuron B. Combined maxillary and mandibular osteotomies. *Clin Plast Surg* 1989;16:795-801
5. Miyatake E, Miyawaki S, Morishige Y, Nishiyama A, Sasaki A, Takano-Yamamoto T. Class III malocclusion with severe facial asymmetry, unilateral posterior crossbite, and temporomandibular disorders. *Am J Orthod Dentofacial Orthop* 2003;124:435-45.
6. Panula K, Keski-Nisula L, Keski-Nisula K, Oikarinen K, Keski-Nisula S. Costs of surgical-orthodontic treatment in community hospital care: an analysis of the different phases of treatment. *Int J Adult Orthod Orthognath Surg* 2002;17:297-306.
7. Fischer B. Asymmetries of the dentofacial complex. *Angle Orthod.* 1954;24(4):179-92.
8. Peck H, Peck S. A concept of facial esthetics. *Angle Orthod.* 1970;40(4):284-318.
9. Peck S, Peck L, Kataja M. Skeletal asymmetry in esthetically pleasing faces. *Angle Orthod.* 1991;61(1):43-8.
10. Jerrold L, Lowenstein J. The midline: diagnosis and treatment. *Am J Orthod Dentofacial Orthop* 1990;97:453-62
11. Barker JH, Brown T, David DJ, Nugent MA. The treatment of facial disharmony and malocclusion by jaw surgery. Case reports. *Aust Dent J* 1991;36:183-205
12. Patrick S Anhoury. Nonsurgical treatment of an adult with mandibular asymmetry and unilateral posterior crossbite. *Am J Orthod Dentofacial Orthop* 2009;135:118-26
13. Kokich VO, Kiyak HA, Shapiro PA. Comparing the perception of dentists and lay people to altered dental esthetics. *J Esthet Dent* 1999;11:311-24.
14. Obwegeser HL, Makek MS. Hemimandibular hyperplasia—hemimandibular elongation. *J Maxillofac Surg* 1986;14:183-208.
15. Joondeph DR. Mysteries of asymmetries. *Am J Orthod Dentofacial Orthop* 2000;117:577-9
16. O'Byrn BL, Sadowsky C, Schneider B, BeGole EA. An evaluation of mandibular asymmetry in adults with unilateral posterior crossbite. *Am J Orthod Dentofacial Orthop* 1995;107:394-400.
17. Cohlmiä JT, Ghosh J, Sinha PK, Nanda RS, Currier GF. Tomographic assessment of temporomandibular joints in patients with malocclusion. *Angle Orthod* 1996;66:27-36.