

Orthodontic treatment of vertical maxillary excess in an adult patient using a single palatal miniscrew implant: A case report

Ekta Lahoti^a, Partha Pratim Choudhury^b, Ali Asger Nakib^c, Anuranjan Das^d

Gummy smile along with a hyperdivergent profile is one of the most complex malocclusions in clinical orthodontics. It is often characterized by excessive maxillary posterior dentoalveolar height along with excessive anterior dentoalveolar height. Such situation in an adult patient often demands surgical therapy. However, patient reluctance towards surgery and alternative method using miniscrews is now frequently used in such cases. In case report, orthodontic treatment of a 25year old male patient with skeletal class II malocclusion, gummy smile and hyperdivergent profile has been described. For the correction of gummy smile and facial profile, we decided for full maxillary arch intrusion using a single palatal miniscrew implant along with a modified transpalatal arch. The active treatment phase lasted 24 months.

Keywords: Gummy smile; Miniscrew; Facial profile; Adult patient

Introduction:

The use of a single vitallium bone screw just below the anterior nasal spine to intrude maxillary incisors without any complications from the screw was reported by Creekmore and Eklund¹ in 1983. In recent times, mini-implants have been used for multiple purposes- for correction of gummy smile with increased anterior facial height by full maxillary arch intrusion; deepbite correction by intrusion of incisors; open bite correction by molar intrusion.^(2,3,4,5) In 2003, Paik et al² treated vertical maxillary excess by single palatal implant and modified transpalatal arch. In 2006, Kim et al³ used mini-implant with segmented wires to achieve intrusion. Gummy smile poses an esthetic problem and requires proper diagnosis and treatment planning. Gummy smile along with a hyperdivergent profile is often characterized by excessive maxillary posterior dentoalveolar height along with excessive anterior dentoalveolar height. In such a situation, often surgical therapy like a Le Fort impaction is needed to improve esthetics. However, patient reluctance towards surgery and alternative method using miniscrews is now frequently used in such cases. This case report describes orthodontic treatment of a 25year old male patient with skeletal class II malocclusion, gummy smile and hyperdivergent profile in whom gummy smile correction was achieved by intrusion of entire maxillary dentition using a single palatal miniscrew implant and a modified transpalatal arch.

Case Report:

A 25 years old male patient presented with skeletal class II malocclusion and gummy smile. Molars showed class I relation with the lower second premolars partially erupted lingually. Overjet was 10 mm and overbite was 1mm. There was 12 mm and 10 mm of arch length deficiencies in maxillary and mandibular arches respectively. He also had short upper lip, lip trap and mentalis strain on closing.(Fig.1)

Cephalometric evaluation revealed a retrusive mandible, large upper anterior dentoalveolar height (U1-NF) and large upper posterior dentoalveolar height (U6-NF) and a large mandibular plane angle associated with increased anterior facial height. The upper and lower incisors both are flared(Fig.2 and Table 1).

Treatment objectives

Our treatment objectives included improving the patient's smile esthetics and facial profile along with a harmonious occlusion. This included:

- creating a normal overbite and overjet relationship
- reducing his excessive gingival display
- reducing the vertical dimension to improve facial balance

Treatment alternatives

The patient showed excessive gingival display in both the anterior and posterior regions. Overbite was zero. Therefore, for the correction of gummy smile, we decided to intrude full maxillary dentition and not just the anterior teeth. Two treatment options were given to the patient:

1. Conventional orthodontic treatment with extraction of upper and lower premolars combined with orthognathic surgery(Le fort I maxillary impaction).
2. Extraction of upper first and lower second premolars followed by orthodontic intrusion of complete maxillary dentition using miniscrew implants.

On weighing the risks and benefits of the both the alternatives, the patient chose the more conservative second option. A single palatal miniscrew and a modified transpalatal arch were then used for intrusion of entire maxillary arch.

Treatment progress

Upper first premolars and lower second premolars were extracted. A preadjusted fixed appliance 0.022 × 0.028 inch slot (MBT prescription) was bonded to the maxillary and mandibular arches. Conventional alignment and leveling were performed in upper and lower arches. A miniscrew implant (diameter 1.5 mm, length 8mm) was placed in posterior midpalatal area under local

^a Consultnt orthodontist, Kolkata.

^b Clinical Tutor, Dept. of Orthodontics, North Bengal Dental College and Hospital, Darjeeling, West Bengal.

^c Clinical Tutor, Dept. of Orthodontics, Dr. R. Ahmed Dental College and Hospital, Kolkata, West Bengal.

^d Principal, Head and PG guide, Dept. of Orthodontics, Mithila Minority Dental College and Hospital, Dwarbhanga, Bihar.

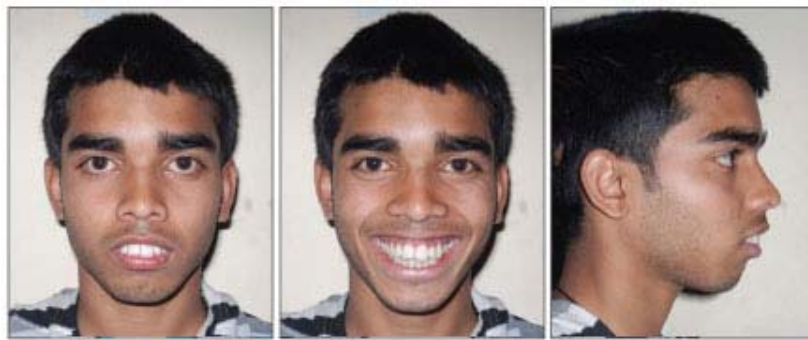

Fig 1. Pre-treatment facial photographs

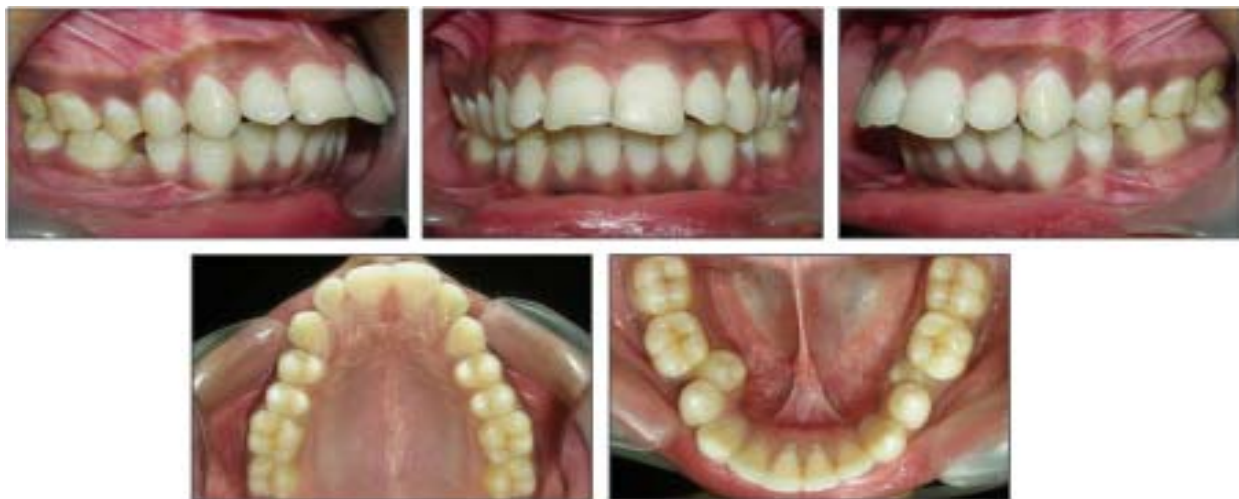

Fig 2. Pre-treatment intraoral photographs

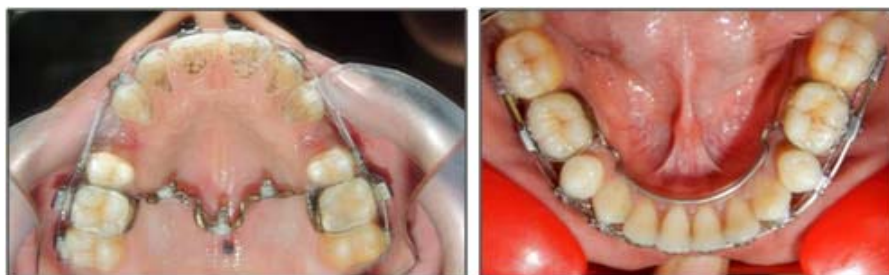

Fig. 3- Soldered transpalatal arch attached to miniscrew by closed coil spring and soldered lingual arch

infiltration anesthesia, anteroposteriorly at the level between first and second molars. A transpalatal arch was fabricated with 1mm stainless steel wire such that it stayed approximately 5mm from palatal mucosa. Three hooks were soldered to it for application of intrusive force on maxillary dentition. A lingual arch was soldered to lower first molars (Fig. 3). After 6 months of treatment, .019/.025 stainless steel working archwires could be engaged in both arches. Closed coil spring (11mm) was attached to hooks on either side and attached in the centre to palatal implant by ligature tie. The maxillary incisors were also simultaneously intruded by incorporation of curve of spee in upper archwire. This produced intrusion of entire maxillary dentition. The intrusion took approximately 12 months, after which the coil spring and hooks were removed and transpalatal arch was tied to implant by ligature tie (Fig. 4). In this way, the mandible autorotated counterclockwise upward and forward resulting in reduction in anterior facial height and slight advancement of chin. Following mandibular autorotation, anterior bite deepened and necessitated incorporation of reverse curve in lower

archwire to achieve proper overbite. The orthodontic treatment took about 24 months. Fixed lingual retainers were then bonded in both arches.

Treatment results

The patient's smile esthetics and facial balance were improved at the end of treatment and lower anterior facial height reduced by 2 mm. The lips and chin appeared more esthetic (Fig. 5). Mandibular plane angle decreased by 1 degree (Table 1). Overall superimposition of cephalometric tracings showed superior movement of the maxillary dentition and posterosuperior movement of upper incisors with little skeletal change and mandibular counterclockwise rotation. Lower molar showed minimal vertical and anteroposterior change (Fig. 9).

The post treatment panoramic radiograph showed overall parallelism of roots. No significant root resorption was noted (Fig. 7)

Table 1. Cephalometric data

Measurement	Pre-treatment	Post-treatment
Anteroposterior Skeletal		
SNA(deg)	90	86
SNB(deg)	79	79
ANB(deg)	11	7
Vertical Skeletal		
GoMe-FHP(deg)	36	35
FMA(deg)	35	34
ANS-Me(mm)	72	70
Dental		
Overjet(mm)	10	2
Overbite(mm)	1	2
U1/SN(deg)	124	103
IMPA(deg)	100	96
U1-NF(mm)	31	30
U6-NF(mm)	27	25.5
L1-MP(mm)	43	41
L6-MP(mm)	33	33
Soft tissue		
U lip-E line(mm)	+3	0
L lip-E line(mm)	+6	+4

U1-NF=Upper anterior dentoalveolar height; L1-MP= Lower anterior dentoalveolar height; U6-NF= Upper posterior dentoalveolar height; L6-MP= Lower posterior dentoalveolar height.

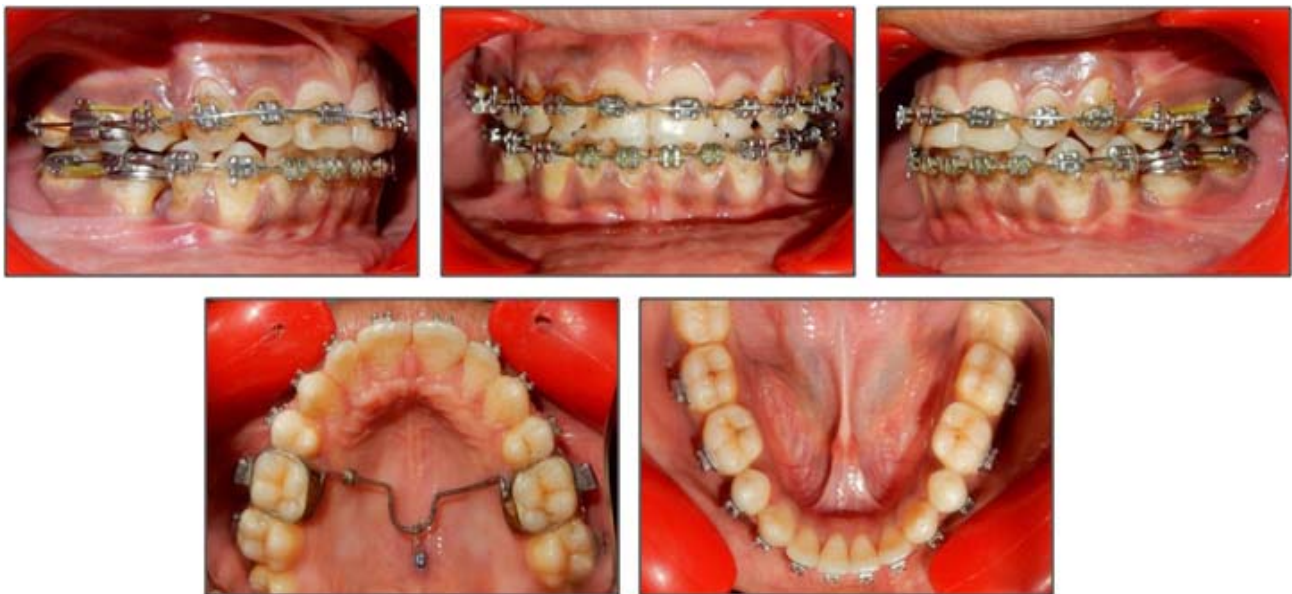

Fig. 4- Treatment progress intraoral photographs

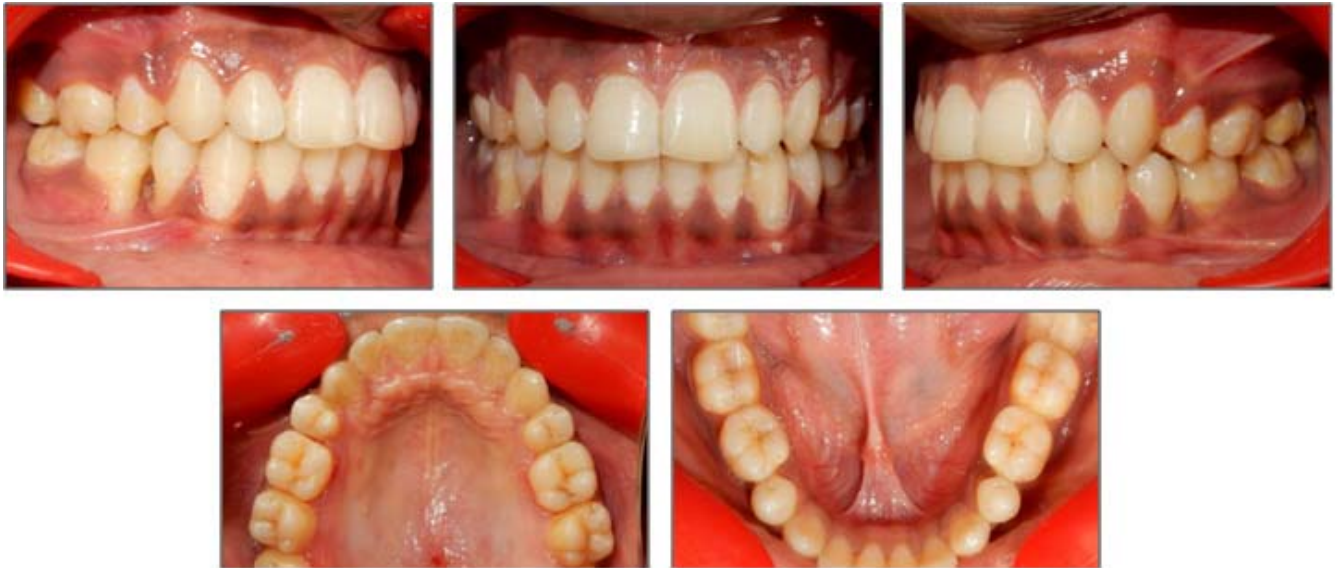

Fig 6. Post-treatment intraoral photographs

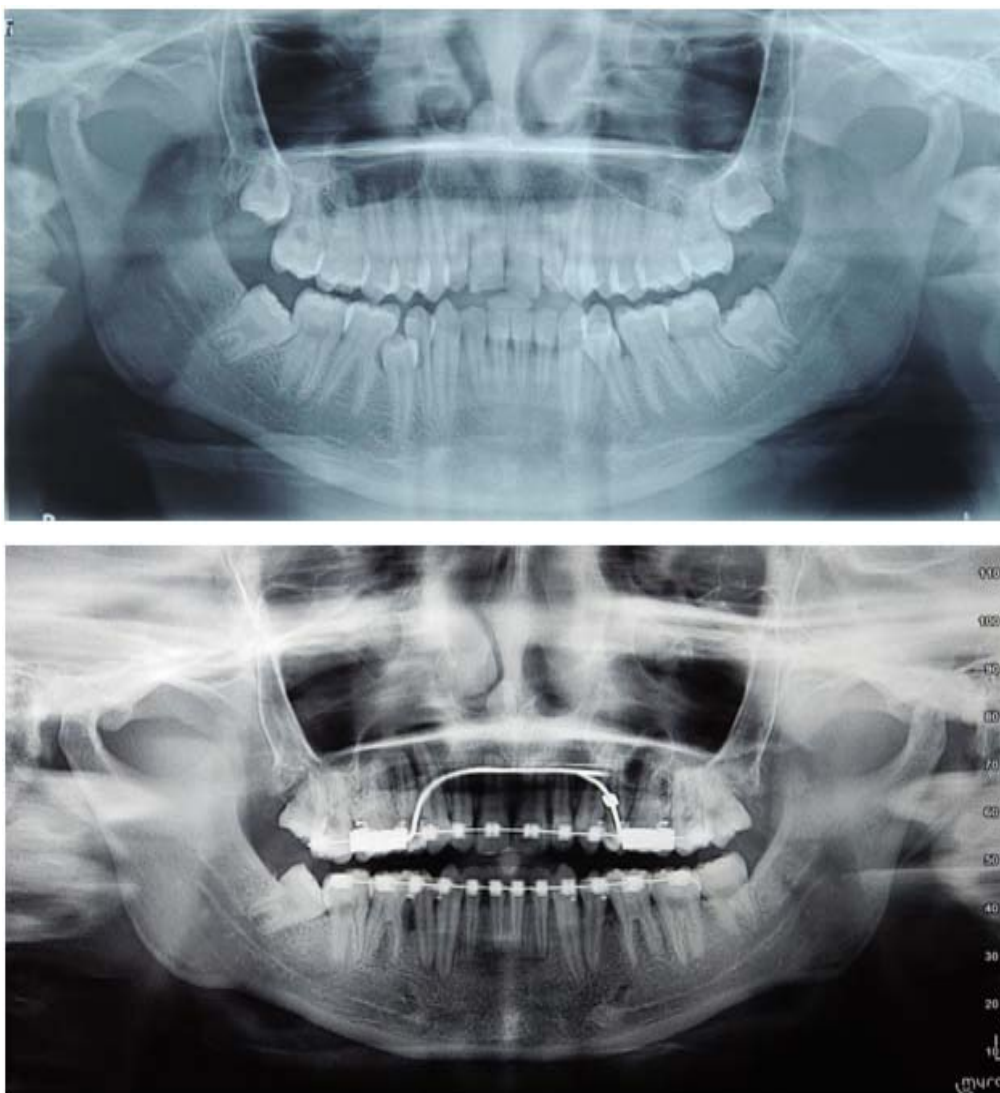


Fig. 7. Pre and post treatment panoramic radiographs

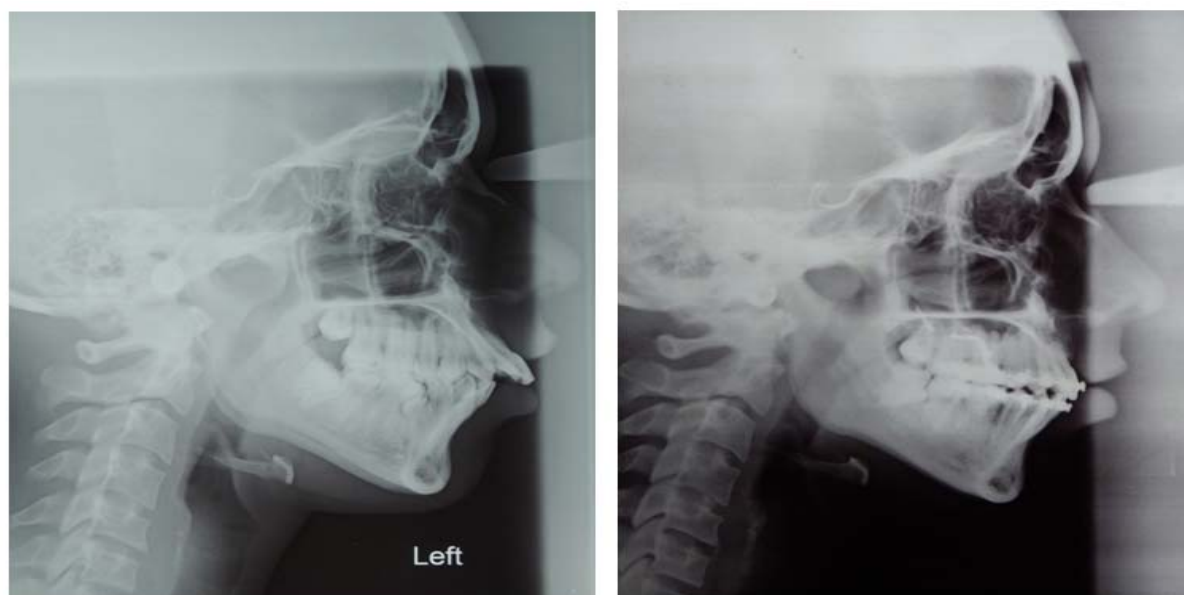

Fig. 8. Pre and post treatment lateral cephalograms.

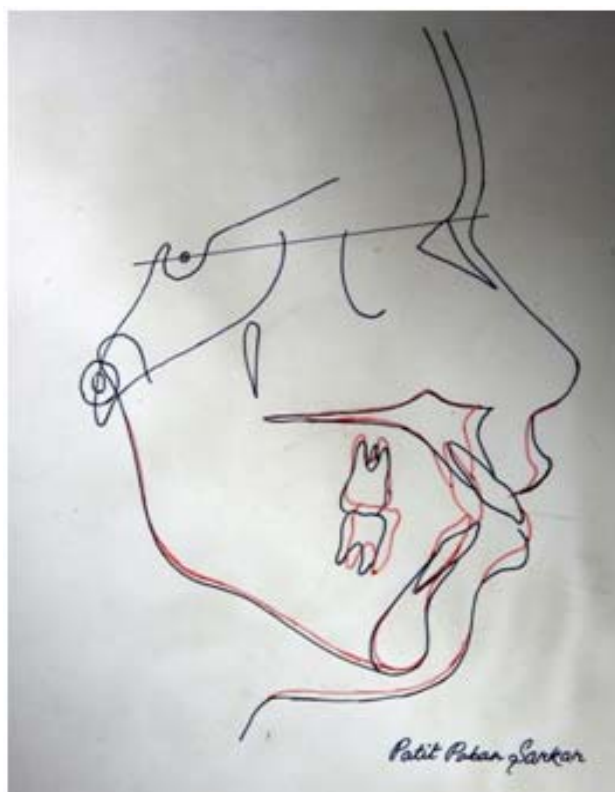


Fig. 9- Superimposition of pre and post treatment cephalometric tracings, showing upper molar intrusion, autorotation of mandible and decrease in lower anterior facial height.

Discussion

There are many reasons for a gummy smile like vertical maxillary excess, excessive gingival overgrowth, altered passive eruption, anatomically short upper lip, hypermobile muscles of the upper lip, or a combination of any of these factors⁶⁻⁸. Many times, orthognathic surgery is required for correction. In this patient, the gummy smile seemed to be a result of short upper lip and vertical maxillary excess.

The use of screw mechanics for achieving the effect of a Le Fort I impaction of the maxilla was proposed by Lin et al⁴ in which multiple screws were used: two miniscrews (diameter 2 mm and length 7 mm) were placed between the roots of the upper second premolars and first molars. Two hook screws (diameter 1.5 mm and length 9 mm) were inserted in buccal alveolar bone between the upper first and second molars on both sides and two hook screws (diameter 2 mm and length 7 mm) were placed in the palatal area 2 mm lateral to midpalatal suture along a line between first and second molars.

Studies with posterior bite block therapy for molar intrusion with repelling magnets⁹⁻¹¹ or without repelling magnets¹² have demonstrated satisfying results with respect to reduction in lower anterior facial height. However, patient compliance is poor with such appliances and temporomandibular joint problems have been reported with the use of repelling magnets. In this case report, single palatal implant has solved the problem of patient compliance and has satisfactorily accomplished intrusion of the entire upper dentition. This procedure has been termed by Paik et al² as “slow impaction” of maxilla as it mimics the effects produced by Le fort I maxillary osteotomies.

In the lower arch, a lingual arch was soldered to molar bands to prevent over-eruption of mandibular molars as the mandible autorotated counterclockwise following maxillary impaction. Following mandibular autorotation, anterior bite somewhat deepened. To counter this, reverse curve was added in lower arch wire to achieve lower incisor intrusion.

The midpalatal area provides adequate retention for miniscrew implants due to good bone quality. Placement of miniscrew in posterior midpalatal area also reduces risk of damaging anatomical structures like nerves, blood vessels or tooth roots. The soft tissue thickness is also very less in this region. Thus, chances of implant failure in posterior palate are also less as compared to placement in more cancellous buccal bone in maxilla. We placed an implant of 1.5 mm diameter and 8mm length in posterior midpalatal area under local infiltration anesthesia, anteroposteriorly at the level between first and second molars. Unlike subperiosteal implants¹³⁻¹⁴, miniscrews are more cost effective and allow immediate loading¹⁵.

Force values for posterior teeth intrusion are not very clearly defined. Chun et al¹⁶ applied 50g of force to intrude single over-erupted molar. Kalra et al¹⁰ applied 90g of force while Melsen¹⁷ applied 25-50g of force to intrude posterior teeth. We applied about 150g of force per side (as measured by dontrix gauge). So, a total of approximately 300g of force acted on the midpalatal screw. The miniscrew remained stable throughout treatment.

Stability following posterior intrusion and reduction of vertical dimension in adults has long been a topic of utmost concern. The vertical effect on posterior teeth following intrusion can be maintained by isometric clenching exercises. Chewing gum exercise has been suggested to increase the contraction forces of elevator muscles of mandible and maintain the correction achieved. Isometric clenching on soft bite plate for 30 minutes per day over 8 weeks. Alternately, two 15mins sessions per day can be done (3secs clenching with 5 secs rest in between) or chewing gum exercise of 30 minutes per day over 4 weeks can be recommended. At the end of this, total occlusal force was found to be increased by 140% and contact area by 125%¹⁸⁻¹⁹. We recommended isometric clenching exercise to this patient.

The extraction of partially erupted lower right second premolar as a part of orthodontic treatment created a bony defect on the mesial aspect of lower right first molar due to faulty surgical extraction technique(Fig.4).Periodontal consultation had been taken and the necessary periodontal reconstruction procedures need to be commenced following removal of braces.

Conclusion

Miniscrews can correct gummy smiles by total intrusion of the maxillary arch and can augment anchorage. The use of single palatal implant has several advantages- they are minimally invasive treatment modality, reduced number of screw implants are needed, mid palate is one of the best and safest sites for implant placement and can withstand considerable orthodontic forces.

REFERENCES

1. Creekmore TD, Eklund MK. The possibility of skeletal anchorage. *J Clin Orthod* 1983;17:266-9.
2. Paik CH, Woo YJ, Boyd R. Treatment of an adult patient with vertical maxillary excess using miniscrew fixation. *J Clin Orthod*.2003;37:423-428.
3. Kim TW, Kim H, Lee SJ. Correction of deep overbite and gummy smile by using a mini-implant with a segmented wire in a growing Class II Division 2 patient. *Am J Orthod Dentofacial Orthop* 2006; 130:676-85.
4. Lin JC, Liou EJ, Bowman SJ. Simultaneous reduction in vertical dimension and gummy smile using miniscrew anchorage. *J Clin Orthod* 2010;44:157- 70.
5. Mohammad R. Razavi, Molar intrusion using Miniscrew Palatal Anchorage. . *J Clin Orthod* August 2012;8:493-498.
6. Robbins JW. Differential diagnosis and treatment of excess gingival display. *Pract Periodontics Aesthet Dent* 1999;11:265-72.
7. Burstone CR. Deep overbite correction by intrusion. *Am J Orthod* 1977;72:1-22.
8. Redlich M, Mazor Z, Brezniak N. Severe high Angle Class II Division 1 malocclusion with vertical maxillary excess and gummy smile: a case report. *Am J Orthod Dentofacial Orthop* 1999;116:317-20
9. Dellinger, E.L. : A clinical assessment of the active vertical corrector : A nonsurgical alternative for skeletal open-bite, *Am. J. Orthod.* 89:428-436, 1986.
10. Kalra, V. ; Burstone, C.J. ; and Nanda, R. : Effects of a fixed magnetic appliance on the dentofacial complex, *Am. J. Orthod.* 95:467-478, 1989.
11. Barbre, R.E. and Sinclair, P.M. : A cephalometric evaluation of anterior open-bite correction with the magnetic active vertical corrector, *Angle Orthod.* 61:93-109, 1991.
12. Iscan, H.N. ; Akkaya, S. ; and Koralp, E. : The effects of the spring-loaded posterior bite-block on the maxillo-facial morphology, *Eur. J. Orthod.* 14:54-60, 1992.
13. Triaca, A. ; Antonini, M. ; and Wintermantel, E. : Ein neues Titan-Flachschaublen-Implantat zur orthodontischen Verankerung am anterioren Gaumen, *Inf. Orthod. Kieferorthop.* 2:251-255, 1992.
14. Block MS, Hoffman DR. A new device for absolute anchorage for orthodontics. *Am J Orthod Dentofacial Orthop* 1995;107:251-8.
15. Costa A, Raffaini M, Melsen B. Miniscrews as orthodontic anchorage: a preliminary report. *Int J Adult Orthod Orthognath Surg.* 1998;13:201-209.
16. Chun, Y.S. ; Woo, Y.J. ; Row, J. ; and Jung, E.J. : Maxillary molar intrusion with the molar intrusion arch, *J. Clin. Orthod.* 34:90-93, 2000.
17. Melsen, B. and Fiorelli, G. : Upper molar intrusion, *J. Clin. Orthod.* 30:91-96, 1996.
18. Uchida M, Yamaguchi K, Nagano S, Ichida T: Daily clenching exercise enhances the occlusal contact, *Orthod Waves* 64:29-37, 2005.
19. Masumoto N, Yamaguchi K, Fujimoto S: Is chewing exercise improving occlusal contact? Questionnaire on manner of food taking. Presented at 66th Congress of Japanese Orthodontic Society, 2007.