



Review Article

White spot lesions in clear aligner therapy as compared with multi-bracket system: A Systematic Review

Deepak Singh¹, Vipul K Sharma^{2*}, Roopal Srivastava³, Pooja Priyadarshani², T P Chaturvedi²

¹Dept. of Orthodontics and Dentofacial Orthopaedics, Maulana Azad institute of Dental Sciences, New Delhi, India

²Dept. of Orthodontics and Dentofacial Orthopaedics, Institute Of Medical Sciences (BHU), Varanasi, Uttar Pradesh, India

³Dept. of Prosthodontics, Institute of Medical Sciences (BHU), Varanasi, Uttar Pradesh, India



ARTICLE INFO

Article history:

Received 08-08-2023

Accepted 12-09-2023

Available online 03-10-2023

Keywords:

Clear aligners

white spot lesions

fixed orthodontics

enamel demineralization

ABSTRACT

Aim and Objective: To evaluate incidence of white spot lesions in clear aligner treatment compared with fixed appliance therapy.

Materials and Methods : Electronic databases (PubMed, Cochrane Collaboration Oral Health group database of clinical trials, Web of Science, Science Direct, Scopus) and manual search of gray literature were conducted up to September 2021. Both randomized and non-randomized controlled studies were considered for review purposes. Study selection, data extraction, quality assessment (RoB 2.0 and ROBINS-I) was performed according to the Cochrane Handbook for Systematic Reviews of Intervention. Due to the presence of high heterogeneity only qualitative analysis has been done.

Results: Out of 479 retrieved literature, 3 studies fulfilled the eligibility criteria and were included in the analysis. Studies were evaluated at low to high risk of bias. On qualitative analysis, a total of 160 new white spot lesions were developed in the clear aligner group and 362 new lesions were found in the fixed orthodontic group ($P < 0.001$). In addition, the surface area of white spot lesion in the clear aligner group was more than the fixed appliance group but the deepest lesion was still found in the fixed appliance group.

Conclusion: Incidence and severity of white spot lesion was found more in the fixed appliance group as compared to the clear aligner group. However, more low risk of bias studies with proper methodological quality is required to reinforce the conclusive evidence.

This is an Open Access (OA) journal, and articles are distributed under the terms of the [Creative Commons Attribution-NonCommercial 4.0 International](https://creativecommons.org/licenses/by-nc/4.0/), which allows others to remix, and build upon the work non-commercially, as long as appropriate credit is given and the new creations are licensed under the identical terms.

For reprints contact: reprint@ipinnovative.com

1. Introduction

Orthodontic treatment has the ability to move the teeth precisely and in a planned manner in all three planes of space within the alveolar bone. Simultaneously, it adversely affects the surrounding structure like clinical attachment loss, subgingival microbial changes, root resorption, enamel demineralization, and discoloration.^{1,2} Among these adverse effects of orthodontic treatment, enamel subsurface demineralization or white spot lesions

(WSLs) are commonly seen in orthodontic patients with a 45.8% of incidence rate and 68.4% of prevalence.^{3,4} Majority of WSLs are associated with the gingival area of upper lateral incisors, lower canines, and premolars.⁵ Younger patients have more chances to develop the lesion during orthodontic treatment as compared with adults.⁶ Self-cleansing mechanisms of oral cavity impeded by multibracket system of orthodontic therapy result in accumulation of plaque and lowering of PH, that ultimately leads to enamel demineralization.^{7,8} Increased incidence of enamel demineralization in fixed orthodontics is already proven with various studies.^{9–11}

* Corresponding author.

E-mail address: vipulk.sharma1@bhu.ac.in (V. K. Sharma).

Clear aligner (CA) therapy is one of the recent advances in orthodontics and becoming popular with time due to the increase in the number of young and adult patients looking for a more aesthetic and comfortable alternative to fixed appliances (FAs). The effectiveness of CA therapy is already proven with different studies and systematic reviews.^{6,12,13} Recent studies claim that the incidence of WSLs is decreased in aligner therapy.¹⁴ Purpose of this systematic review was to assess the enamel demineralization in clear aligner treatment compared with conventional multibracket system. The null hypothesis was assumed that there is no difference regarding incidence and characteristics of enamel demineralization between fixed multibracket system and clear aligner therapy.

2. Materials and Methods

2.1. Protocol and registration

Preferred Reporting Items for Systematic Review and Meta-Analyses (PRISMA) guidelines (<http://www.prisma-statement.org/>)¹⁵ and the Cochrane Handbook for Systematic Reviews of Intervention (<https://www.cochrane-handbook.org/>)¹⁶ were used for conduction and reporting and analysis. Systematic review was registered in PROSPERO and the registration number was CRD42021261169.

2.2. Eligibility criteria

Eligibility criteria of analysis has been set according to the PICOS format described as:

2.3. Participants

Mild to moderate class I malocclusion (<5 mm of crowding) with non-extraction treatment plan.

2.4. Intervention

Clear aligner therapy was used as an orthodontic treatment modality.

2.5. Comparison

Fixed orthodontic treatment was performed in mild class I malocclusion (crowding < 5mm, with non-extraction treatment plan) as a control group.

2.6. Outcome

The incidence rate of WSLs, depth of enamel demineralization, and surface area of developed lesions.

2.7. Study design

Randomized controlled clinical trials, prospective studies, and in-vivo studies were included.

2.8. Exclusion criteria

Subjects who have not undergone any orthodontic therapy, patients with severe malocclusion and skeletal discrepancies, patients with craniofacial syndromes, malocclusion treated with myofunctional and orthopedic appliances, patients underwent either CA therapy or FA therapy who have compared WSLs before and after the treatment, Retrospective studies, case series, case reports, literature reviews, in-vitro studies, observational studies, authors' opinion, letters to the editor, and engineering articles were excluded. Focused question of the study was "Do clear aligner therapy show a lesser incidence rate of WSLs compared to fixed orthodontic treatment?"

3. Search Methodology

A comprehensive search was done from January 2020 to September 2021 with no publication year limits by two independent reviewers (VS and DS). Following electronic databases were searched for published studies- PubMed (<https://pubmed.ncbi.nlm.nih.gov/>), Cochrane Collaboration Oral Health group database of clinical trials (<https://www.cochrane.org/>), Web of Science (<https://mjl.clarivate.com/search-results>), Science Direct (<https://www.sciencedirect.com/>), Scopus (<http://www.scopus.com/>). In addition to this, a manual search of the references mentioned in the included studies and grey literature was done.

In-vivo randomized controlled clinical trials and prospective studies were included in this study to check and compare the incidence rate of newly developed WSLs in patients who underwent orthodontic treatment with either CA compared with FA therapy.

Following keywords were used during literature search
 1. White spot lesions
 2. Clear aligners
 3. Traditional braces
 4. Fixed orthodontic treatment
 5. Enamel demineralization
 6. Initial carious lesions
 7. Subsurface demineralization
 8. Invisalign.

Boolean operators OR and were used in combination with these keywords to search published studies.

Combinations of keywords were used in electronic databases during literature search were "Clear aligners AND White spot lesions", "Clear aligners AND Enamel demineralization", "Clear aligners AND White spot lesions OR Enamel demineralization", "Clear aligners AND Traditional braces AND White spot lesions", "Invisalign AND White spot lesion AND Traditional braces", "Fixed orthodontic treatment OR Invisalign AND White spot lesions" and "Fixed orthodontic treatment AND Subsurface demineralization OR Initial carious lesions".

3.1. Data collection

The data were extracted by two independent reviewers (PP and TP) from all the included studies and filled them into predetermined forms. From each study, following data were

obtained – study design, publication year, country, sample size, sample gender, sample age, intervention, follow-up period, analysis, and outcomes.

3.2. Data analysis

Studies will be considered for meta-analysis, if presented with sufficient homogenous data otherwise qualitative analysis would have been undertaken. Incidence of white spot lesion after both the treatment procedures was planned to be assessed by the software review manager 5.03 (RevMan, Nordic Cochrane Centre, Copenhagen, Denmark). Bivariate differential mean statistic was planned for an intergroup estimate with 95% confidence interval to measure outcome mean. Random effect model with Cochran–Mantel–Haenszel statistics¹⁷ was used. To identify study heterogeneity I^2 test statistics were applied and P value <0.05 was considered significant statistically.

3.3. Risk of bias and quality of evidence assessment

Two independent reviewers (DS and RS) assessed the bias of the included studies and any disagreements were solved by discussion. The risk of bias of the included randomized clinical controlled trials was evaluated using the Cochrane risk of bias assessment tool and a plot was generated using Rob 2.0 Cluster (<https://www.riskofbias.info/welcom/e/rob-2-0-tool>).¹⁸ The traffic signal plot consisted of five domains (D1 to D5) indicating selection, detection, attrition, reporting, and other bias. ROBINS-1 (<https://www.riskofbias.info/welcome/home/current-version-of-robins-1>)¹⁹ was used for risk of bias assessment of the included non-randomized prospective study assessed by seven different domains. Overall bias and bias of each domain was decided to be low (low for all key domains), moderate (moderate risk in at least one domain), serious (serious risk in at least one domain), critical (critical risk in at least one domain) or no information. Along with this, GRADE tool (<https://www.gradepro.org/>) was also used to evaluate the quality of evidence for all the included studies.

4. Results Study selection

The literature search yielded a total of 479 studies through search in electronic databases (PubMed- 218, Cochrane central- 145, ScienceDirect- 51, Web of Science- 65). Among all the studies, 130 duplicate records were removed. 345 studies were removed after screening title and abstracts. Table 4 studies were included for full-text reading; one study was excluded due to other reasons.^{14,20–22} Among three studies, two randomized controlled clinical trials and one prospective study were included for qualitative and quantitative analysis.^{20–22} The study selection procedure was done by two independent reviewers (VS and DS) and any disagreements between the reviewers were solved by discussion. The study selection procedure has been shown

in Figure 1 a.

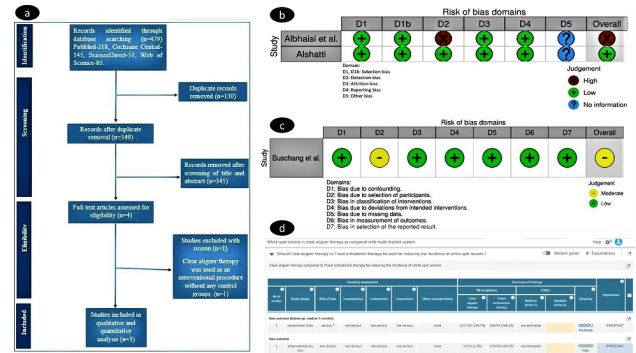


Figure 1: a) PRISMA flow diagram shows selection process of eligible studies; b) Traffic signal plot of assessment of RCCT with the Cochrane risk of bias tool; c) Traffic signal plot of risk of bias assessment in prospective study; d) GRADE tool for the assessment of quality of evidence.

4.1. Characteristics of the included studies

Characteristics of the included studies are presented in Tables 1 and 2.

Total three included studies in this systematic review were conducted in three different regions (Jordan, Texas, Connecticut) and published in between 2017 to 2021.^{20–22} Total 551 patients who were treated with either clear aligner therapy or fixed orthodontic appliances were identified. The clear aligner group was comprised of 287 patients whereas 264 patients were present in the fixed orthodontic group. In addition, included age group was found 17 years to a maximum age of 44.4 years. Moreover, gender description was provided only in one study, and the minimum follow-up period was assessed immediately after treatment completion to a maximum of 18-month post-treatment.²⁰ QLF and Digital photographs were used as the method of recording the WSLs.^{21,22} Furthermore, all the studies have mentioned the method of prior sample calculation, considered inspecting the accuracy measurement, and compared baseline data.

5. Results of Individual Studies and Qualitative Synthesis

I^2 value was calculated 98% in this analysis and the Chi^2 value was greater than the degree of freedom, showing a higher amount of heterogeneity in between the studies. In addition, because of the heterogeneity in study design, intervention, follow-up period, and presence of low-quality studies (high risk bias), a quantitative analysis was not conducted. On qualitative analysis, a total of 160 new white spot lesions were developed in the clear aligner group and 362 new white spot lesions were found in the multibracket fixed orthodontic group. All the three included studies

Table 1: Characteristics of included studies

Studies	Number of subjects	Age group and Gender	Treatment duration and Follow-up	Variables	Outcome
Albhaisi et al., 2020 ²⁰	49 subjects taken, 42 complete d the study 19 (CA group) 23 (FA group)	21.25±3 years for both CA and FA group. 39 females and 10 males.	Duration of the treatment was not mentioned Outcome variables were measured during treatment (3 months).	Primary outcome variable; Newly developed white spot Lesions Secondary outcome variables; 1. Mean amount of fluorescence loss. 2. Deepest point in the lesion. 3. Lesion area in pixel format. 4. Plaque surface area	Post-treatment mean fluorescence loss was higher in FA group. Newly developed white spot lesions were found more in FA group. Value of deepest point in lesion was significantly higher in FA group. Lesion area was significantly higher in CA group. FA group exhibit significantly more plaque accumulation than CA group.
Buschang et al., 2020 ²²	CA group-244 subjects FA group-206 subjects	30.4±14 years; CA group 29.2±11.5 years; FA group	CA therapy- 1.5±0.9 years FA treatment- 2.5±1.3 years	Change in pre-treatment and post-treatment oral hygiene status Incidence of white spot lesions	Oral hygiene was better in patients with removable aligners. Less incidence of developing white spot lesion in aligner group
Alshatti, 2017 ²¹	24 subjects (CA therapy) 16 subjects, self-ligating brackets (FA) 19 subjects, conventional brackets subjects (FA)	No gender description. 17-24 years age group No gender description.	No follow-up period was mentioned. 16.83±5.11 months (CA therapy) 17.40±6.28 (self-ligating brackets- FA) 19.52±4.40 (conventional brackets- FA) Outcome was	Incidence of white spot lesion Surface area or severity of white spot lesion Correlation between gingival, plaque and bleeding indices and White spot lesions.	Incidence of white spot lesion in clear aligner group was found low as compare to conventional and self-ligating bracket groups. Surface area of white spot lesion in clear aligner group was more but less severe in nature. Gingival, plaque and bleeding indices values for clear aligner group were always lower than fixed appliance group.

mentioned $P < 0.001$; that indicates a significantly lesser number of newly developed lesions in the clear aligner group. According to Albhaisi et al.,²⁰ post-treatment mean fluorescence loss was higher in the FA group that indicate more newly developed white spot lesions in FA group along with the value of deepest point in the lesion was found significantly higher in the same group. Contrast to the above findings lesion area was significantly higher in the CA group. Similarly, Buschang et al.²² concluded that less incidence of developing white spot lesion seen in the aligner group than FA therapy. In addition, according to Alshatti et al.,²¹ Incidence of white spot lesion in clear aligner group was found low as compared to conventional and self-ligating bracket groups along with the surface area of white spot lesion in clear aligner group was more but less severe in nature. Furthermore, it was also concluded by all the three studies that oral hygiene status was poor with FA therapy (more plaque accumulation and gingival bleeding). Moreover, there was no significant difference found regarding age group and gender during evaluation.

5.1. Quality of the included studies

The risk of bias assessment of Randomized controlled clinical trials^{20,21} are summarized in (Table 3, Figure 1 b) and for prospective study²¹ in (Table 4, Figure c). The risk of bias was assessed, in which one trial²⁰ was evaluated at high risk of bias due to absence of blinding of outcome assessment and another²¹ was found to have a low risk of bias. Overall moderate risk of bias in the included prospective study was found²² because of selection of the participants were done on the basis of the recent completion of cases which led to some concerns regarding the quality of the study, and low risk of bias was judged against the other six domains of the ROBINS-1 tool. (Table 4, Figure 1 c) The quality of evidence was assessed using GRADE tool, on the basis of which, moderate result was found in randomized controlled clinical trials^{20,21} and high outcome was found in the prospective study.²² (Figure 1 d)

6. Discussion

White spot lesions are aesthetically unpleasant if develop on anterior teeth and influence a person's confidence and smile.²³ This review was done in order to evaluate the incidence of white spot lesions in clear aligner and multibracket fixed appliance therapy. The results show significantly less incidence of white spot lesion in clear aligners as compared to the fixed appliances. ($p < 0.001$) It is in agreement with a study conducted by Muhammad Azeem et al.¹⁴ in which patients treated with clear aligners but without taking control group. A possible explanation for this low incidence of enamel demineralization in the CA group may attributable to less food lodgement over appliance since patients do not wear the appliance

during the meal, favorable maintenance of oral hygiene, and minimum chances of accumulation of microbial flora i.e., streptococcus mutans and lactobacillus over aligner and tooth surface.²⁴ According to another study, shorter treatment duration in aligners therapy may obviate the risk of developing WSLs as compared with FA therapy.²⁵

Although incidence of WSL is low in clear aligner group, included studies show severe heterogeneity. (I^2) Limited flow of saliva to the teeth surfaces while using clear aligner and attachments of appliance may interfere with the self-cleansing activity of saliva resulting in enamel demineralization.²⁶ Only one study assessed mineral loss and depth of the lesion which is more in the fixed appliance group.²⁰ The size of WSL developed in patients with fixed appliance treatment were small with greater enamel demineralization and lesions in patients with clear aligner therapy were large with lesser demineralization.²⁰

The wide attachment bonded on the tooth surface in the CA group may be a possible explanation of wide lesion. Age is considered as a risk factor to develop white spot lesions in orthodontic patients, younger patients most of the preadolescent age group reported with increased incidence of white spot lesions.¹¹ Study performed by Mizrahi⁹ concludes that frequencies of white spot lesions are gender independent. However, contrary to this, other^{27,28} disagree with a greater male predilection for developing WSLs.

All three studies included in this systematic review provides data of 551 subjects irrespective of their gender and age to assess the incidence of white spot lesions evaluated with various methods like digital photography and quantitative light-induced fluorescence with the help of various indices and criteria to evaluate the measurements show heterogeneity in studies.

Oral hygiene and white spot lesion development are closely linked and patients with poor pre-treatment oral hygiene are more likely to develop WSLs than with fair oral hygiene.²³

6.1. Strength and future research recommended

We followed well-established guidelines for the conduction of this analysis that has been undertaken with the thorough searching of the electronic databases. Results of this review are of clinical significance that can be used for choosing the appropriate appliance for the specific orthodontic condition in consideration of post-treatment aesthetic. Clear aligner therapy showed a low incidence of white spot lesions, so it may be a preferred treatment option especially in patients with high caries susceptibility and poor oral hygiene. In addition, clinicians need to encourage their patients regarding oral hygiene maintenance, more during fixed appliance treatment.

Due to lack of high-level evidence regarding this topic, more randomized clinical trials with proper design are required to draw a definite conclusion. Ideally white spot

lesion should be studied after debonding because bracket would interfere with adequate assessment of the tooth surface and short-term study will not conclude definite results.

7. Limitations

There are some limitations to the present review mainly because of the limited number of studies found, in which one study was presented with low quality or high risk of bias. There are limitations to the generalizability of our results due to the presence of severe heterogeneity with respect to sample size, method of WSLs recording, parameters taken, age group, gender variation, and treatment duration. Based on the analysis, conclusive evidence of the outcome is low.

8. Conclusion

Based on all the studies included in this review, the following conclusion can be made:

1. Incidence of white spot lesions was less in patients under clear aligner group compared to fixed orthodontic treatment group.
2. Size of the white spot lesion was larger in subjects with clear aligner therapy than subjects with traditional braces but mineral loss associated with clear aligners were lesser than fixed appliances.

However, more low risk of bias studies with proper methodological qualities are required to be conducted in the near future to strengthen the conclusive evidence.

9. Abbreviation

WSL; white spot lesion, FA; fixed appliance, CA; clear aligner

10. Source of Funding

None.

11. Conflict of Interest


None.

References

1. Papageorgiou SN, Papadelli AA, Eliades T. Effect of orthodontic treatment on periodontal clinical attachment: a systematic review and meta-analysis. *Eur J Orthod.* 2018;40(2):176–94.
2. Samandara A, Papageorgiou SN, Marathiotou II, Tsatala SK, Papadopoulos MA. Evaluation of orthodontically induced external root resorption following orthodontic treatment using cone beam computed tomography (CBCT): a systematic review and meta-analysis. *Eur J Orthod.* 2019;41(1):67–79.
3. Kamber R, Papageorgiou SN, Eliades T. Does orthodontic treatment have a permanent effect on tooth color. *J Orofac Orthop.* 2018;79(2):73–82.
4. Sundararaj D, Venkatachalapathy S, Tandon A, Pereira A. Critical evaluation of incidence and prevalence of white spot lesions during fixed orthodontic appliance treatment: A meta-analysis. *J Int Soc Prev Commun Dent.* 2015;5(6):433–42.
5. Artun J, Brobakken BO. Prevalence of carious white spots after orthodontic treatment with multibonded appliances. *Eur J Orthod.* 1986;8(4):229–63.
6. Ke Y, Zhu Y, Zhu M. A comparison of treatment effectiveness between clear aligner and fixed appliance therapies. *BMC Oral Health.* 2019;19(1):24. doi:10.1186/s12903-018-0695-z.
7. Lucchese A, Gherlone E. Prevalence of white-spot lesions before and during orthodontic treatment with fixed appliances. *Eur J Orthod.* 2013;35(5):664–72.
8. Sudjalim TR, Woods MG, Manton DJ. Prevention of white spot lesions in orthodontic practice: a contemporary review. *Aust Dent J.* 2006;51(4):284–93.
9. Mizrahi E. Enamel demineralization following orthodontic treatment. *Am J Orthod.* 1982;82(1):90548–54.
10. Artun J, Brobakken BO. Prevalence of carious white spots after orthodontic treatment with multibonded appliances. *Eur J Orthod.* 1986;8(4):229–63.
11. Chapman JA, Roberts WE, Eckert GJ, Kula KS, Cabezas CG. Risk factors for incidence and severity of white spot lesions during treatment with fixed orthodontic appliances. *Am J Orthod Dentofacial Orthop.* 2010;138(2):188–94.
12. Lagravère MO, Mir CF. The treatment effects of Invisalign orthodontic aligners: a systematic review. *J Am Dent Assoc.* 2005;136(12):1724–33.
13. Papadimitriou A, Mousoulea S, Gkantidis N, Kloukos D. Clinical effectiveness of Invisalign® orthodontic treatment: a systematic review. *Prog Orthod.* 2018;19(1):37. doi:10.1186/s40510-018-0235-z.
14. Hamid W. Incidence of white spot lesions during orthodontic clear aligner therapy. *J World Fed Orthodont.* 2017;6(3):127–30.
15. Moher D, Liberati A, Tetzlaff J, Altman P. Preferred reporting items for systematic reviews and meta-analyses: the PRISMA statement. *Int J Surg.* 2010;8(5):336–77.
16. Higgins JPT, Thomas J, Chandler J. *Cochrane Handbook for Systematic Reviews of Interventions.* 2nd ed. London: Cochrane: Wiley-Blackwell; 2019. p. 736. Available from: www.cochrane-handbook.org.
17. Rayner JCW. Cochran-Mantel-Haenszel tests for the completely randomised design. *J Korean Stat Soc.* 2021;50:185–97.
18. Sterne JAC, Hernán MA, Reeves BC. ROBINS-I: a tool for assessing risk of bias in nonrandomized studies of interventions. *BMJ.* 2016;355:4919.
19. Sterne JAC, Savovic J, Page MJ. RoB 2: a revised tool for assessing risk of bias in randomised trials. *BMJ.* 2019;366:14898.
20. Albhaisi Z, Al-Khateeb SN, Alhaja A. Enamel demineralization during clear aligner orthodontic treatment compared with fixed appliance therapy, evaluated with quantitative light-induced fluorescence: A randomized clinical trial. *Am J Orthod Dentofac Orthop.* 2020;157(5):594–601.
21. Alshatti H. Comparison of White Spot Lesions among Clear Aligners, Self-Ligating Brackets and Conventional Brackets - A Randomized Controlled Clinical Trial. *World J Orthod.* 2008;9(2):46–50.
22. Buschang PH, Chastain D, Keylor CL, Crosby D, Julien KC. Incidence of white spot lesions among patients treated with clear aligners and traditional braces. *Angle Orthod.* 2019;89(3):359–64.
23. Cochrane NJ, Ratneser S, Woods MG, Reynolds EC. Effect of different orthodontic adhesive removal techniques on sound, demineralized and remineralized enamel. *Aust Dent J.* 2012;57(3):365–72.
24. Türköz C, Bavgbek C, Akça S, Varlık K. Influence of thermoplastic retainers on Streptococcus mutans and Lactobacillus adhesion. *Am J Orthod Dentofac Orthop.* 2012;141(5):598–603.
25. Buschang PH, Shaw SG, Ross M, Crosby D, Campbell PM. Comparative time efficiency of aligner therapy and conventional edgewise braces. *Angle Orthod.* 2013;2319:062113–466.

26. Abbate GM, Caria MP, Montanari P, Mannu C, Orrù G, Caprioglio A. Periodontal health in teenagers treated with removable aligners and fixed orthodontic appliances. *J Orofac Orthop*. 2015;76(3):240–50.
27. Tufekci E, Dixon JS, Gunsolley JC, Lindauer SJ. Prevalence of white spot lesions during orthodontic treatment with fixed appliances. *Angle Orthod*. 2011;81(2):206–16.
28. Gorelick L, Geiger AM, Gwinnett AJ. Incidence of white spot formation after bonding and banding. *Am J Orthod*. 1982;81(2):93–8.

Author biography

Deepak Singh, Senior Resident  <https://orcid.org/0000-0003-1208-8989>

Vipul K Sharma, Junior Resident  <https://orcid.org/0000-0002-5487-2440>

Roopal Srivastava, Junior Resident  <https://orcid.org/0000-0002-3510-3910>

Pooja Priyadarshani, Junior Resident

T P Chaturvedi, Professor  <https://orcid.org/0000-0002-8574-9779>

Cite this article: Singh D, Sharma VK, Srivastava R, Priyadarshani P, Chaturvedi TP. White spot lesions in clear aligner therapy as compared with multi-bracket system: A Systematic Review. *J Contemp Orthod* 2023;7(3):165-172.