



## Case Report

# Surgical growth modulation for mandibular retrognathism: A case report

Ashish Kamboj<sup>1\*</sup>, SS Chopra<sup>2</sup>, Nishant Sinha<sup>1</sup>, Paras Angrish<sup>3</sup>, Pushkar Andhare<sup>4</sup>

<sup>1</sup>Dept. of Orthodontics, Govt. Dental Centre, Leh (UT of Ladakh), India

<sup>2</sup>Dept. of Orthodontics, Army Dental Center R & R, Delhi, India

<sup>3</sup>Dental Section, Field Hosp, Tangtse, Ladakh, India

<sup>4</sup>Govt. Dental Centre, Jullundur, Punjab, India



### ARTICLE INFO

#### Article history:

Received 12-07-2023

Accepted 28-08-2023

Available online 03-10-2023

#### Keywords:

Distraction osteogenesis

Aesthetic enhancement

Stomatognathic function

Mandibular retrognathism

### ABSTRACT

A case of 18-year-old female presented with retrognathic mandible having skeletal class II malocclusion, exhibiting convex profile, deep mentolabial sulcus, class II molar, and canine relation bilaterally with proclined maxillary incisors, increased overjet and 100% deep bite. The case had a severe ABO discrepancy index. The leveling and alignment of dental arches were achieved by sequential archwire placement using 0.022" MBT PEA. After leveling and alignment stage, the case was assessed for surgical growth modulation using intra-oral distractors. After necessary planning the case was operated for bilateral sagittal split osteotomy and placement of intra-oral distractors. A standardized protocol was followed for the activation of distractors. Two weeks post distraction the case was reassessed for skeletal changes achieved, followed by settling of occlusion and removal of intra-oral distractors. Skeletal class I bases with improvement in vertical proportions was observed on completion of treatment. This case report suggests that in a patient with mandibular retrognathism and nearly exhausted growth potential, orthodontic treatment in conjunction with meticulously planned and executed mandibular distraction osteogenesis may be effective in achieving aesthetic enhancement and improved stomatognathic function.

This is an Open Access (OA) journal, and articles are distributed under the terms of the [Creative Commons Attribution-NonCommercial 4.0 International](https://creativecommons.org/licenses/by-nc/4.0/), which allows others to remix, and build upon the work non-commercially, as long as appropriate credit is given and the new creations are licensed under the identical terms.

For reprints contact: [reprint@ipinnovative.com](mailto:reprint@ipinnovative.com)

## 1. Introduction

Skeletal Class II malocclusion prevails in 15% of total malocclusions in Indian population.<sup>1</sup> Prognathic maxilla, retragnathic mandible, or a combination of the two may be the cause of the skeletal class II malocclusion. The most frequent cause of skeletal class II malocclusion is mandibular retrognathism.<sup>2</sup> Growth control, treatment for camouflage, and surgical correction are some of the several management strategies for skeletal class II malocclusion. In cases with mandibular retrognathism after growth completion, two treatment

options can resort viz; camouflage orthodontic treatment and ortho-surgical management. Camouflage treatment accounts for dental correction achieved without addressing the skeletal problem. Despite being extremely invasive, surgical mandibular advancement can address skeletal imbalances.<sup>3–8</sup> A combination treatment such as distraction osteogenesis, which exploits the benefits of both growth modulation and surgical corrective treatment can be a better option in the management of skeletal discrepancies post-growth cessation. Mandibular distraction osteogenesis along with bilateral sagittal split osteotomy<sup>3–5</sup> is commonly used for mandibular advancement.<sup>6–8</sup> Surgical mandibular advancement of more than 7mm with a bilateral sagittal split osteotomy show increased chances of relapse

\* Corresponding author.

E-mail address: [aashishkamboj@yemail.com](mailto:aashishkamboj@yemail.com) (A. Kamboj).

postoperatively<sup>9–11</sup> along with increased incidence of condylar resorption.<sup>12–14</sup> Cases requiring more than 7mm of mandibular advancement are better managed using distraction osteogenesis since chances of postoperative relapse, condylar resorption, and damage to the inferior alveolar nerve are reduced owing to relatively slow soft tissue expansion allowing adequate hard and soft tissue remodelling.<sup>15–19</sup> Distraction osteogenesis is a common treatment option and is more successful for non-syndromic growing patients between the ages of 11 and 17 years who have a skeletal Class II malocclusion and an average to low mandibular angle<sup>8,15,16, 20–23</sup> This article demonstrates how distraction osteogenesis was used to successfully treat one such patient, improving both the appearance and functionality of the stomatognathic system.

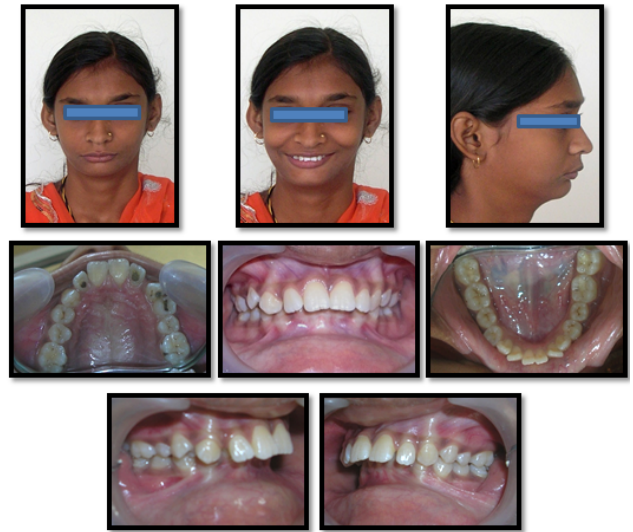**2. Case Report**

*2.1. Case summary*

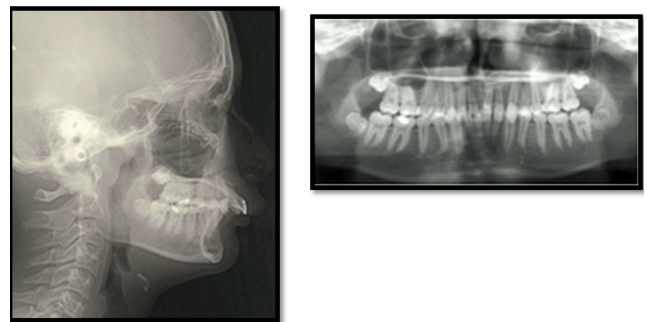
The patient was an 18-year-old female, and her main complaint was that her upper front teeth were positioned forward. Extra-oral examination revealed no signs of temporomandibular joint disorders. She featured a convex facial profile, a deep mentolabial sulcus, and a recessive chin. Intra-oral examination revealed patient in permanent dentition with dental caries wrt 12, 14, 22, 23 and 24, class II molar and canine relationship bilaterally with increased overjet, 100% deep bite (Figure 1). The radiographic study of the lateral cephalogram revealed a retrognathic mandible with an SNB angle of 72 degrees and an ANB angle of 7 degrees, resulting in a skeletal class II jaw relationship. The FMA of 20 degrees and Go-Gn to SN of 26 degrees are suggestive of decreased lower anterior facial height and horizontal growth pattern. The maxillary incisors were protruded with a U1-NA of 40 degrees and 8mm. The CVMI staging indicated that the mandibular growth spurt had ended (Figure 2 and Table 1). The patient’s ABO discrepancy index was 23, which falls under the severe group (Table 2).

**Table 1:** Pre-treatment and post-treatment cephalometric measurements

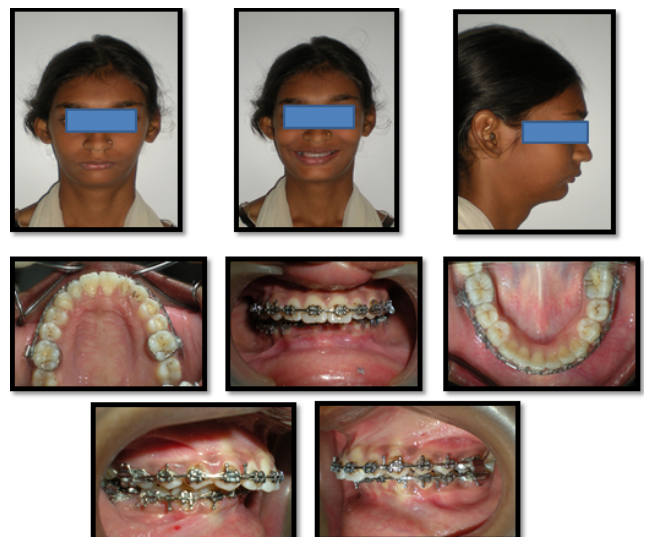Variable	Pre treatment	Post treatment
SNA	79 degree	79 degree
ANB	72 degree	78 degree
U1- NA	40 degree (8mm)	35 degree (7mm)
L1-NB	27 degree (5mm)	24 degree (4mm)
Go-Gn to SN	26 degree	28 degree
FMA	20 degree	21 degree
IMPA	101 degree	98 degree
Co-Gn	110 mm	118 mm
LAFH	59 mm	62 mm



**Figure 1:** Pre-treatment photographs



**Figure 2:** Pre-treatment radiographs



**Figure 3:** Pre-surgical photographs



Figure 4: Pre-surgical prediction tracing

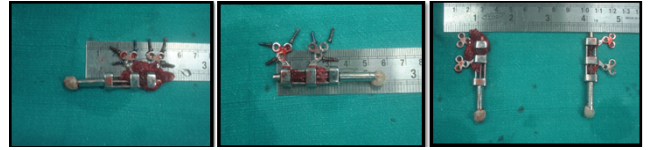


Figure 8: Distractor removal

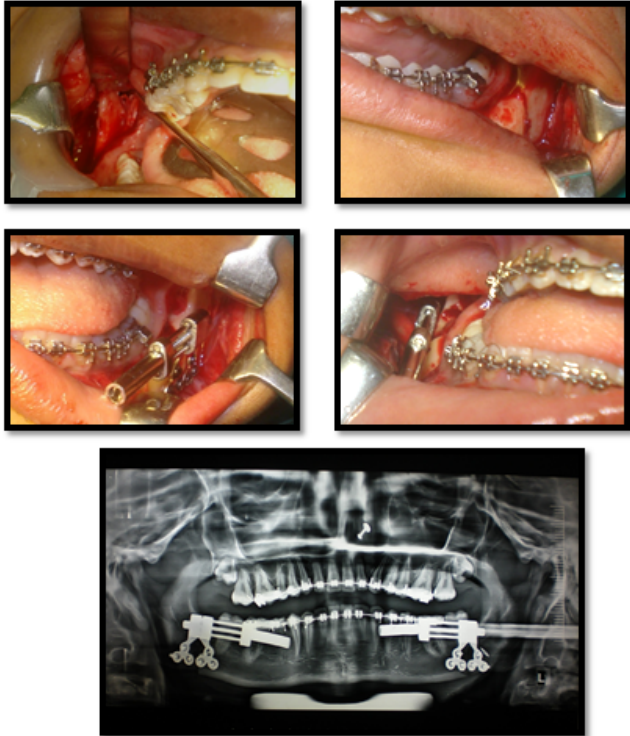


Figure 5: Intraoperative photographs and radiograph

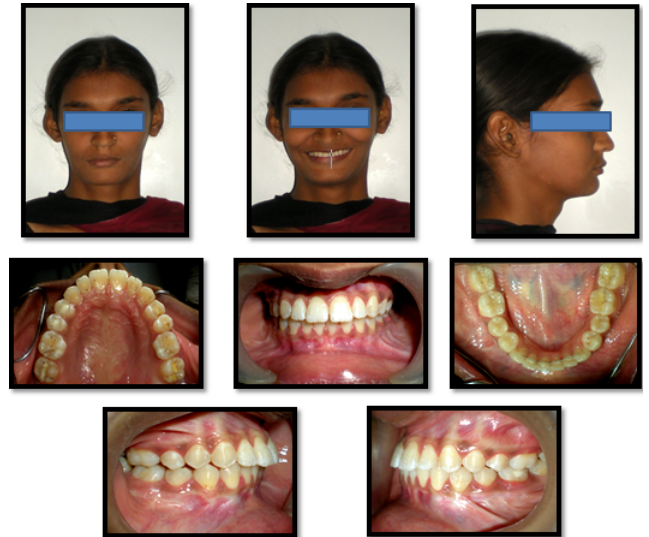

Figure 9: Post-treatment photographs

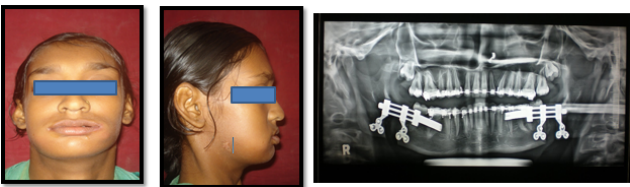


Figure 6: 2 weeks post distraction photographs & OPG

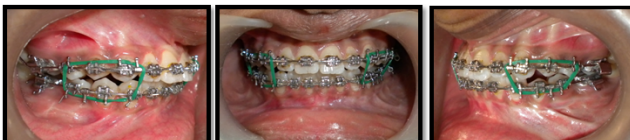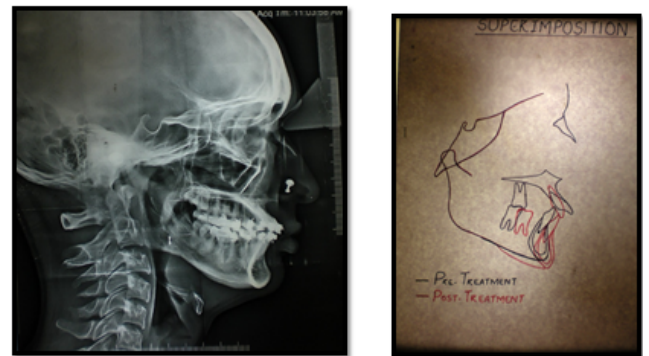


Figure 7: Post distraction settling of occlusion

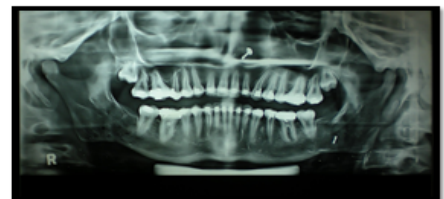


Figure 10: Post-treatment radiographs and superimposition

**Table 2:** ABO discrepancy index of the case

Variable	Value
Overjet	07
Overbite	05
Crowding	00
Occlusion	08
Cephalometrics	05
Total	23 (Severe)
Mild 1-7, Moderate 7-16, Severe 17-25, Extremely severe - Above 25	

### 3. Diagnosis

An adult female patient aged 18 years was diagnosed with skeletal class II malocclusion in CVMI-6 due to retrognathic mandible, convex profile, deep mentolabial sulcus, recessive chin, Angle class II division 1 malocclusion with class II canine relation, increased overjet, and 100% deep bite in conjunction with horizontal growth pattern.

### 4. Treatment Plan

The treatment plan was constituted as follows: — Restoration of caries teeth and prophylactic extraction of mandibular third molars. Fixed mechanotherapy for levelling and alignment of dental arches to be carried out with 0.022" MBT PEA. Distraction osteogenesis to lengthen the mandibular body to improve the mandibular retrognathism and recessive chin to achieve class I skeletal bases. Optimization of overjet and overbite. Finishing and detailing with settling of buccal occlusion and retention.

### 5. Treatment Alternatives

An alternate treatment option for skeletal class II malocclusions with mandibular retrognathism after a growth spurt is camouflage orthodontic treatment employing extraction technique. Though, the skeletal issue is not fixed by this therapy. As a result, we chose surgical orthodontic treatment since it could accomplish the bulk of the patient's problem-list objectives. We chose mandibular distraction osteogenesis with bilateral sagittal split osteotomy above the other surgical options, since achieving class I skeletal bases required more than 7mm of mandibular advancement.

### 6. Treatment Progress

Restoration of caries teeth was carried out using light cure composite. Prophylactic removal of the mandibular third molars bilaterally was carried out. An MBT pre-adjusted edgewise appliance (0.022 x 0.025 inch) was placed in the maxillary and mandibular arches. Sequential archwires were placed starting from 0.016" NiTi, 0.016" x 0.022" NiTi, 0.017" x 0.025" NiTi, and 0.017" x 0.025" SS to achieve levelling and alignment of dental arches over a period of 06 months (Figure 3). Following levelling and

alignment, pre-surgical radiographic analysis was carried out to assess the dental corrections achieved and detailed planning of the surgical procedure (Figure 4). Before the surgical procedure, 0.021" x 0.025" SS archwires were placed in both arches. The intra-oral distraction device (KLS Martin, Umkirch, Germany) was fastened to proximal and distal parts distal to the mandibular second molar bilaterally following a bilateral sagittal split osteotomy (at age 18 years 08 months) (Figure 5). The device was activated at a rate of 1 mm/day (0.5 mm per 12 hours) following an initial recovery period of 8 days. The schedule was continued for further 9 days till the patient exhibited anterior edge-to-edge relation (Figure 6). Post-distraction settling of occlusion was performed using box elastics to prevent post-operative relapse (Figure 7). Seven months after the desired activation, the distraction device was removed (Figure 8). Final settling of occlusion and finishing and detailing was carried out which took a further 3 months. A skeletal class I apical base relationship and an excellent facial profile with the ideal overjet and overbite were obtained after 15 months of ortho-surgical treatment (Figures 9 and 10). The patient was placed on retention using upper Hawleys retainers and lower FSW retainers and a regular follow-up was scheduled

### 7. Results

The patient displayed a decent facial profile, class I skeletal basis, and a tolerable occlusion at the conclusion of treatment. Improvements were made to the protruding upper lip, deep mentolabial sulcus, and inadequate chin. The overjet and overbite were optimized, and the dental arches were levelled and aligned (Figure 9). The post-treatment radiographic study of the lateral cephalogram revealed a balanced face with an FMA of 21 degrees and a Go-Gn to Sn of 28 degrees, as well as a skeletal class I apical base relationship with an ANB angle of 1 degree. The Co-Gn was raised by 8 mm, showing advancement of the mandible. The upper incisors underwent U1-SN retrusion with a 35-degree and 7-mm angle. (Table 1 and Figure 10 ).

### 8. Discussion

An 18-year-old patient with a skeletal class II malocclusion caused due to a retrognathic mandible with a receding chin had orthodontic therapy in conjunction with mandibular distraction osteogenesis. An 8 mm increase in mandibular length (Co-Gn) was seen in the present case. It was possible to acquire a decent facial profile when the skeletal imbalance was fixed. The patient's overjet and overbite were optimized after therapy, and the occlusion was satisfactory. Following bilateral sagittal split osteotomy for mandibular advancement, the literature search turns up numerous instances<sup>24–29</sup> that demonstrate a change in stomatognathic function. Only a small number of papers, meanwhile, could be found that examined how individuals with skeletal

class II malocclusions changed in terms of stomatognathic function following mandibular distraction osteogenesis.

Distraction following an osteotomy with slow incremental activation causes the separation of bony segments to cause the development of new bone, a process known as osteogenesis<sup>30</sup>. It was introduced by Codivilla at the beginning of the twentieth century and was popularized by Ilizarov through extensive studies describing the biomechanical principles of the technique that result in bone formation<sup>31,32</sup>. However, it was McCarthy who used this technique for the lengthening of hypoplastic mandibles.<sup>8</sup> In contrast with the distraction of long bones, maxillofacial distraction involves the need to control three-dimensional movements with superadded complexity because of the shape of the maxillofacial bones, dynamic muscle activity, and involved dental relationship. This makes the technique less predictable than routine orthognathic procedures and requires meticulous planning for execution. Intra-oral distractors have the advantage of being less conspicuous as compared to extra-oral distractors. The callus formation and its remodeling in between the osteotomised segments and also distractor vector control are the two most critical aspects in obtaining the required skeletal and dental corrections.<sup>33</sup> In the case of orthognathic surgery, the same degree of precision is difficult and might not be achieved as compared to distraction osteogenesis because of the slow traction and adequate adaptation time for the soft tissues which constitutes an increase in the soft tissue envelope (distraction histogenesis).<sup>34</sup> Therefore, it was proposed that surgical growth modulation therapy, which combines orthodontic therapy with mandibular distraction osteogenesis, was effective in resolving skeletal disharmonies and enhancing facial features like the profile and function of the stomatognath and teeth.

## 9. Conclusion

Ortho-surgical treatment combined with mandibular distraction osteogenesis may be an efficient treatment option and can be considered as a surgical growth modulation therapy for correction of skeletal discrepancy in adult patients for improving facial aesthetics and stomatognathic function and therefore enhances the quality of life of the patient.

## 10. Source of Funding

None.

## 11. Conflict of Interest


None.

## References

1. Kharbanda OP. Orthodontics-diagnosis and management of malocclusion and dentofacial deformities. 1st ed. USA: Mosby Elsevier; 2009. p. 20–6.
2. Mcnamara JA. Components of class II malocclusion in children. *Angle Orthod.* 1981;51:177–202.
3. Trauner R, Obwegeser H. The surgical correction of mandibular prognathism and retrognathia with consideration of genioplasty. Part I. Surgical procedures to correct mandibular prognathism and reshaping of the chin. *J Oral Surg.* 1957;10(7):677–89.
4. Grammer FC, Carpenter AM. A quantitative histologic study of tissue responses to ramal sagittal splitting procedures. *J Oral Surg.* 1979;37(7):482–5.
5. Wyatt WM. Sagittal ramus split osteotomy: literature review and suggested modification of the technique. *Br J Oral Maxillofac Surg.* 1997;35:137–41.
6. Tavakoli K, Stewart KJ, Poole MD. Distraction osteogenesis in craniofacial surgery: a review. *Ann Plast Surg.* 1998;40:88–99.
7. Strijen PJV, Perdijk BT, Breuning KH. Distractie-osteogenese. Een nieuwe ontwikkeling in de aangezichtschirurgie. *Ned Tijdschr Tandheelkd.* 1998;105:129–131.
8. Mccarthy JG, Stelnicki EJ, Mehrara BJ, Longaker MT. Distraction osteogenesis of the craniofacial skeleton. *Plast Reconstr Surg.* 2001;107(7):1812–27.
9. Van Sickels J, Richardson DA. Stability of orthognathic surgery: a review of rigid fixation. *Br J Oral Maxillofac Surg.* 1996;34(4):279–85.
10. Mobarak KA, Espeland L, Krogstad O, Lyberg T. Mandibular advancement surgery in high-angle and low-angle Class II patients: different long-term responses. *Am J Orthod Dentofac Orthop.* 2001;119(4):368–81.
11. Dolce C, Hatch JP, Van Sickels J, Rugh JD. Rigid versus wire fixation for mandibular advancement: skeletal and dental changes after 5 years. *Am J Orthod Dentofac Orthop.* 2002;121(6):610–9.
12. Moore KE, Gooris PJ, Stoeltinga PJW. The contributing role of condylar resorption to skeletal relapse following mandibular advancement surgery. *J Oral Maxillofac Surg.* 1991;49(5):448–60.
13. Arnett GW, Milam SB, Gottesman L. Progressive mandibular retrusion-idiopathic condylar resorption. *Am J Orthod Dentofac Orthop.* 1996;110(1):8–15.
14. Hoppenreijts TJM, Stoeltinga PJW, Grace KL, Robben CMG. Long-term evaluation of patients with progressive condylar resorption following orthognathic surgery. *Int J Oral Maxillofac Surg.* 1999;28(6):411–8.
15. Van Strijen P, Breuning KH, Becking AG, Tuinzing DB. Stability following distraction osteogenesis to lengthen the mandible: results in 50 patients. *J Oral Maxillofac Surg.* 2004;62(3):304–7.
16. Diner PA, Kollar EM, Martinez H, Vazquez MP. Intraoral distraction for mandibular lengthening: a technical innovation. *J Craniomaxillofac Surg.* 1996;24(2):92–5.
17. Tavakoli K, Stewart KJ, Poole MD. Distraction osteogenesis in craniofacial surgery: a review. *Ann Plast Surg.* 1998;40(1):88–99.
18. Ller PT, Troulis MJ, Rosenberg A, Kaban LB. Changes in the condyle and disc in response to distraction osteogenesis of the minipig mandible. *J Oral Maxillofac Surg.* 2002;60:1327–33.
19. Whitesides LM, Meyer RA. Effect of distraction osteogenesis on the severely hypoplastic mandible and inferior alveolar nerve function. *J Oral Maxillofac Surg.* 2004;62:292–7.
20. Hollier LH, Higuera S, Stal S, Taylor TD. Distraction rate and latency: factors in the outcome of pediatric mandibular distraction. *Plast Reconstr Surg.* 2006;117(7):2333–6.
21. Mommaerts MY, Jacobs W, De Jonghe N. Mandibular distraction using a dynamic osteosynthesis system: MD-DOS. Concepts and surgical technic. *Rev Stomatol Chir Maxillofac.* 1998;99(5-6):223–30.
22. Karacay S, Akin E, Okcu KM, Bengi AO, Altug HA. Mandibular distraction with MD-DOS device. *Angle Orthod.* 2005;75(4):685–93.
23. Schreuder WH, Jansma J, Bierman MW, Vissink A. Distraction osteogenesis versus bilateral sagittal split osteotomy for advancement of the retrognathic mandible: a review of the literature. *Int J Oral Maxillofac Surg.* 2007;36(2):103–10.
24. Throckmorton GS, Ellis E, Sinn DP. Functional characteristics of retrognathic patients before and after mandibular advancement

- surgery. *J Oral Maxillofac Surg.* 1995;53(8):898–908.
25. Harper RP, De Bruin H, Burcea I. Muscle activity during mandibular movements in normal and mandibular retrognathic subjects. *J Oral Maxillofac Surg.* 1997;55(3):225–33.
  26. Zarrinkelk HM, Throckmorton GS, Ellis E, Sinn DP. Functional and morphologic changes after combined maxillary intrusion and mandibular advancement surgery. *J Oral Maxillofac Surg.* 1996;54(7):828–37.
  27. Braber WD, Glas HD, Bilt AD, Bosman F. Masticatory function in retrognathic patients, before and after mandibular advancement surgery. *J Oral Maxillofac Surg.* 2004;62(5):549–54.
  28. Youssef RE, Throckmorton GS, Ellis E, Sinn DP. Comparison of habitual masticatory cycles and muscle activity before and after orthognathic surgery. *J Oral Maxillofac Surg.* 1997;55(7):699–707.
  29. Proffit WR, Turvey TA, Fields HW, Phillips C. The effect of orthognathic surgery on occlusal force. *J Oral Maxillofac Surg.* 1989;47(5):457–63.
  30. Proffit WR, White RP, Sarver DM. Contemporary Treatment of Dentofacial Deformity. 1st ed. St.Louis: Mosby; 2003. p. 768.
  31. Codivilla A. The classic: On the means of lengthening, in the lower limbs, the muscles and tissues which are shortened through deformity. *Clin Orthop Relat Res.* 2008;466:2903–12.
  32. Ilizarov GA. The tension-stress effect on the genesis and growth of tissues: Part I. The influence of stability of fixation and soft-tissue preservation. *Clin Orthop Relat Res.* 1989;238:249–81.
  33. Grayson BH, McCormick S, Santiago PE, Mccarthy JG. Vector of device placement and trajectory of mandibular distraction. *J Craniofac Surg.* 1997;8(6):473–80.
  34. Rachmiel A, Levy M, Laufer D. Lengthening of the mandible by distraction osteogenesis: Report of cases. *J Oral Maxillofac Surg.* 1995;53(7):838–84.

### Author biography

**Ashish Kamboj**, Orthodontist  <https://orcid.org/0000-0002-1836-6786>

**SS Chopra**, Professor and HOD  <https://orcid.org/0000-0002-7983-2541>

**Nishant Sinha**, Endodontist  <https://orcid.org/0000-0001-9015-0755>

**Paras Angrish**, Pedodontist

**Pushkar Andhare**, Orthodontist

**Cite this article:** Kamboj A, Chopra SS, Sinha N, Angrish P, Andhare P. Surgical growth modulation for mandibular retrognathism: A case report. *J Contemp Orthod* 2023;7(3):232-237.