



Case Report

Treatment of an adolescent patient with class ii division 1 malocclusion by extraction and forsus fatigue resistant device: Case report

Nausheer Ahmed¹, Abrar Younus A^{2*}, Shreya K Shetty¹

¹Dept. of Orthodontics, Government Dental College and Research Institute, Bengaluru, Karnataka, India

²Private Practitioner and Consultant Orthodontist, Bangalore, Karnataka, India



ARTICLE INFO

Article history:

Received 04-08-2023

Accepted 10-09-2023

Available online 03-10-2023

Keywords:

Orthopantomogram

Pathologies

The Forsus Fatigue Resistant Device (FFRD)

ABSTRACT

Treatment of a patient presenting with Class II malocclusion requires careful diagnosis and treatment planning to resolve esthetic, occlusal, and functional problems. Over the decades numerous treatment options have been presented to treat class II malocclusions. Orthodontic camouflage being a cost-effective, non-surgical treatment option has been well accepted by patients to mask their underlying skeletal discrepancy, while providing acceptable facial esthetics and occlusion.

This case report presents the treatment by four first premolar extractions followed by Forsus Fatigue Resistant Device (FFRD) therapy in a 14 years old female patient with skeletal Class II base due to the retrognathic mandible, proclined upper and lower front teeth with an overjet of 5 mm, and unwilling for surgery in the future.

After undergoing the treatment, an optimal static and functional occlusion was attained, yielding a favorable outcome.

This is an Open Access (OA) journal, and articles are distributed under the terms of the [Creative Commons Attribution-NonCommercial 4.0 International](https://creativecommons.org/licenses/by-nc/4.0/), which allows others to remix, and build upon the work non-commercially, as long as appropriate credit is given and the new creations are licensed under the identical terms.

For reprints contact: reprint@ipinnovative.com

1. Introduction

Class II, div I malocclusion exhibits a worldwide prevalence of 14% among children aged 12 to 14 years and is the most commonly observed malocclusion type in India. Clinical manifestations of class II, div I malocclusion include a range of severity in the skeletal base, with a predominantly class II molar relationship according to Angles classification. Additionally, it is characterized by class II canine and incisor relationships, maxillary incisors that are inclined forward, an increased overjet, and typically presents a convex facial profile accompanied by lips that are unable to fully close.¹

In the management of class II div I malocclusion, various treatment approaches are commonly utilized. These include the application of a myofunctional appliance

in individuals with ongoing facial growth, the strategic extraction of permanent teeth to facilitate dental camouflage and conceal the skeletal discrepancy, or the consideration of orthognathic surgery for patients who have ceased growing. When addressing class II malocclusions in individuals who are no longer experiencing growth, the extraction options may involve the removal of two maxillary premolars or two maxillary premolars along with two mandibular premolars in order to achieve correction. In growing patients, the extraction of four premolars is primarily recommended in cases of crowding in the mandibular arch, the presence of a cephalometric discrepancy, or a combination of both.²⁻⁴

The functional appliances used in growing patients are either removable or fixed in nature. Fixed devices, in contrast to removable appliances, generally do not rely on the patient's active participation and can be worn concurrently with multibracket therapy. This enables the correction of Class II malocclusion through a single-phase

* Corresponding author.

E-mail address: abraryounus94@gmail.com (A. Younus A).

treatment approach.⁵ Functional appliances exert pressure on the mandible, causing it to move forward. This stimulates adaptive growth in the mandibular condyle and remodeling of the glenoid fossa. As a result, there is a notable increase in the effective length of the mandible and a correction of facial convexity.⁶

In this case report, we describe the treatment of a 14-year-old female patient who presented with a class II skeletal base resulting from a retruded mandible and a protruded maxilla, along with dentoalveolar protrusion. The treatment approach involved extractions followed by the implementation of forsus fatigue resistant device therapy. The Forsus fatigue-resistant device is composed of several components, including a universal spring module, an "L" pin, and a push rod. The push rod comes in five different sizes to accommodate various needs. These components are assembled in such a way that the push rod, of the appropriate size, connects directly to the lower archwire distal to the mandibular canines. The spring, on the other hand, attaches to the headgear tube on the maxillary first molar through the use of the "L" pin.⁷ The main functions of the FRD appliance are limiting sagittal maxillary growth, promoting mandibular growth, inducing mesial movement of the mandibular arch, and distal movement of the maxillary arch.⁸ However, one major side effect of FRD as with any functional appliances is undesirable forward tooth movement of the lower incisors. The proclination of the lower incisors hinders maximum skeletal correction.⁹

1.1. Diagnosis

A 14 years old female patient reported to the department of orthodontics and dentofacial orthopedics, Government dental college and research institute, Bangalore with the chief complaint of forwardly places upper front teeth.

An extraoral examination revealed a mesocephalic head and mesoprosopic facial form. The patient’s profile was convex with posterior divergence, competent lips, acute nasolabial angle, and negative lip step. Reduced length of the mandible, reduced chin projection and low clinical FMA was also noted. No gross facial asymmetry was noted.(Figure 1)

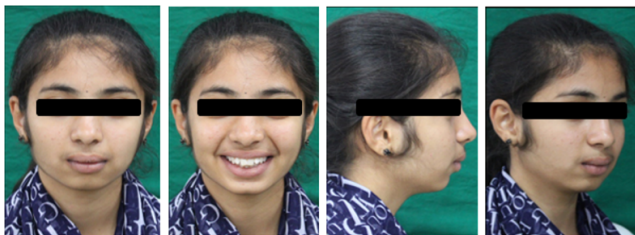

Figure 1: Pre-treatment extraoral photographs

Her intraoral examination revealed, class 1 molar relation on the right side and end on molar relation on the left

side, U-shaped upper and lower arches, proclined upper and lower anteriors with an overjet of 4mm, other individual dental irregularities such as crowding wrt 11,21, 31,41 and posterior crossbite wrt 36, were noted.(Figure 2)

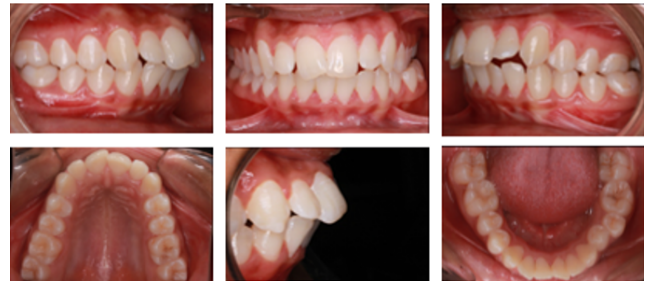

Figure 2: Pre-treatment intraoral photographs

Smile analysis revealed consonant smile arc with increased buccal corridor space.

Cephalometric analysis revealed orthognathic maxilla and retrognathic mandible (Table 1 and (Figure 3).

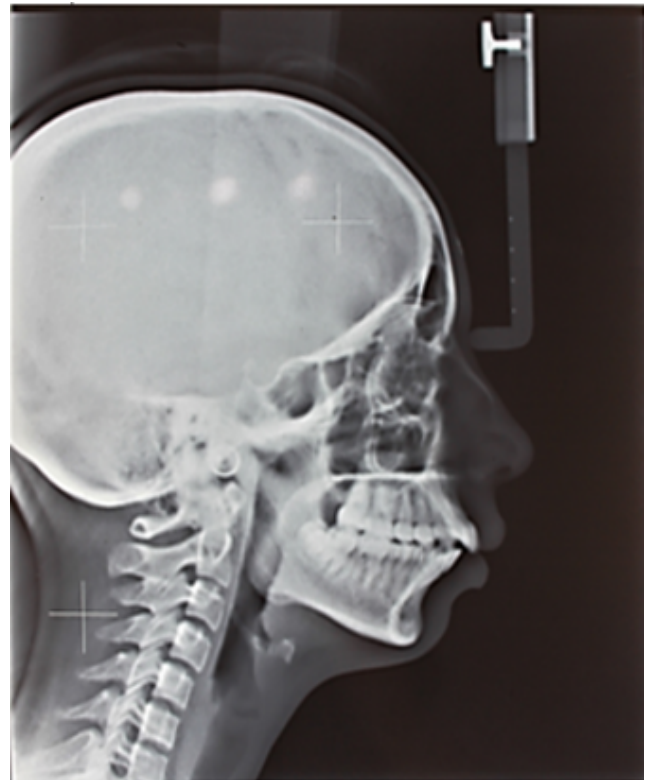
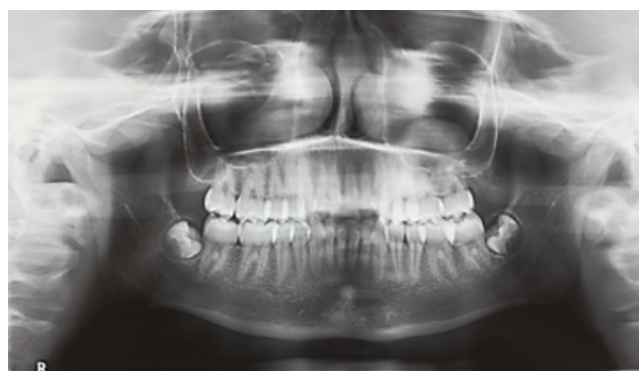


Figure 3: Pre-treatment lateral cephalogram

An orthopantomogram showed partially erupted mandibular third molars and congenitally missing maxillary third molars. There was no evidence of caries, restorations, or any other pathologies. (Figure 4)

Table 1: Cephalometric values

Parameter	Pre-treatment(in ⁰)	Mid-treatment (in ⁰)	Post-treatment(in ⁰)
SNA	78	75	74
SNB	73	70	76
ANB	6	5	2
SND	70	70	72
Mandibular Plane Angle (Go-Me)	23	23	24
Interincisal Angle	102	130	131
Upper Incisor TO SN	105	98	92
Lower Incisor TO MP	116	105	108

**Figure 4:** Pre- treatment OPG

2. Treatment Objectives

The main goals of orthodontic treatment in this case were to address molar relationships, minimize protrusion of the maxillary and mandibular dentoalveolar regions, achieve optimal overjet and overbite, establish a functional occlusion, reduce buccal corridor widths, and enhance facial and smile aesthetics.

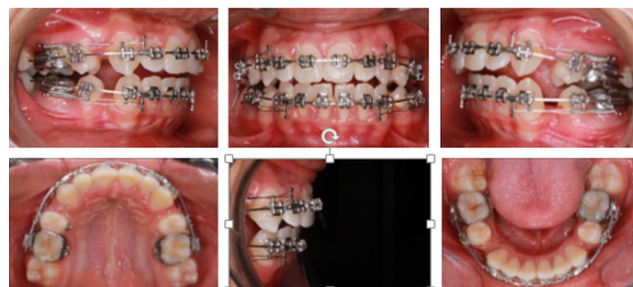
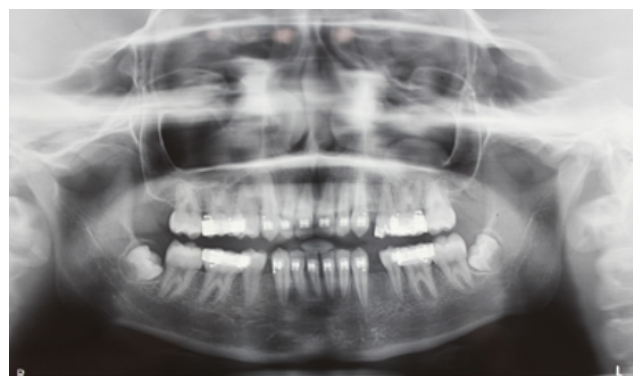2.1. Treatment alternatives

A removable functional appliance therapy was not an appropriate treatment choice, the option to correct the underlying anteroposterior dental and skeletal discrepancy by extraction of four first premolar teeth followed by Forsus fixed functional appliance therapy was accepted by the patient.

Extractions of first premolars were chosen instead of second premolars to correct the dentoalveolar protrusion in upper and lower arches.

2.2. Treatment progress

Extraction of 14, 24, 34, and 44, were carried out following which 0.022" slot MBT brackets were bonded onto all the teeth, leveling and alignment of both arches were carried out using 0.016" NITI archwires, and the following sequence of archwires were used- 0.018 SS, 17*25 NITI, 19*25 SS. En masse retraction of upper and lower anterior segments was carried out using active tiebacks on continuous 19*25SS archwires. (Figures 5, 6 and 7)

**Figure 5:** En -masse retraction of anterior segment**Figure 6:** Mid- treatment OPG

Extraction spaces were closed after six months, following which Forsus fixed functional appliance therapy was initiated (Figure 8).

The appliance was maintained for 7 months after which final finishing and detailing were carried out .014 NITI archwires were paced for 2 months for occlusal settling. Debonding was carried out after occlusal settling was completed and the retention phase was initiated with upper Begg's wrap-around retainer with an anterior inclined plane and lower fixed lingual retainer.

3. Treatment Results

Noticeable enhancements were observed in both facial esthetics and occlusion. The treatment goals were successfully attained, as evidenced by the post-treatment evaluation of the patient's external facial features. The convexity of the profile reduced, buccal corridors

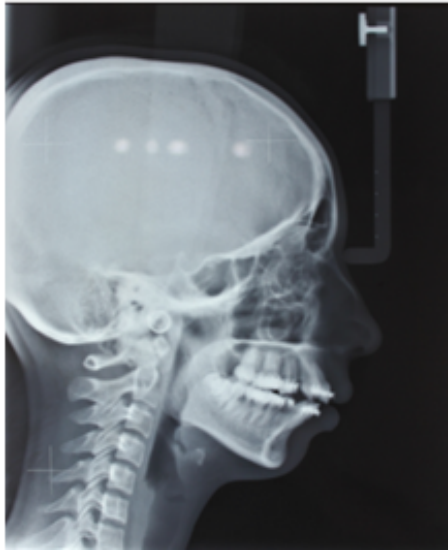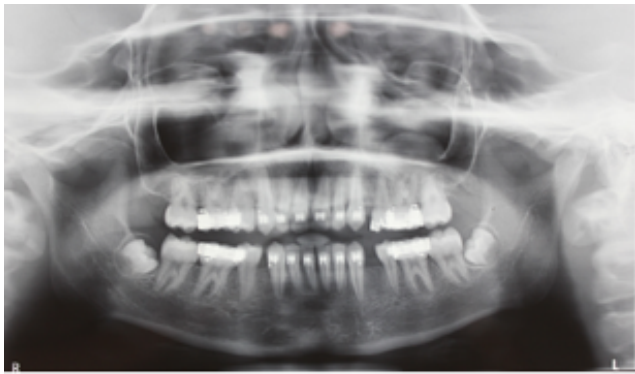


Figure 7: Mid treatment lateral cephalogram

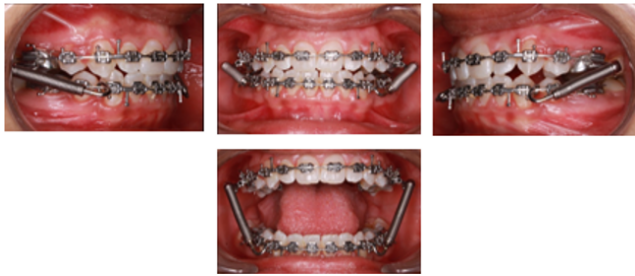

Figure 8: Initiation of forsyth fixed functional appliance therapy

diminished, and there was a remarkable improvement in smile aesthetics. (Figure 9)

The post-treatment intraoral assessment revealed bilateral Class I molar and canine relationships, along with satisfactory intercuspation of the anterior and posterior teeth. (Figure 10). The panoramic radiograph showed satisfactory root angulation for all teeth. (Figure 11)

Following the functional appliance phase and completion of orthodontic treatment, the cephalometric analysis revealed minimal alterations in the skeletal components. However, notable labial inclination of both maxillary and

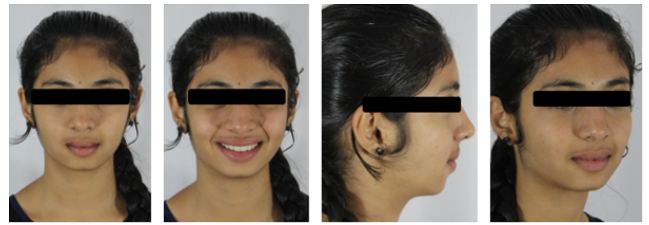


Figure 9: Post- treatment extra- oral photographs

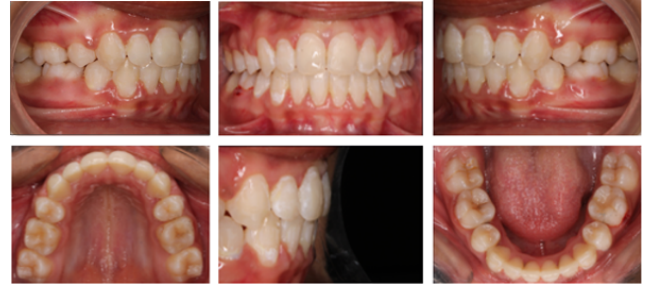

Figure 10: Post- treatment intra- oral photographs

mandibular incisors was observed in the dentoalveolar aspect. The clinical changes observed were verified through cephalometric superimpositions. (Table 1)

4. Discussion

Careful considerations towards facial esthetics, occlusion, and underlying skeletal discrepancy are essential to successfully treat class II malocclusion.

For the correction of dentoalveolar protrusion and moderate to severe crowding, extraction of permanent teeth will be required.

To treat the underlying skeletal discrepancy functional growth modification can be performed in growing patients and in adults surgical correction will be necessary.

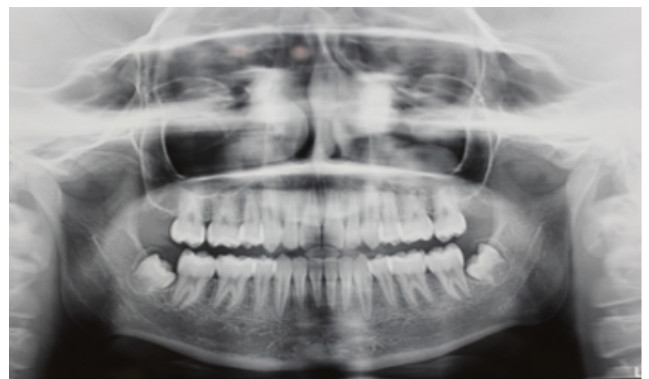

Figure 11: Post- treatment OPG

In children near the end of adolescence, a certain amount of skeletal changes can still be achieved by the use of fixed

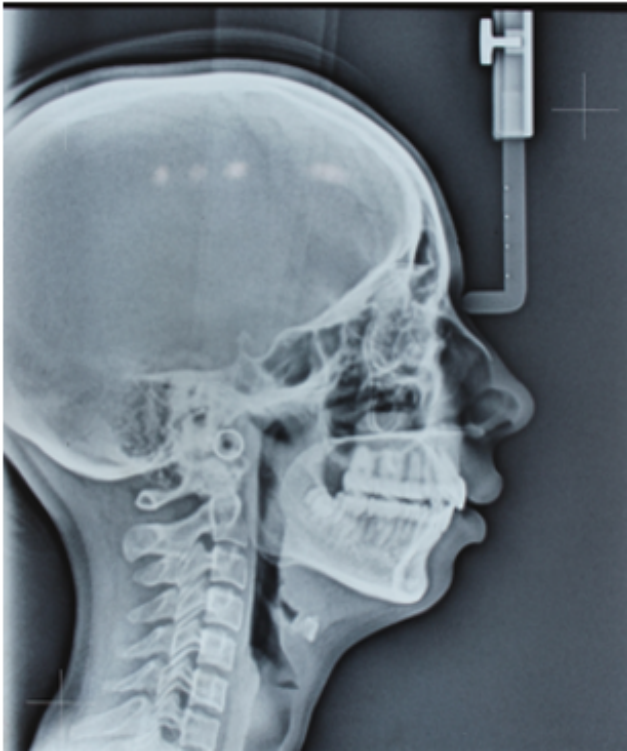


Figure 12: Post- treatment lateral cephalogram

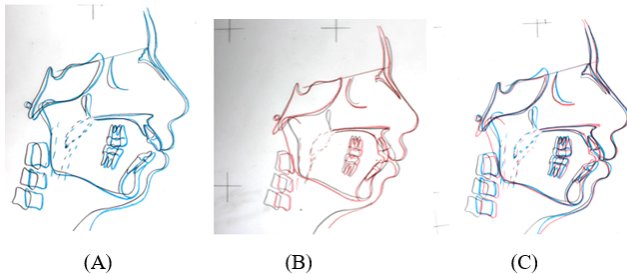


Figure 13: Superimposition of pre-treatment (black), mid-treatment (blue) (a) post-treatment (red) (b), comparison of pre, mid and post treatment cephalometric landmarks (c).

functional appliance.¹⁰

In this particular case, the presence of proclined upper and lower anterior teeth, combined with a class II skeletal base caused by a retruded mandible, posed limitations to the advancement of the mandible through functional appliance therapy. As a result, the extraction of four first premolars was performed in order to address the proclination of the teeth and facilitate the desired advancement of the mandible.

The Forsus Fatigue Resistant Device (FFRD) is categorized as a fixed, hybrid functional appliance. It differs from rigid, fixed functional devices like the Herbst appliance due to its semi-rigid telescopic system, which provides flexibility in mandibular positioning. As a noncompliance device, the FFRD remains fixed in the patient's mouth,

eliminating the need for the orthodontist to rely on the patient's cooperation.¹¹

The FFRD tends to push the upper molars distally and the lower molars mesially to correct the sagittal relationship while maintaining the vertical dimension.¹²

Multiple studies have shown that FFRD corrected the sagittal discrepancy mainly by dentoalveolar changes when used for 5-6 months.¹³

The cephalometric analysis revealed a reduction in ANB angle by 4°.

The lower incisor inclination was reduced by 11° after space closure, but increased by 3° after FFRD therapy. Thus, a total reduction in the lower incisor inclination by 8°. This increase in lower incisor inclination can be attributed to the tendency of the FFRD to procline the lower incisors.

The extraction treatment improved the incisor inclination which allowed the desired amount of forward positioning of the mandible without hindrance.

Extraction before fixed functional appliance therapy eliminated the natural dental compensations and provided stable dental relationships on the skeletal bases. It also counteracted the adverse effects of the fixed functional appliance on dental inclinations.

Therefore, extraction treatment along with the application of FFRD showed favorable dental skeletal and esthetic results.

To further improve the chin prominence in this patient, an anterior sliding genioplasty was advised. But, the patient is satisfied with the current results and is unwilling to undergo surgery. The one year follow-up photographs (Figure 14) reveals well maintained oral hygiene, stable functional occlusion. No further improvement in chin projection due to soft tissue growth was noted.

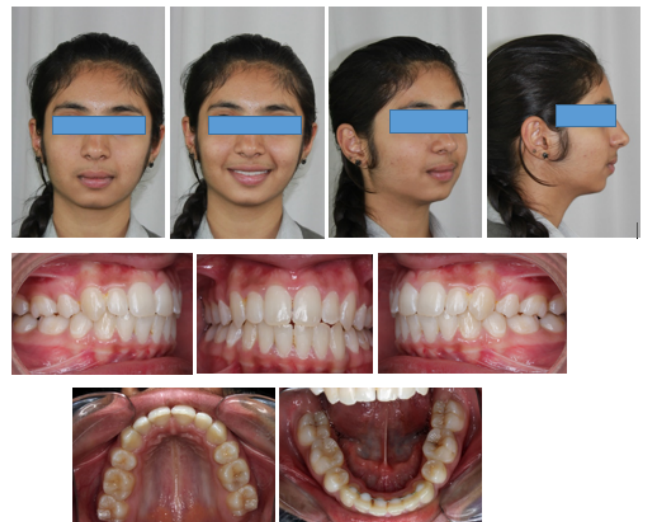

Figure 14: One year post retention extra-oral and intraoral photographs

5. Conclusion

To effectively address the class II malocclusion caused by a retrognathic mandible and bidental protrusion, the FFRD was employed alongside the extraction of first premolars. The premolar extractions created sufficient space for achieving proper tooth inclination and eliminated any obstructions to mandibular advancement. In summary, a growing patient presenting a skeletal Class II malocclusion with a retruded mandible and prominently proclined dentition experienced successful treatment through a combination of a fixed functional appliance and premolar extractions

6. Source of Funding

None.

7. Conflict of Interest


The authors declare no conflict of interest

References

- Naragond A, Kenganal S, Sagarkar R. Orthodontic Camouflage Treatment in an Adult Patient with a Class II, Division 1 Malocclusion - A Case Report. *J Clin Diagn Res.* 2013;7(2):395–400.
- Bishara SE, Cummins DM, Jakobsen JR, Zaher AR. Dentofacial and soft tissue changes in Class II, Division 1 cases treated with and without extractions. *Am J Orthod Dentofac Orthop.* 1995;107:28–37.
- Rock WP. Treatment of Class II malocclusions with removable appliances. Part 4. Class II Division 2 treatment. *Br Dent J.* 1990;168(7):298–302.
- Arvystas MG. Nonextraction treatment of Class II, Division 1 malocclusions. *Am J Orthod.* 1985;88(5):380–95.
- Franchi L, Alvetro L, Giuntini V, Masucci C, Defraia E, Baccetti T, et al. Effectiveness of comprehensive fixed appliance treatment used with the Forsus Fatigue Resistant device in class II patients. *Angle Orthod.* 2011;81(4):678–83.
- Turkkahraman H, Eliacik SK, Findik Y. Effects of miniplate anchored and conventional Forsus Fatigue Resistant devices in the treatment of class II malocclusion. *Angle Orthod.* 2016;86(6):1026–32.
- Vogt W. The Forsus Fatigue Resistant device. *J Clin Orthod.* 2006;40(6):368–77.
- Franchi L, Alvetro L, Giuntini V, Masucci C, Defraia E, Baccetti T. Posttreatment orthopantomogram Effectiveness of comprehensive fixed appliance treatment used with the Forsus Fatigue Resistant device in class II patients. *Angle Orthod.* 2011;81(4):678–83.
- Jones G, Buschang PH, Kim KB, Oliver DR. Class II non-extraction patients treated with the Forsus Fatigue Resistant device versus intermaxillary elastics. *Angle Orthod.* 2008;78(2):332–8.
- Shweta A, Rekha S, Manish A, Lekha S. Combining Extractions with Fixed Functional Appliances in Treatment of Class II Malocclusion: Two Case Reports. *Sch J Dent Sci.* 2017;4(11):515–37.
- Bowman AC, Saltaji H, Flores-Mir C, Preston B, Tabbaa S. Patient experiences with the Forsus Fatigue Resistant Device. *Angle Orthod.* 2013;83(3):437–83.
- Jung MH. Effective mechanics for vertical control with the Forsus Fatigue Resistant Device. *J Clin Orthod.* 2015;49(6):378–87.
- Gunay EA, Arun T, Nalbantgil D. Evaluation of the immediate dentofacial changes in late adolescent patients treated with the Forsus(TM) FRD. *Eur J Dent.* 2011;5(4):423–55.

Author biography

Nausheer Ahmed, Professor and Head

Abrar Younus A, Private Practitioner and Consultant Orthodontist
 <https://orcid.org/0000-0002-5720-9185>

Shreya K Shetty, Post Graduate Student

Cite this article: Ahmed N, Younus A A, Shetty SK. Treatment of an adolescent patient with class ii division I malocclusion by extraction and forsus fatigue resistant device: Case report. *J Contemp Orthod* 2023;7(3):244-249.