



## Case Report

# Unilateral mesialisation using Temporary anchorage device and segmental T loop – A case report

Gaurav Sharma<sup>1</sup>, Vatsal Singhvi<sup>1</sup>, Teena Purohit<sup>1\*</sup>, Rashmi Puri<sup>1</sup>, Garima Gaur<sup>1</sup>, MS Christina<sup>1</sup>

<sup>1</sup>Dept. of Orthodontics and Dentofacial Orthopaedics, Vyas Dental College and Hospital, Jodhpur, Rajasthan, India



### ARTICLE INFO

#### Article history:

Received 02-01-2024

Accepted 01-02-2024

Available online 08-02-2024

#### Keywords:

Segmental T-loop

Ectopic eruption

Mesiodens

Palatally placed premolar

Unilateral mesialisation

Skeletal anchorage

Cherry loop

### ABSTRACT

A temporary anchorage device is a device that is temporarily fixed to bone for the purpose of enhancing orthodontic anchorage either by supporting the teeth of the reactive unit or by obviating the need for the reactive unit altogether, and which is subsequently removed after use. Use of mini implants is one of the innovative approach for complex tooth movements such as mesialisation. Space closure from distal to mesial is one of the most difficult orthodontic tasks. Tooth-borne anchorage limits the scale of tooth movement. Extraoral or intraoral appliances are used especially for unilateral space closure. As an alternative to conventional mesialization appliances, osseointegrated implants may be used for maximum anchorage in orthodontic treatment. The use of direct anchorage in the form of installed mini-implant that is connected to the teeth requiring horizontal movement causes low levels of strains on anchor unit comparing to the results that were registered during indirect anchorage with one or two anchor teeth. This report presents the case of removal of mesiodens and blocked out and fractured premolar and the space closure by unilateral mesialisation with the help of mini implants and loops.

This is an Open Access (OA) journal, and articles are distributed under the terms of the [Creative Commons Attribution-NonCommercial 4.0 International](https://creativecommons.org/licenses/by-nc/4.0/), which allows others to remix, and build upon the work non-commercially, as long as appropriate credit is given and the new creations are licensed under the identical terms.

For reprints contact: [reprint@ipinnovative.com](mailto:reprint@ipinnovative.com)

## 1. Introduction

Ectopic eruption is a disturbance in which the tooth does not follow its usual course. In this case, the presence of a mesiodens has caused the central incisor to take a deviated path. Another ectopic eruption was noticed in upper left second premolar which erupted palatally to the main arch. This article presents the course of treatment followed after extraction of these ectopically erupted and supernumerary teeth. Their management included closure of the space created after their removal by mesialisation of the arch in two segments. It was successfully managed by using the mini implants for absolute anchorage and friction less mechanics.

## 2. Case Report

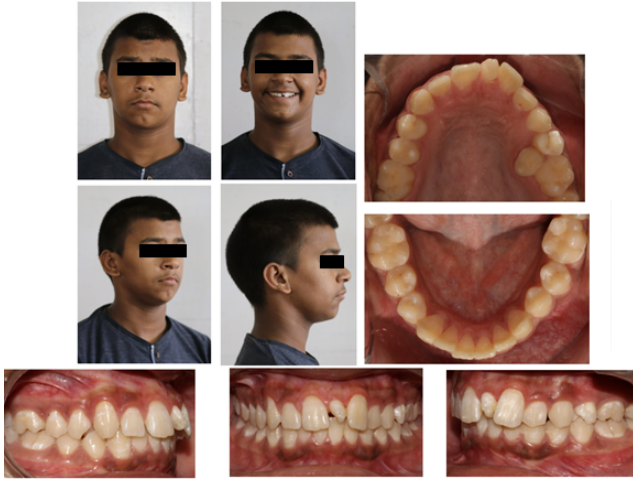A 15 year old male GP presented with the chief complaint of irregularly placed upper front teeth Extraoral examination shows convex facial profile, mesocephalic head shape and leptoprosopic facial form, no gross asymmetry of face, average nasolabial angle, shallow mentolabial sulcus and competent lips.<sup>1</sup>

Intraoral findings include Molar relation Class I on right side and End on relation on left side, Canine relation class I on the right side and class III on left side. Presence of mesiodens between 11 and 21. Presence of palatally placed and fractured 25. Overjet of 4 mm and overbite of 5 mm. Mesiolabial rotation of 14, 21, 24, Distolabial rotation of 35, 44. Not recordable upper and lower dental midlines.<sup>2-4</sup>

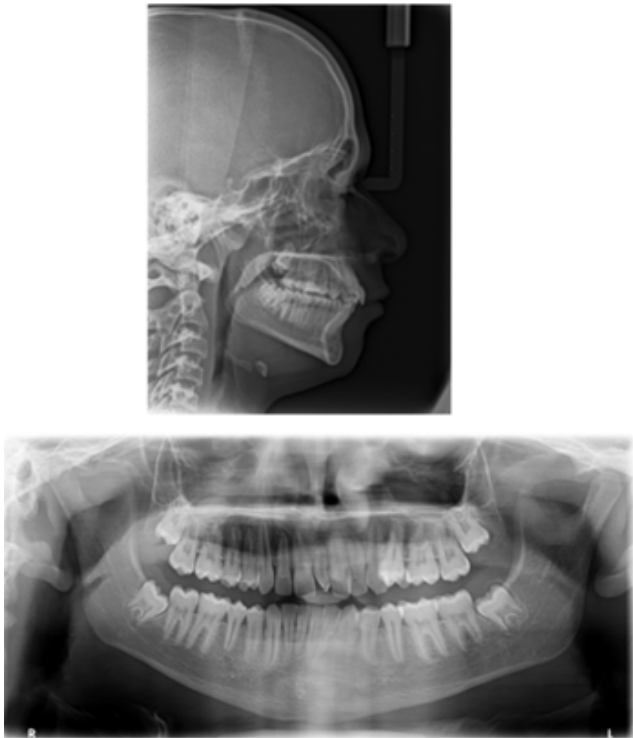
Cephalometric findings showed skeletal Class I jaw bases with orthognathic maxilla and mandible and

\* Corresponding author.

E-mail address: [teena.purohit02@gmail.com](mailto:teena.purohit02@gmail.com) (T. Purohit).



**Figure 1:** Pre treatment photographs



**Figure 2:** Pre-treatment radiographs

normodivergent growth pattern, Normally inclined upper and slightly proclined lower incisors.

Model analysis reveals arch perimeter excess by 1.5 mm in upper arch and 1 mm tooth material excess in lower arch.

### 2.1. Problem list

1. Presence of supernumerary teeth (mesiodens)
2. Fractured and Palatally placed 25
3. Rotation of 14, 21, 24, 35, 44

4. Increased overbite
5. Mild spacing in upper anteriors
6. Mild crowding in lower anteriors
7. Not recordable dental midlines

### 3. Treatment Objective

1. Leveling and aligning the teeth in both the arches
2. Correction of rotations
3. Correction of spacing and crowding
4. To establish proper overjet and overbite
5. To establish proper occlusion and midline

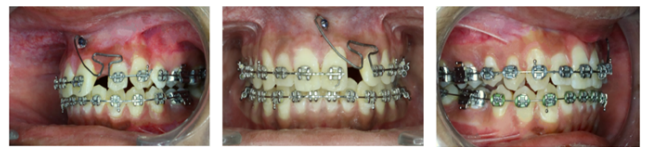#### 3.1. Treatment plan

Pre-adjusted edgewise appliance with MBT prescription with 0.022'' slot.

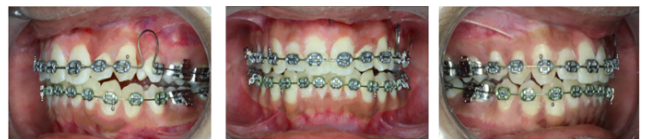#### 3.2. Treatment progress

Extraction of mesiodens and blocked out 25 with fracture was done. Initial leveling and alignment started in following sequence for both the arches - 0.014'' NiTi, 0.016'' NiTi, 0.018'' NiTi, 0.018'' SS and 16×22 SS for 6 months. After this, mini implants were placed between 11 and 21. Sectional T-loop was given with absolute anchorage for mesialisation of 22 and 23. Simultaneously, arch was consolidated from 16 to 21. This was continued for 4 months. After completion of mesialisation, T-loop was removed. Now for mesialisation of 25 and 26, Cherry loop was fabricated using 17×25'' TMA wire that took 3 months to complete. Arch wires were updated to rectangular SS wires.<sup>5-9</sup>

Class II elastics were given on right side and class III elastics were given on left side for next 4 months. To achieve good cuspal interdigitation and settling elastics were given for 3 months.



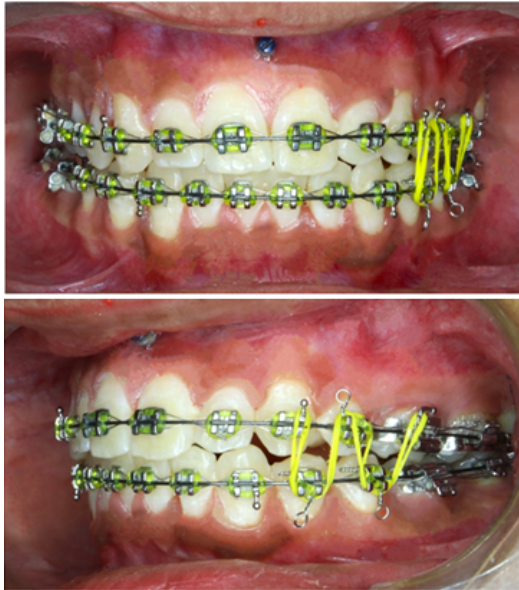
**Figure 3:** T loop mechanics



**Figure 4:** Cherry loop

**Table 1:** Pre and post cephalometric value

Parameters	Pre- treatment	Post- treatment
SNA	83	84
SNB	78	80
ANB	5	4
Wits (AO-BO)	1mm	0.5mm
UI-SN	103	106
IMPA	100	95
FMA	24	28
Nasolabial angle	98	98
Mentolabial sulcus	136	133

**Figure 5:** Settling stage

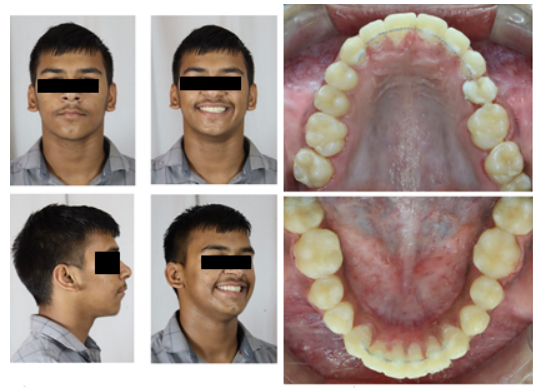
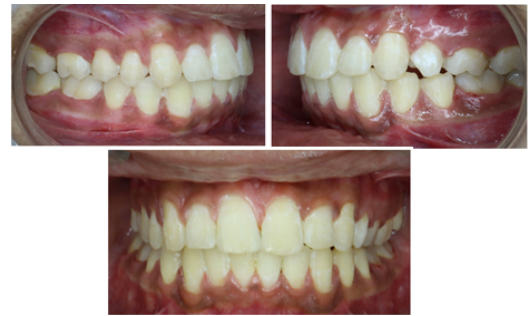#### 4. Treatment Result

Treatment objectives were fulfilled with establishment of overjet and overbite of 2mm. Class I molar on right side and class II on left side. Canine relation class I on both the sides were appreciable. There was complete space closure in both the arches along with proper alignment.

The post treatment cephalometric evaluation showed that there was increase in following angles : SNA by 1°, SNB by 2°, FMA by 4°, UI-SN by 3° and decrease in IMPA by 5°. All variations are within normal range.

#### 5. Discussion

Technology advancement has contributed significantly to the field of treatment planning in dentistry and Orthodontics. Application of mini implants in modern dentistry has revolutionized treatment approaches to reach ideal treatment results. One such case has been presented that emphasizes on space closure by means of arch mesialisation in two segments. Mesial movement of whole arch from left side

**Figure 6:** Post treatment photographs**Figure 7:** Post treatment photographs

may cause anchorage loss, so two step mesialisation was planned. Firstly the space created by supernumerary teeth was closed till canine by segmental T-Loop using absolute anchorage. Remaining posterior segment was mesialised by using loop mechanics. Loss of anchorage is the foremost concern in such cases, but with the help of mini implants it was done with predictable results. If mesialisation was not planned in this case, there could have been chances of not achieving proper molar and canine relation. Patient is expected to have stable results as the treatment was done in early stages of growth.<sup>10-13</sup>

#### 6. Conclusion

Innovative application of Temporary Anchorage Devices could simplify the modification of iatrogenically skewed dental arches with desirable aesthetics. Using these have provided a more predictable and less invasive treatment results compared to other compelling treatment plan alternative. The planned treatment was executed with absolute anchorage without any complication. The overall treatment time was 20 months. The desired objectives of smile and facial esthetics, functional occlusion and stability were achieved.

## 7. Source of Funding

None.

## 8. Conflict of Interest

None.

## References

1. Cope JB. Temporary anchorage devices in orthodontics: A paradigm shift. *Seminars Orthod.* 2005;11(1):3–9.
2. Hemmatpour S, Oonchi M, Karami S, Nahvi G. Temporary Anchorage Device as an Innovative Alternative for Unilateral Arch Mesialization in Medical Application. *Biointerface Res Appl Chem.* 2021;11:8825–35.
3. Reynders R, Ronchi L, Bipat S. Mini-implants in orthodontics: a systematic review of the literature. *Am J Orthod Dentofac Orthop.* 1995;135(5):1–19.
4. Gedrange T, Boening K, Harzer W. Orthodontic implants as anchorage appliances for unilateral mesialization: A case report. *Quintessence Int.* 2006;37(6):485–91.
5. Rivis O, Potapchuk A, Khomyn MG, Bokoch A. Use of mini-implant anchorage for second molar mesialization: comprehensive approach for treatment efficiency analysis. *Assoc Supp Oral Health Res.* 2020;20:1–11.
6. Hasan AS, Kolemen M, Elkolaly A, Marya S. TAD's for the Derotation of 90° Rotated Maxillary Bicuspid. *Case Rep Dent.* 2021;28:4285330.
7. Russell K, Folwarczna M. Mesiodens-Diagnosis and Management of a Common Supernumerary Tooth. *J Can Dent Assoc.* 2003;69:362–8.
8. Vecilli AF, Freitas M. The T-loop in details. *Dental Press J Orthod.* 2018;23(1):108–17.
9. Becker K, Pliska A, Busch C, Wilmes B, Wolf M, Drescher D. Efficacy of orthodontic mini implants for en masse retraction in the maxilla: a systematic review and meta-analysis. *Int J Impl Dent.* 2018;4(1):35. doi:10.1186/s40729-018-0144-4.
10. Venugopal A, Manzano P, Rengalakshmi S. A Novel Temporary Anchorage Device Aided Sectional Mechanics for Simultaneous Orthodontic Retraction and Intrusion. *Case Rep Dent.* 2020;p.:5213936. doi:10.1155/2020/5213936.
11. Barham M, Okada S, Hisatomi M, Khasawneh A, Tekiki N, Takeshita Y, et al. Influence of mesiodens on adjacent teeth and the timing of its safe removal. *Imaging Sci Dent.* 2022;52(1):8967489.
12. Yaseen SM, Naik S, Uloopi KS. Ectopic eruption - A review and case report. *Contemp Clin Dent.* 2011;2(1):3–7.
13. Hemmatpour S, Nahvi G, Oonchi M, Karami S. An Innovative Miniscrew-Based Jig for Unilateral Total Arch Mesialization. *Biointerface Res Appl Chem.* 2020;11(2):1–11.

## Author biography

**Gaurav Sharma**, Professor and Head

**Vatsal Singhvi**, Senior Lecturer

**Teena Purohit**, PG Student  <https://orcid.org/0009-0004-2546-6090>

**Rashmi Puri**, Reader

**Garima Gaur**, Senior Lecturer

**MS Christina**, PG Student

**Cite this article:** Sharma G, Singhvi V, Purohit T, Puri R, Gaur G, Christina MS. Unilateral mesialisation using Temporary anchorage device and segmental T loop – A case report. *J Contemp Orthod* 2024;8(1):67-70.