



## Case Report

# Treatment of a challenging case of impacted, severely dilacerated & deflected maxillary central incisors: A case report with 10 years follow up

Param Makhija<sup>1</sup>, Mukesh Gupta<sup>2</sup>, Kratika Mishra<sup>1b 2\*</sup>

<sup>1</sup>Dept. of Dentistry, GCS Medical College, Ahmedabad, India

<sup>2</sup>Dept. of Orthodontics, Index Institute of Dental Sciences, Indore, Madhya Pradesh, India



### ARTICLE INFO

#### Article history:

Received 08-02-2024

Accepted 08-03-2024

Available online 15-05-2024

#### Keywords:

Bilaterally dilacerated maxillary incisors

Impacted incisor

orthodontics

Surgical exposure

Multidisciplinary treatment of dilacerated teeth

Pedodontics

### ABSTRACT

Impaction, dilaceration, and internal deflection of both maxillary permanent central incisors are not frequently reported in dental practice. The treatment approach is essential as it plays a pivotal role in contributing to the facial aesthetics and occlusion in permanent dentition of the individual. This is a case of a 10-year-old male diagnosed radio graphically with impacted, severely dilacerated, and deflected both the Maxillary central incisors. The management of the case was carried out surgically and orthodontically. By combining two stages of surgical exposure, orthodontic traction and alignment, the impacted dilacerated and deflected incisors were successfully moved into the desired position. A ten-year follow-up of the stability and periodontal health showed that the tooth placed in the occlusion maintained both esthetics and function.

This is an Open Access (OA) journal, and articles are distributed under the terms of the [Creative Commons Attribution-NonCommercial-ShareAlike 4.0 License](https://creativecommons.org/licenses/by-nc-sa/4.0/), which allows others to remix, and build upon the work non-commercially, as long as appropriate credit is given and the new creations are licensed under the identical terms.

For reprints contact: [reprint@ipinnovative.com](mailto:reprint@ipinnovative.com)

## 1. Introduction

An impacted tooth is one that fails to erupt into the oral cavity within the expected time. The frequency of maxillary central incisor impaction has been found in the range of 0.006% to 0.2%.<sup>1</sup> The dilaceration is characterized by an angulation in the crown and root of the tooth. This is often related to the trauma from the primary central incisors during the early developmental stages of the permanent central incisors.<sup>2</sup>

Orthodontic correction of severely dilacerated deflected impacted maxillary incisors is challenging due to its limiting factors like ankylosis, position of teeth, root resorption, time of treatment, successful outcome, multidisciplinary approach, patient cooperation, long duration and follow-up of treatment etc. (3-8). Delay in orthodontic and surgical intervention will result in unnecessary difficulties in aligning the tooth in the arch.<sup>3</sup>

\* Corresponding author.

E-mail address: [kratikamishra1990@gmail.com](mailto:kratikamishra1990@gmail.com) (K. Mishra).

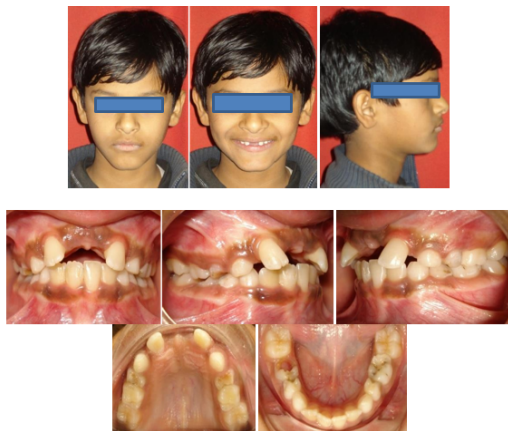## 2. Case Report

A 10-year-old boy reported to the Department of Orthodontics, Modern Dental College and Research Centre, Indore, India, with a chief complaint of non-eruption of front two teeth giving ugly look and hampered facial aesthetics. Patient had a history of trauma 4 years ago with the avulsion of deciduous maxillary central incisors. No relevant past medical history.<sup>4-6</sup>

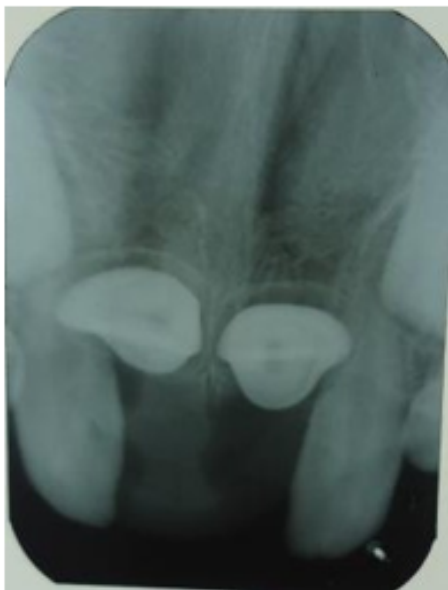## 3. Diagnosis

The clinical examination revealed a mesoprosopic facial form and a convex facial profile and presence of good facial balance. An intraoral examination revealed the mixed dentition with Angle's Class I Molar relation bilaterally with two missing maxillary permanent central incisors [Figure 1]. An intraoral periapical radiograph of upper anterior region demonstrated impacted permanent both maxillary central incisors. [Figure 2]. To confirm the

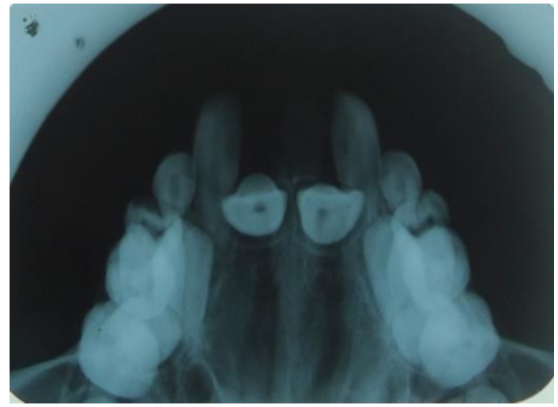
position and morphology of impacted teeth an occlusal radiograph [Figure 3] and Panoramic (orthopantomogram or OPG) were taken [Figure 4]. Table showing Comparison of Cephalometric analysis and its inference showing changes in pre-treatment and post treatment.(Table 1) This established a diagnosis of bilaterally impacted, dilacerated and deflected maxillary central incisors. It was decided to orthodontically align the incisors. The CBCT of maxilla was taken to further confirm the root dilacerations of inverted maxillary incisors and its 3-dimensional position in maxilla. Maxillary central incisors were seen inverted with cingulum facing labially and also touching the nasal floor with crown root angulation nearing right angle. [Figure 5]



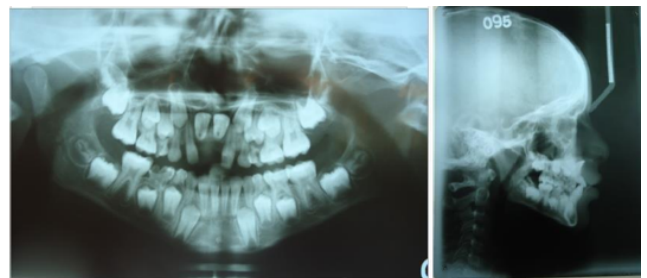**Figure 1:** Pre-treatment extra-oral and intraoral pictures



**Figure 2:** Pre-treatment intra-oral radiograph



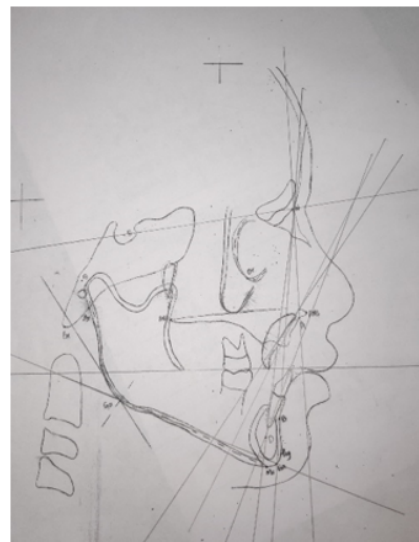
**Figure 3:** Occlusal radiograph showing impacted and dilacerated maxillary central incisors.



**Figure 4:** Pre-treatment OPG and lateral cephalogram showing inverted maxillary central incisors, mixed dentition and erupting canines and premolars.



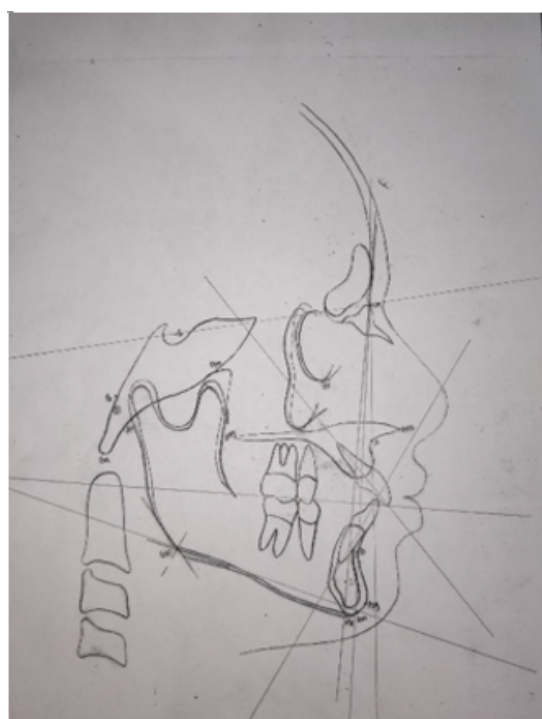
**Figure 5:** CBCT image of maxilla showing both maxillary incisors dilacerated inverted and deflected to nasal floor with cingulum facing labially.



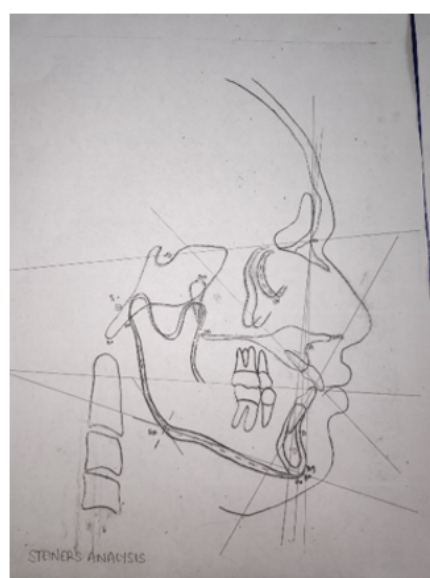Cephalometric tracing of pre-treatment

**Table 1:** Table showing comparison of cephalometric analysis and its inference showing changes in pre-treatment and post treatment.

Parameters	Pre -Treatment	Post- Treatment	Post 10 years Follow-up
Facial Angle (Mean 82 °-95°)	85°	84°	86°
Angle of Convexity (Mean -8.5 °-10°)	+12°	+3°	+1°
AB Plane Angle (Mean 0 °-9°)	-9°	-7°	-4°
Mandibular Plane Angle (Mean 17 °-28°)	25°	25°	23°
Y-Axis (Mean 53 °-66°)	57°	60°	58°
Inter-Incisal Angle (Mean 130 °-150°)	12°	108°	107°
SNA (Mean-82°)	83°	81°	82°
SNB (Mean-80°)	76°	78°	80°
ANB (Mean-2°)	7°	3°	2°
SND (Mean-76°)	73°	75°	78°
MPA (Mean-32°)	31°	28°	28°
Occlusal Plane (Mean-14°)	8°	13°	9°
Upper Incisor-NA (Mean-22°)	-36°	39°	46°
Lower Incisor-NB (Mean-25°)	20°	27°	26°
Lower Incisor to Chin ( Mean 2-4 mm)	4mm	6mm	6mm
FMA (Mean-25°)	25°	22°	22°
FMIA (Mean-65°)	65°	62°	62°
IMPA (Mean-90°)	90°	96°	96°



Cephalometric tracing of post-treatment



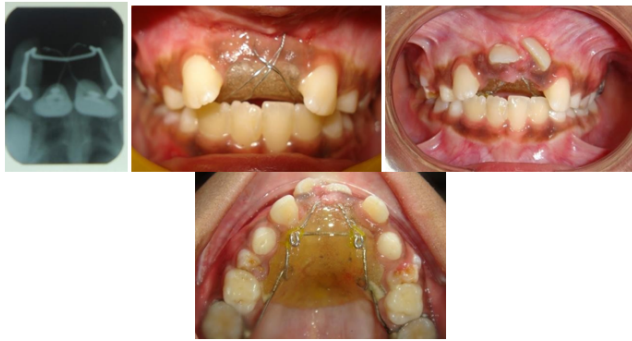Cephalometric tracing of post 10 years follow-up

prevent soft tissue injury was placed.<sup>7</sup>(Figure 9).

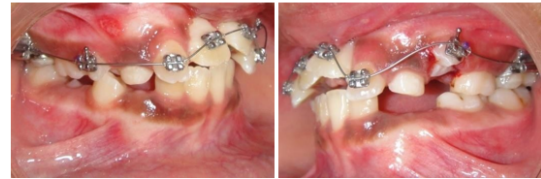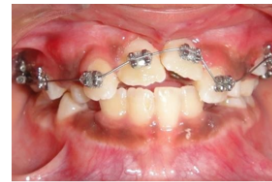#### 4. Treatment Planning and Progress

Class II elastics were used for settling the occlusion. (Figure 10). Once the desired occlusion was achieved then the debonding was done and fixed retainers were delivered to the patient. (Figure 11). The follow up of patient was done at regular intervals. Latest records collected at the stage of 10 years follow up. (Figure 12).<sup>8</sup>

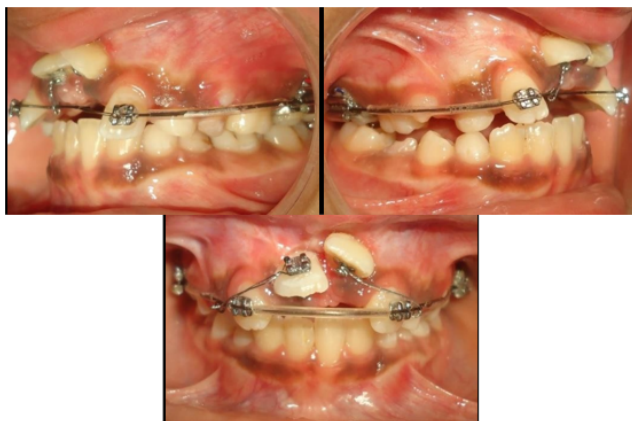



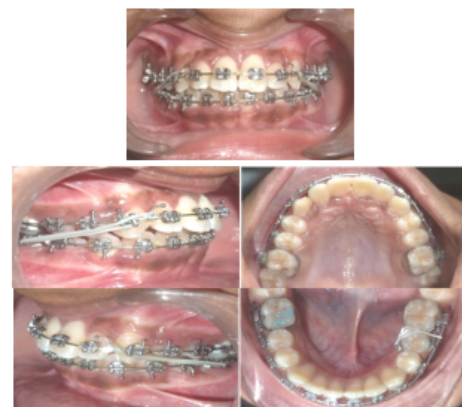**Figure 6:** Surgical exposure of central incisors and attachment of lingual buttons to the exposed crown of maxillary central incisors.



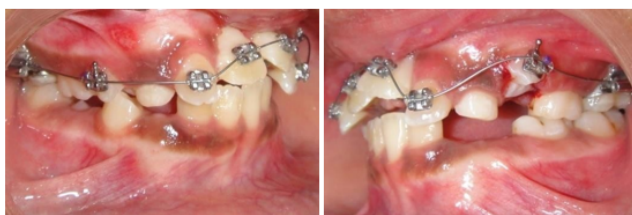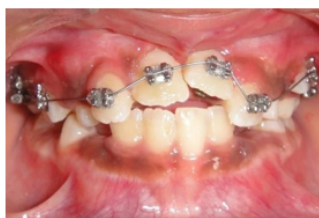**Figure 9:** Levelling and alignment of maxillary arch with 0.012 NiTi wire



**Figure 7:** Modified TPA in place with anterior hooks and anterior acrylic extension to prevent tissue injury from ligature wires



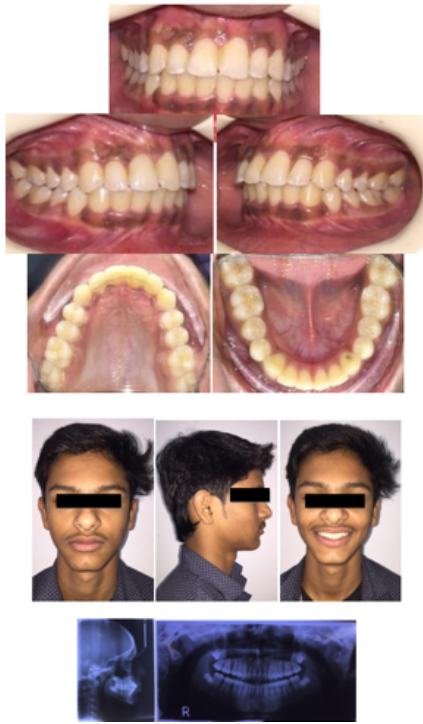**Figure 10:** Mid treatment intra-oral pictures and extra-oral pictures



**Figure 8:** Mid treatment intra-oral pictures after the eruption of maxillary incisors.

#### 4.1. Alternate treatment plan option-

1. Extraction of impacted teeth and replacement with dental implants.
2. Creation of space for impacted tooth, surgical crown exposure and orthodontic traction of the impacted central incisor.
3. Extraction of impacted central incisor and temporary restoration with removable prosthetic denture, followed by a permanent restoration with a bridge or an implant when growth ceases.
4. Extraction of impacted central incisor and closure of the space, converting the lateral incisor into central incisor with subsequent prosthetic restoration.



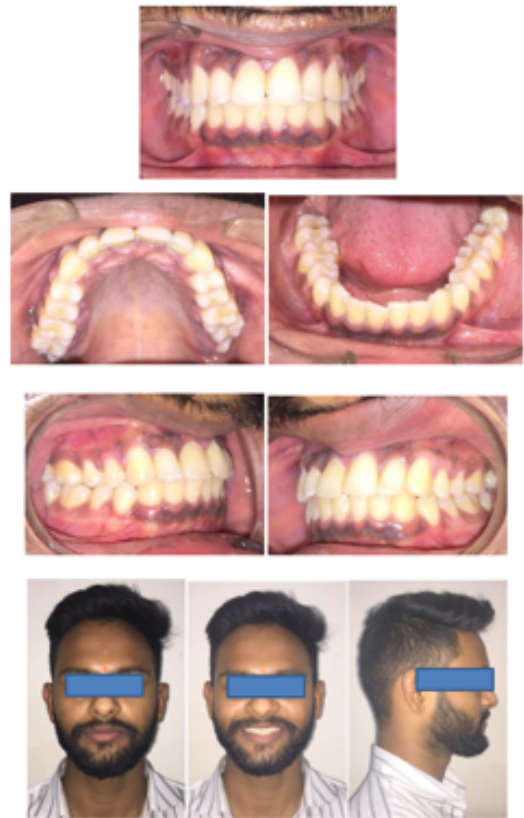**Figure 11:** Intra-oral and extra-oral photographs, OPG and Lateral Cephalogram after debonding.

**5. Discussion**

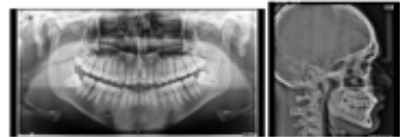Impacted maxillary permanent central incisor due to dilacerations is rarely seen and has serious impact on aesthetics, phonetics, mastication, and psychology in young patients. Orthodontic treatment of impacted and dilacerated maxillary anterior teeth is one of the most challenging task for orthodontists due to its limiting factor like position of the impacted tooth, degree of root completion, direction of impacted teeth, degree of dilacerations, and the presence of space for the impacted teeth. This case was challenging as both the maxillary central incisors had dilacerations and roots were deflected labially pushed to floor of nose, with crown root angulation nearing right angle. Limitation of this case was that ideal tip torque could not be achieved as there was fear of fenestration by dilacerated root. A ten-year follow-up of the stability and periodontal health showed that the tooth placed in the occlusion maintained both aesthetics and function. This case report thus establishes that dilacerated inverted teeth can be successfully aligned with early intervention and multidisciplinary approach without root resorption.

**6. Conclusion**

Bilateral impaction, dilacerations and internal deflection of both maxillary permanent central incisors is a relatively rare phenomenon but when present they pose a multitude



**Figure 12:** Intra-oral and extra-oral photographs, OPG and lateral cephalogram after 10 years follow up



**Figure 13:** Superimpositions of pre-treatment and post treatment cephalograms showing changes of incisal inclinations.

of diagnostic, prognostic, and management challenges. To reach a definitive diagnosis and improve treatment planning, the role of latest imaging tools such as CBCT is indispensable along with essential diagnostic aids. Treatment should commence as early as possible and comprises surgical exposure followed by orthodontic traction and tooth alignment in the dental arch. For successful management, a multidisciplinary approach and a high level of cooperation from the patient are required.

### 7. Source of Funding

None.

### 8. Conflict of Interest

None.


### References

1. Grover PS, Lorton L. The incidence of unerupted permanent teeth and related clinical cases. *Oral Surg Oral Med Oral Pathol.* 1985;59(4):420–5.
2. Andreasen JO. Textbook and color atlas of traumatic injuries to the teeth. Andreasen JO, Andreasen F, editors. Copenhagen: Munksgaard; 1985. p. 457–94.
3. Moss JP. An orthodontic approach to surgical problems. *Am J Orthod.* 1975;63:363–90.
4. Levin MP, and DA. Flap design in exposing unerupted teeth. *Am J Orthod.* 1974;65:419–41.
5. Brin I, Zilberman Y, Azaz B. The unerupted maxillary central incisor: Review of its etiology and treatment. *ASDC J Dent Child.* 1982;49:352–9.
6. Lin YT. Treatment of an impacted dilacerated maxillary central incisor. *Am J Orthod Dentofac Orthop.* 1999;115(4):406–15.
7. Wasserstein A, Tzur B, Brezniak N. Incomplete canine transposition and maxillary central incisor impaction a case report. *Am J Orthod Dentofac Orthop.* 1997;111:635–44.
8. Kolokithas G, Karakasis D. Orthodontic movement of dilacerated maxillary central incisor. *Am J Orthod.* 1979;76:310.

### Author biography

**Param Makhija**, Professor

**Mukesh Gupta**, Professor

**Kratika Mishra**, Associate Professor  <https://orcid.org/0000-0001-8345-5681>

**Cite this article:** Makhija P, Gupta M, Mishra K. Treatment of a challenging case of impacted, severely dilacerated & deflected maxillary central incisors: A case report with 10 years follow up. *J Contemp Orthod* 2024;8(2):228-233.