



Case Report

Revolutionizing orthodontics: Effective management of Class III skeletal malocclusion using innovative buccal shelf bone screws

Vighanesh Vijay Kadam^{1*}, Hrushikesh Aphale¹, Sunil Kumar Nagmode¹

¹D.Y Patil Dental College and Hospital, Navi Mumbai, Maharashtra, India



ARTICLE INFO

Article history:

Received 11-03-2024

Accepted 05-06-2024

Available online 27-08-2024

Keywords:

Extra-alveolar bone screws

TAD

biomechanics

Anchorage

Lower arch distalization

ABSTRACT

Introduction: The advent of the temporary anchorage devices has revised the envelope of discrepancy in modern orthodontic practice. Orthodontic camouflage is opted in situations where the patient is reluctant to have an invasive orthognathic surgical procedure and the associated risks or where, by the use of temporary anchorage devices, the orthodontic envelope can be expanded, and optimal orthodontic result can be obtained non surgically. In such cases, TAD's can be used to obtain an acceptable orthodontic result with a cusp to fossa posterior relation, an optimal aesthetic outcome, and a functional occlusion. This case report showcases a camouflage treatment of a Class III non-growing patient treated by use of TAD's, to cause clockwise rotation of maxillo- mandibular occlusal complex for achieving optimum molar relation, facial esthetics, and function.

Case Report : A case of skeletal and Angle's Class III malocclusion is presented where orthodontic camouflage was carried out to deliver optimal orthodontic results. This was achieved effectively by in toto distalization of the lower arch. This was brought about with the use of two extra alveolar TAD's placed in the buccal shelf region of the lower arch. Two 2 x 12 mm bone screws were used, after space creation by extraction of lower third molars bilaterally, and elastic chains was the chosen force delivery system. Here in toto distalization of the lower arch was achieved to end in an Angle's class I molar and canine relationship with normal overjet and overbite. Total treatment duration was of 17 months.

Conclusion : Challenging skeletal malocclusions can be treated non surgically by effective use of TAD's and correct and efficient use of biomechanics.

This is an Open Access (OA) journal, and articles are distributed under the terms of the [Creative Commons Attribution-NonCommercial 4.0 International](https://creativecommons.org/licenses/by-nc/4.0/), which allows others to remix, and build upon the work non-commercially, as long as appropriate credit is given and the new creations are licensed under the identical terms.

For reprints contact: reprint@ipinnovative.com

1. Introduction

In the Asian ethnic groups, the prevalence of Class III malocclusions is the greatest compared to other sagittal malocclusions. These patients along with the skeletal discrepancy show dentoalveolar, functional and also vertical, and transverse deviations which complicate the treatment planning.¹ The main reason why these patients seek orthodontic treatment is compromised facial aesthetics and functions. Skeletal Class III malocclusions are the most difficult malocclusions to treat particularly because of the

unfavorable growth pattern of the mandible and associated with the dental compensations.¹ Many of these cases require orthopedic correction during the growing phase in children and for the non-growing patients orthognathic surgery is required for the best treatment outcome. The ideal treatment in adult patients is orthognathic surgery, which many patients refuse due to the invasive nature of the procedure.²⁻⁴

Expanding the conventional envelope of discrepancy, in some skeletal malocclusions, orthodontic camouflage may be considered to achieve appropriate occlusion, which would improve aesthetics and optimum function.⁵ The objective of the orthodontic camouflage involves the

* Corresponding author.

E-mail address: vighaneshkadam99@gmail.com (V. V. Kadam).

uprighting of the maxillary & mandibular anteriors on their respective jaw bases, sometimes needing selective extractions. Another alternative method for orthodontic camouflage in skeletal CI III is by en-masse distalization of mandibular dentition.⁵

Before the advent of skeletal anchorage, distalization of the lower arch was difficult to achieve, time consuming and involved complicated appliances which were many times not accepted by the patient. Conventionally, individual molar distalization was done, followed by retraction of remaining teeth into gained space. However, with the advent of TAD's and increasing use of extra alveolar TAD's, it is now possible to distalize the lower arch en masse, without the use of complicate appliances or difficult biomechanics. This method is gaining rapid popularity as it is easy to perform, shortens the treatment time and is relatively more patient friendly.

2. Case Report

A 19 year old adult patient reported with a chief complaint of forwardly placed lower front teeth. He presented with a hypodivergent skeletal CI III pattern with a prognathic mandible which was complicated by a negative overjet of 2 mm and asymmetric molar relation of full cusp angles CI III molar relation on the right side and a half cusp CI III molar relation on the left side. The general extra oral and intra oral features are summarised in Table 1 and Table 2.

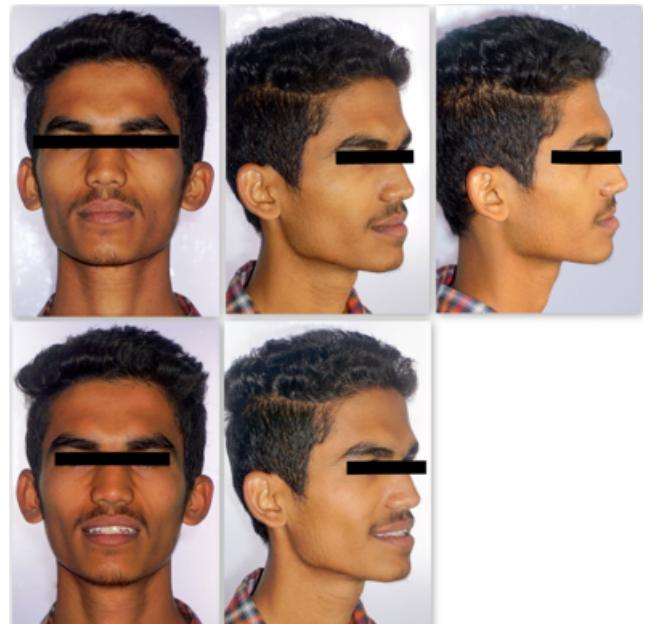

Figure 2:

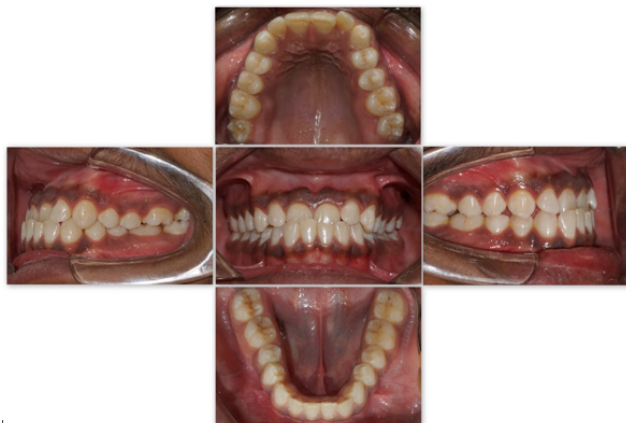

Figure 1:

The pre-treatment images (Figures 1, 2, 3 and 4).

3. Treatment Objectives

The treatment objectives of the case are summarised in the table 3.

3.1. Treatment plan

Keeping the mentioned treatment objectives in view, a treatment plan of orthodontic camouflage was devised. An

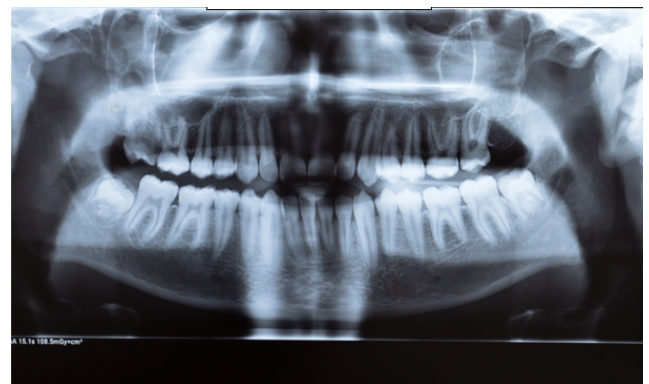

Figure 3:

asymmetric en masse distalization was planned to end in a CI I molar relation bilaterally. The anchorage was gained using extra alveolar TAD's placed in the buccal shelf area of the lower jaw bilaterally. An asymmetric molar relation dictated an asymmetric setback of the lower dentition. A posterior acrylic bite plate was used to facilitate no anterior tooth contact while en masse distalization in both the lower quadrants.

Alignment and levelling were done in the upper arch. Here a couple force was used with the help of a transpalatal arch to achieve the denotation of the second molar and to correct its overhanging palatal cusp. The upper and lower midlines were matched to the facial midline facilitated by asymmetric lower arch distalization (the third molars to be extracted and available space distal to the 2nd molars). The case finished with Class I molar and canine relationship bilaterally, dental midlines matching the facial midline,

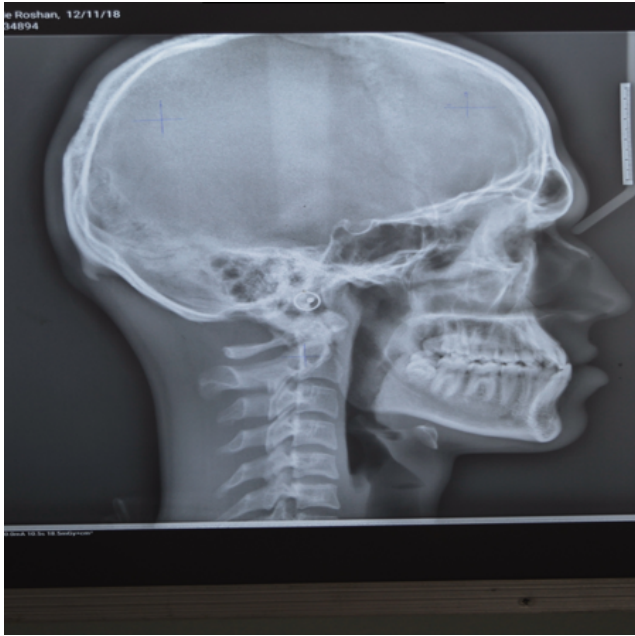

Figure 4:

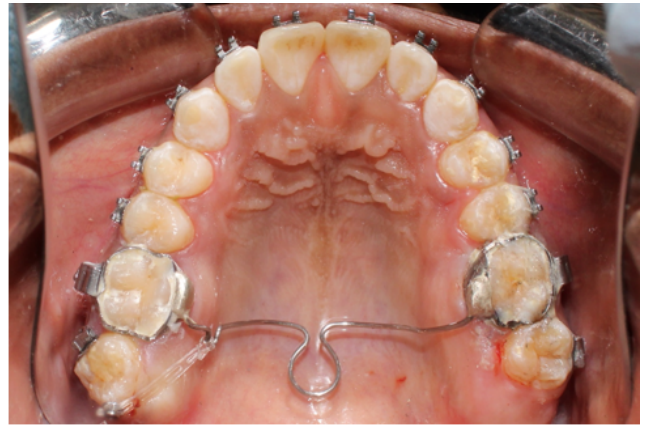

Figure 6:

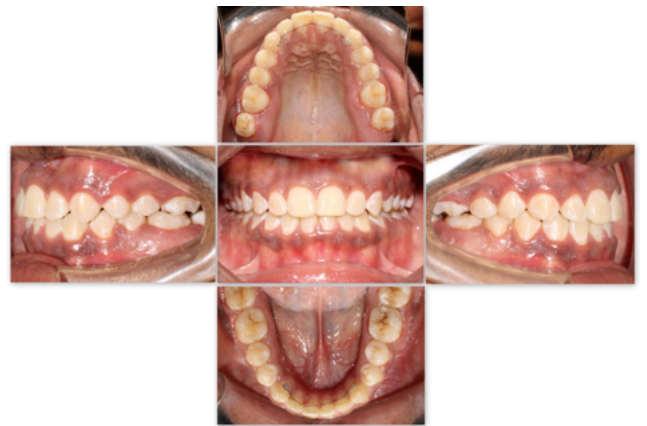

Figure 7:

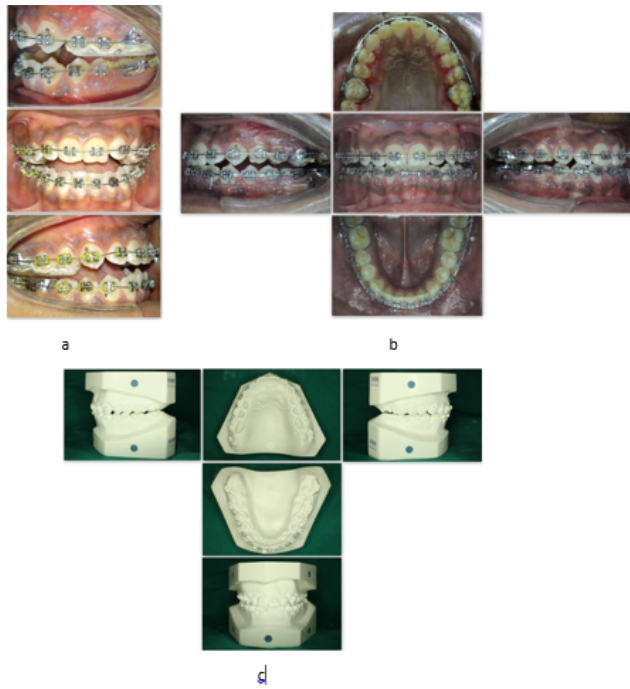


Figure 5:

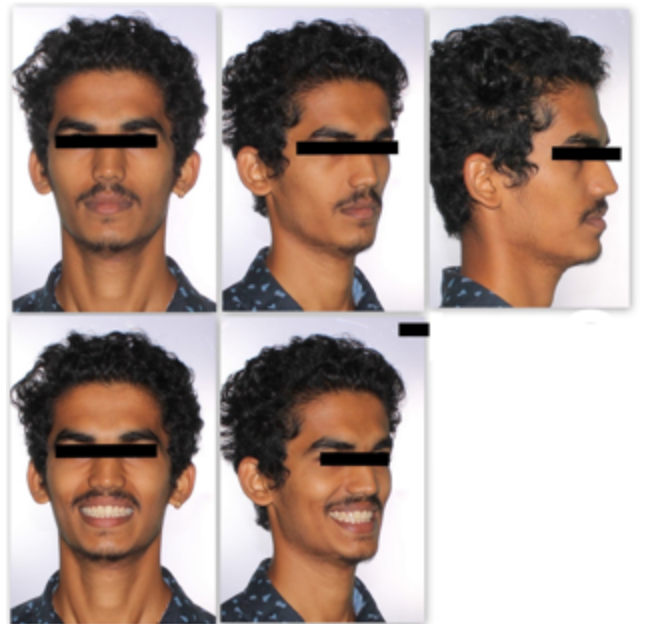

Figure 8:

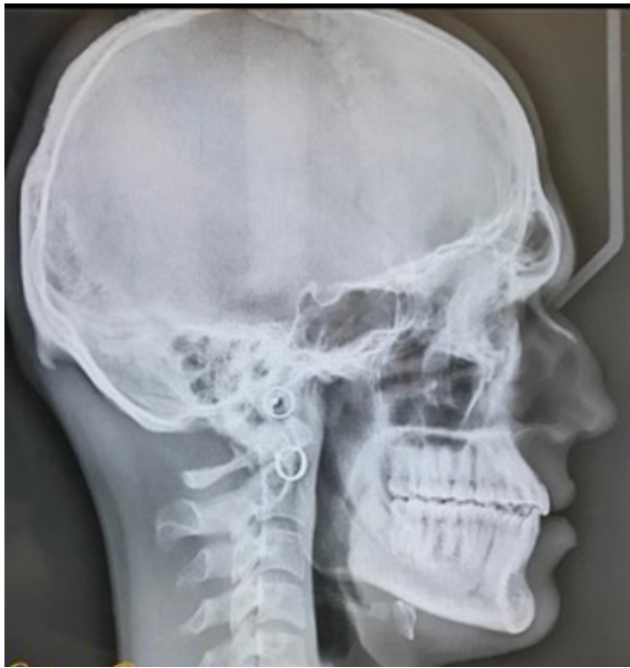

Figure 9:

ideal overjet, ideal overbite, and correction of protrusive soft-tissue profile.

3.2. Treatment progress

The treatment sequence and biomechanics are summarized in Table 4. The bite plate is utilized for relieving the anterior crossbite, Figure 5 A.

Figure 5 B illustrates the mandibular arch distalization with the buccal shelf implants.

The mechanics for the correction of the rotations of the maxillary second molars are illustrated in Figure 6.

The post-completion of the treatment is seen in Figures 7, 8 and 9.

4. Results

The case was finished with Angle’s Class I molar relationship along with Class I canine relation. The incisor relationship with normal overjet and overbite of 2 mm was achieved. The upper and lower dental midlines matched at the end of the treatment. All displacements and crossbites were corrected by the end of the treatment. No occlusal wear facets were noted with mutually protected occlusion and canine-guided excursive movements established. A consonant smile arc was achieved, and smile esthetics was significantly improved along with the facial profile.

Cephalometric changes – The Cephalometric changes along with the pre-treatment cephalometric values (Table 5) and post-treatment cephalometric values (Table 6) are mentioned in the.

Table 1:

Chief complaint	Forwardly placed lower front teeth.
Examination	Extra-oral Hypodivergent face pattern Obtuse nasolabial angle Anterior divergent face Positive lip step Everted lower lip Shallow mento-labial sulcus Intra-oral Angle’s Class III molar relationship Canine relation Class III on the right aspect and Class I on the left aspect Reverse overjet of 2mm Crowding in the upper arch Maxillary dental midline shift towards right Disto-buccal rotation with 17 and 27 Ellis Class I fracture with maxillary central incisors
Radiographic findings	Orthopantomogram Impacted mandibular third molars

Table 2:

Parameter	Readings
SNA	86°
	87°
ANB	-1
WIT’S APPRAISAL	-5mm
GoGN-SN plane	19°
FMA	17°
Y-axis	59°
U1-NA line (angle)	34°
U1-NA line (linear)	5mm
L1-NB line (angle)	22°
L1-NB line (linear)	4mm
L1-A-Pog line	4mm
IMPA	94°
S line to upper lip	-1mm
S line to lower lip	5mm
Cephalometric Summary:	
<ul style="list-style-type: none"> • Skeletal Class III jaw base with horizontal growth pattern. • Proclined upper incisors. • Retroclined and forwardly placed lower incisors. • Protrusive lower lip. 	

5. Discussion

In the treatment of orthodontic camouflage in skeletal CI III malocclusions, counter clockwise rotation of the jaws is undesirable.^{6–8} This can be facilitated planning biomechanics where the vectors of force is as parallel to the lower occlusal plane as possible. Here in this case report, the correction is achieved by minimal clockwise rotation of the mandibular plane with the fixed appliance along with the buccal shelf bone screw in a Class III adult patient. The

Table 3:

Parameter	Normal values	Pre-treatment	Inference
		Maxilla to Cranium	
SNA	820	820	Orthognathic maxilla
N-Point A	0+/-2mm	-4mm	Backwardly placed maxilla
N-A(∟ HP)	0.0+/-3.7mm	2mm	Average
		Mandible to Cranium	
	800	870	Prognathic mandible
N-Pog	0 to -4 mm	-5mm	Backwardly positioned chin
N-B(∟ HP)	-5.3+/-6.7mm	5mm	Average
N-Pg(∟ HP)	-4.3+/-8.5mm	6mm	Average
Go-Gn to SN	320	190	Horizontal growth pattern
		Maxillary Teeth to Cranium	
NA to U1(Angle)	220	280	Proclined maxillary incisors
NA to U1(Linear)	4mm	4mm	Normally positioned incisors
U1 to NF(⊥ NF)	30.5+/-2.1mm	21mm	Decreased
U6 to NF(⊥ NF)	26.2+/-2mm	16mm	Decreased
U1 to SN	102+/-20	1230	Proclined maxillary incisors
U1 to ANS-PNS	70+/-50	600	Proclined maxillary incisors
		Mandibular teeth to cranium	
NB to L1	250	220	Upright lower incisors
NB to L1(mm)	4mm	4mm	Normally positioned incisors
L1 to A-Pog	1-2 mm	4mm	Protrusive incisors
IMPA	900	940	Proclined lower incisors
L1 to MP(⊥ MP)	45+/-2.1mm	32mm	Decreased
L6 to MP(⊥ MP)	35.8+/-2.9mm	27mm	Decreased
		Maxilla to Mandible	
Interincisal angle	1300	1110	Proclination of incisors
ANB	20	-50	Skeletal class III jaw base relationship
WITS appraisal	+1mm	-4mm	Skeletal class III jaw base relationship
		Vertical Relation	
Y-axis	660	590	Anterior positioning of mandible w.r.t cranial base
Facial axis angle	00	40	Horizontal growth pattern
J angle	850	920	Anticlockwise rotation of the maxilla
LAFH	45+/-2	50mm	Average
Basal plane angle	250	220	Horizontal growth pattern
Facial height ratio	62-65%	68%	Horizontal growth pattern
FMA	250	230	Horizontal growth pattern
Gonial angle	128+/-70	1160	Horizontal growth pattern
		Soft tissue	
'S' line to upper lip	0mm	-1mm	Lies behind the s line
'S' line to lower lip	0mm	3mm	Lies ahead of the s line
Nasolabial angle	900-1000	880	Acute

Table 4:

Treatment Objectives			
Dimension	Skeletal	Dental	Soft tissue
Anteroposterior	-	To achieve ideal overjet To achieve Angle's Class III molar relationship	To achieve ideal lip position
Transverse		To achieve Class I canine relationship To achieve ideal alignment in the upper and lower arches To correct the dental midline discrepancy.	-
Vertical	Open up the mandibular plane and increase the lower anterior facial height as a resultant to distalization of upper arch (wedge effect)	Establish ideal overbite	-
Other	-	Resin based restoration with 11 and 21. Disimpaction with the mandibular third molars	

Table 5:

Treatment sequence and biomechanical plan	
Maxilla	Mandible
Bonding with maxillary arch (MBT 0.022"slot) along with cemented posterior biteplate. Leveling and alignment with 0.014, 0.016, 0.016×0.022 Niti wires. Followed by 0.017 x 0.025" SS and 0.019 x 0.025" SS.	Bonding with mandibular arch (MBT 0.022"slot) Leveling and alignment with 0.014, 0.016, 0.016×0.022 Niti wires. Followed by 0.017 x 0.025" SS and 0.019 x 0.025" SS.
The bite plate was removed adequate overjet observed. The maxillary second molars were bonded, and de-rotations was done with round 0.014" Niti wire and elastics from modified TPA. The consolidation of the arch was done with the continuous ligature wire, and 0.012 Niti wire was placed for the settling process. For retention fixed lingual bonded retainers along with Hawley's retainers. Pericision was done for the corrected rotations of the maxillary second molars. Ellis Class I fractures of the central incisors were restored with resin based esthetic cements.	Buccal shelf orthodontic bone screws of 12 mm length placed in the right lower buccal shelf region and immediate loading done with e-chain delivering a force of about 300 G for asymmetrical retraction of the right buccal segment to correct the dental midline and develop adequate overjet. Bilateral placement of forces was to avoid the cant of occlusal plane. Full arch distalization was continued on the right side till Class I molar and canine relation was attained. The archwire was periodically checked for transverse co-ordination of arches. Post distalization and space closure - consolidation of arch was done, and the same 0.019×0.025 SS wire was kept for extended period to aid in ideal root parallelism Postdistalization and space closure - consolidation of arch was done, and the same 0.019×0.025 SS wire was kept for extended period of two months. For retention fixed lingual bonded retainers along with Hawley's retainers.

Table 6:

Parameter	Normal values	Current	Inference
		Maxilla to Cranium	
SNA	820	820	Orthognathic maxilla
N-Point A	0+/-2mm	-4mm	Backwardly placed maxilla
N-A(∟ HP)	0.0+/-3.7mm	1mm	Average
		Mandible to Cranium	
N-Pog	800	860	Prognathic mandible
N-B(∟ HP)	0 to -4 mm	-4mm	Backwardly positioned chin
N-Pg(∟ HP)	-5.3+/-6.7mm	4mm	Average
Go-Gn to SN	-4.3+/-8.5mm	6mm	Average
	320	200	Horizontal growth pattern
		Maxillary Teeth to Cranium	
NA to U1(Angle)	220	300	Proclined maxillary incisors
NA to U1(Linear)	4mm	4mm	Normally positioned incisors
U1 to NF(∟ NF)	30.5+/-2.1mm	21mm	Decreased
U6 to NF(∟ NF)	26.2+/-2mm	17mm	Decreased
U1 to SN	102+/-20	1250	Proclined maxillary incisors
U1 to ANS-PNS	70+/-50	580	Proclined maxillary incisors
		Mandibular Teeth to Cranium	
NB to L1	250	200	Upright lower incisors
NB to L1(mm)	4mm	3mm	Normally positioned incisors
L1 to A-Pog	1-2 mm	3mm	Forwardly positioned incisors
IMPA	900	910	Normally positioned lower incisors
L1 to MP(∟ MP)	45+/-2.1mm	32mm	Decreased
L6 to MP(∟ MP)	35.8+/-2.9mm	27mm	Decreased
		Maxilla to Mandible	
Interincisal angle	1300	1150	Proclination of incisors
ANB	20	-40	Skeletal class III jaw base relationship
WITS appraisal	+1mm	-3mm	Skeletal class III jaw base relationship
		Vertical Relation	
Y-axis	660	600	Anterior positioning of mandible w.r.t cranial base
Facial axis angle	00	+30	Deficient vertical development of the face
J angle	850	920	Anticlockwise rotation of the maxilla
LAFH	45+/-2	52 mm	Average
Basal plane angle	250	240	Horizontal growth pattern
Facial height ratio	62-65%	67%	Horizontal growth pattern
FMA	250	240	Horizontal growth pattern
Gonial angle	128+/-70	1170	Horizontal growth pattern
		Soft Tissue	
'S' line to upper lip	0mm	-1mm	Lies behind the s line
'S' line to lower lip	0mm	0mm	Lies over the s line
Nasolabial angle	900-1000	880	Acute

severity of the skeletal discrepancy, degree of the incisor compensations, facial growth pattern, periodontal status, anterior facial proportions, and aesthetic appearance of the patient are the important factors to be considered during planning the biomechanics of a skeletal CI III case where orthodontic camouflage is desired.^{9–13}

There have been various studies that determine which cases of skeletal Class III malocclusion can be treated by orthodontic camouflage by enlarging the envelope of discrepancy.^{14–19} In general it is hypothesized that surgery is ideally indicated when the ANB angle is more than -5 degrees, and the Wits appraisal shows mandibular prognathism more than 5mm. In the present case report, the ANB angle was - 5 degrees, IMPA was 94 degrees, and the Wits appraisal was -5mm. This made the present case a borderline case and as the patient did not agree to a surgical treatment plan, orthodontic camouflage was planned by asymmetric en masse distalization of the lower arch.

The patient also showed some functional forward shift of the mandible, which can be observed in many cases of CI III with an anterior cross bite due to occlusal interferences. Orthodontic camouflage in many Class III cases addresses the sagittal problems, but seldom on the improvement of vertical deficiency.^{20–24} The extrusion of the maxillary anteriors was planned to improve the incisor visibility and smile arc as reported in a few can reports published.²⁴ The clockwise rotation of the occlusal plane was advantageous in improving smile arc as proposed by Eric Liou et al.⁹ Posterior bite plate was used on the upper posteriors to open the bite while the reverse overjet was corrected. After achieving a positive overjet, the posterior bite plate was discontinued. Two buccal shelf bone screws (2x12mm) were placed in the third and fourth quadrants. A parallel force vector was used. Asymmetric mandibular dentition distalization was desired which was more on the right side to correct a full cusp CI III molar relation to a CI I molar relation. On the left side the amount of distalization was limited to correct a half cusp CI III to a CI I molar relation. The distalization force was stopped after achieving CI I molar relation bilaterally. The goal of achieving a functional mutually protected occlusion with cuspid rise was achieved.

5.1. Critical appraisal

Although the results from an orthodontic point of view look satisfactory, as a new modality of treatment, a long-term follow-up will determine the success achieved. All the aesthetic and functional goals were achieved and a stable posterior occlusion with symmetric cusp to fossa relation was established bilaterally. The case selection, the biomechanics, and the appreciation of the anatomic limitations would remain as some of the important perspectives for achieving the final objective.

6. Conclusion

The primary objective of any new clinical protocol is to enhance treatment quality by incorporating precision, expanding treatment horizons, and to make the treatment more acceptable to the patient.

By employing extra radicular bone screws in distalization techniques, with careful biomechanical consideration, we can effectively address emerging challenges and surpass limitations, ultimately striving for the pinnacle of the ever eluding clinical excellence.

7. Patient Consent Declaration

The author affirms that all appropriate patient consent forms have been obtained. The patients have willingly given their consent for the usage of their images and other clinical information in the journal. The patients are aware that their names and initials will not be disclosed, and utmost efforts will be taken to protect their identity. However, complete anonymity cannot be guaranteed.

8. Source of Funding

None.

9. Conflict of Interest

None.

References

- Venugopal A, Manzano P, Vaid N. TAD driven Class III camouflage: Eight point protocol to optimize efficiency, aesthetics and stability. *Sem Orthod.* 2022;28(2):164–94.
- Bittencourtma. Early treatment of patient with Class III skeletal and dental patterns. *Dental Press J Orthod.* 2015;20(6):97–109.
- Kama JD, Ozer T, Baran S. Orthodontic and orthopaedic changes associated with treatment in subjects with Class III malocclusions. *Eur J Orthod.* 2006;28(5):496–502.
- Park JH, Emamy M, Lee SH. Adult skeletal class III correction with camouflage orthodontic treatment. *Am J Orthod Dentofac Orthop.* 2019;156(6):858–69.
- Troy BA, Shanker S, Fields HW, Vig K, Johnston W. Comparison of incisor inclination in patients with Class III malocclusion treated with orthognathic surgery or orthodontic camouflage. *Am J Orthod Dentofac Orthop.* 2009;135(2):146–53.
- Baik HS. Limitations in orthopaedic and camouflage treatment for Class III malocclusion;. *Sem Orthod.* 2007;13:158–74.
- Reyneke R, Bryant R, Suuronen PJ. Post operative skeletal stability following clockwise and counterclockwise rotation complex compared with conventional orthognathic treatment. *Br J Oral Maxfac Surg.* 2007;45(1):56–64.
- Tsai IM, Lin CH, Wang YC. Correction of skeletal class III malocclusion with clockwise rotation of the maxillomandibular complex. *Am J Orthod Dentofac Orthop.* 2012;141(2):219–65.
- Eric JW, Liou YC. Orthodontic clockwise rotation of maxillomandibular complex for improving facial profile in late teenagers with Class III malocclusion: A preliminary report. *APOS Trends Orthod.* 2018;8(1):3–9.
- Worms FW, Isaacson RJ, Spiedel RM. Teuscher U. An appraisal of growth and reaction to extra oral anchorage. *Angle Orthod.* 1973;43(2):113–134.

11. Baik HS, Han HK, Kim DJ, Proffit W. Cephalometric characteristics of Korean Class III surgical patients and their relationship to plans for surgical treatment. *Int Adult Orthod Orthognath Surg.* 2000;15(2):119–47.
12. Baikhs. Limitations of Orthopedic Treatment and Combined Surgery in Skeletal Class III Malocclusion. Orthodontics in the 21st Century. Osaka, Japan, Osaka: University Press; 2002.
13. Kerr WJS. Class III malocclusions: Surgery or Orthodontics. *Br J Orthod.* 1992;19(1):21–5.
14. Eisenhauer AS, Lux CJ, Schuster G. Treatment decision in adult patients with Class III malocclusion: orthodontic therapy or orthognathic surgery? *Am J Orthod Dentofac Orthop.* 2002;122(1):27–38.
15. Chung KR, Kim SH, Kook YA. C-orthodontic microimplant for distalization of mandibular dentition in Class III correction. *Angle Orthod.* 2005;75(1):119–66.
16. Burns NR, Musich DR, Martin C, Razmus T, Gunel E, Ngan P. Class III camouflage treatment: What are the limits? *Am J Orthod Dentofac.* 2010;137(9):1–9.
17. Tekalepd V. Orthodonticcamouflageinskeletal class III malocclusion: A contemporary review. *J Orofac Res.* 2014;4(2):98–102.
18. Kwon EY, Lee JY, Choi J. Effect of slow forced eruption on the vertical levels of the interproximal bone and papilla and the width of the alveolar ridge. *Korean J Orthod.* 2016;46(6):379–85.
19. Chang C, Liu SS, Roberts WE. Primary failure rate for 1680 extra-alveolar mandibular buccal shelf mini-screws placed in movable mucosa or attached gingiva. *Angle Orthod.* 2015;85:905–915.
20. Chang CH, Lin JS, Roberts WE. Failure rates for stainless steel versus titanium alloy infrazygomatic crest bone screws: A single-center, randomized double-blind clinical trial. *Angle Orthod.* 2018;89(1):40–6.
21. Papageorgiou SN, Zogakis IP, Papadopoulos MA. Failure rates and associated risk factors of orthodontic miniscrew implants: A meta-analysis. *Am J Orthod Dentofac Orthop.* 2012;142:577–95.
22. Lin J, Roberts E. CBCT imaging to diagnose and correct the failure of maxillary arch retraction with IZC screw anchorage. *Int J. Orthop Impl.* 2014;35:4–17.
23. Deshmukh SV, Vadera KJ. Nonextraction treatment with en-masse distalization of maxillary dentition using miniscrews. *J Indian Orthod Soc.* 2018;52:204–13.
24. Kim SJ, Choi TH, Baik HS, Park YC, Lee KJ. Mandibular posterior anatomic limit for molar distalization. *Am J Orthod Dentofac Orthop.* 2014;146(2):190–7.

Author biography

Vighanesh Vijay Kadam, Lecturer  <https://orcid.org/0000-0002-6979-8060>

Hrushikesh Aphale, Professor

Sunil Kumar Nagmode, Professor

Cite this article: Kadam VV, Aphale H, Nagmode SK. Revolutionizing orthodontics: Effective management of Class III skeletal malocclusion using innovative buccal shelf bone screws. *J Contemp Orthod* 2024;8(3):380-388.