



Case Report

Complete transposition of mandibular lateral incisor–canine (Mn.I2.C): A rare clinical case

Lucky Yadav^{1*}, Akanksha Jaswal², Renuka Bamal³, Ashish Kumar⁴

¹Dept. of Orthodontics and Dentofacial Orthopaedics, Lady Hardinge Medical College and Hospitals, New Delhi, India

²Dept. of Orthodontics and Dentofacial Orthopaedics, Mahatma Gandhi Dental College and Hospital, Jaipur, Rajasthan, India

³Dept. of Orthodontics and Dentofacial Orthopaedics, NIMS Dental College, Rajasthan, India

⁴Dept. of Orthodontics and Dentofacial Orthopaedics, Rajasthan Dental College and Hospital, Jaipur, Rajasthan, India

ARTICLE INFO

Article history:

Received 25-05-2022

Accepted 23-07-2022

Available online 13-09-2022

Keywords:

Radiographic
Transposition
Cephalometric

ABSTRACT

A permanent tooth that grows and emerges from the same location of the dental arch as the other permanent teeth is a rare event. Unilateral transposition has been reported more often than bilateral transposition, with the left side of the body being affected more frequently than the right. With a frequency rate of 0.03 percent, the Mn.I2.C transposition is the rarest of all transpositions. In this unusual case report on a mandibular lateral incisor-canine transposition, dento-alveolar concerns such as arch length discrepancy and tooth material differences are addressed (Mn.I2.C).

This is an Open Access (OA) journal, and articles are distributed under the terms of the [Creative Commons Attribution-NonCommercial 4.0 International](https://creativecommons.org/licenses/by-nc/4.0/), which allows others to remix, and build upon the work non-commercially, as long as appropriate credit is given and the new creations are licensed under the identical terms.

For reprints contact: reprint@ipinnovative.com

1. Introduction

It's a rare kind of ectopic eruption in which a permanent tooth develops in the same quadrant of the dental arch as other permanent teeth that have already appeared. Even though they are rare, tooth transpositions could be either full or partial.^{1,2} The difference between the two is that in a full transposition situation, both the crowns and roots of the affected teeth are transposed, while in an incomplete transposition scenario, only the crowns are transposed and the root apices remain in their initial locations.³

According to different authors prevalence varies region to region but less than (<1%) overall. In India, it was 0.43 percent, 0.38 percent in Turkey, and 0.13 percent in Saudi Arabia. In the Indian population, transposition affects the maxillary dentition (68.5 percent - 76 percent)⁴ making mandibular transposition a rare occurrence. Syndromic patients have a much greater prevalence of the disease. Patients with Down's syndrome have a 14.29 percent tooth

transposition rate, whereas those with a cleft palate have a 4.1 percent tooth transposition incidence. According to most studies, women are more likely than males to have transposition of the maxilla, which is a unilateral condition affecting the left side of the face.

According to Peck and Peck,⁵ transpositions are characterized as one of the following:

1. Maxillary canine-first premolar (Mx C P1)
2. Maxillary canine-lateral incisor (Mx C I2)
3. Maxillary canine to first molar site (Mx C to M1)
4. Maxillary lateral incisor-central incisor (Mx I2 I1)
5. Maxillary canine to central incisor site (Mx C to I1)
6. Mandibular lateral incisor-canine (Mn I2 C)⁶

According to Peck et al., the canine and lateral incisors are involved in 20% of maxillary arch transpositions, whereas the canine and first premolar are involved in 71%.⁵ In rare cases, maxillary lateral and central incisors may be swapped, as well as the canine and central incisors. Mn.I2.C transpositions are exceptionally rare, occurring in only 0.03

* Corresponding author.

E-mail address: drluckyyadav4170@gmail.com (L. Yadav).

percent of cases of transposition.^{4,5,7,8} A case study of a mandibular left lateral incisor-canine complete transposition with anterior crowding and its orthodontic treatment will be described here.

2. Case Report

A 14 year old female came to Department of Orthodontics and Dentofacial Orthopaedics, at Rajasthan Dental College and Hospital, Jaipur with major complain of unevenly placed upper and lower teeth. Her medical and dental histories were not significant. She had mesomorphic body type and athletic build. Extra-oral examination showed well proportioned face, convex facial profile, posterior divergence, competent lips and average nasolabial angle. Figure 1 (A-C) Intra-oral examination showed ‘u’ shaped maxillary and mandibular arches with anterior crowding, class I molar relationship, class II incisors with overjet 1mm and overbite 5 mm. Other significant findings were complete transposition of canine and lateral incisor in mandibular left region, scissor bite irt. 14, crossbite irt 24 and retroclined maxillary central incisors. Figure 1 (D-H)

Radiographic examination (OPG) Figure 1 (I) revealed complete transposition of 32-33 and erupting all third molars while lateral cephalometric revealed Figure 1 (J) skeletal class II base (WITS 5mm, ANB 3 degree) Tables 1, 2 and 3. In Model analysis Arch perimeter and caries analysis showed tooth material excess of 3mm and 7mm respectively, premolar basal arch width percentage was 41% (borderline case), overall Bolton’s ratio 91% and anterior ratio is 72.91%.

3. Treatment Plan and Progress

The extraction treatment plan was chosen after careful review of diagnostic information and consultations with physicians. Standard edgewise appliance (022”x028” slot) were opted for treatment progress. initially upper arch treatment started with protraction intrusion utility arch(0.016x0.022 SS) for correction of maxillary centrals proclination after banding maxillary first molars and bonding central incisors and a removable anterior bite plate was given for correction of deep bite , utility arch was activated for 4 months till the desired results were achieved. Figure 2 (A).

After which standard edgewise appliance was bonded on complete upper and lower arch with banded molar tubes and extraction of upper first premolars and lower laterals was done to address tooth material and arch length discrepancy. Leveling and alignment of both the arches was started with 0.014,0.016,0.18,0.016x0.022 and 0.019x0.025 NiTi and then 0.019x0.025 stainless steel. Figure 2 (B-D). After this canine retraction was started on 0.019x0.025 stainless steel with Nance palatal button in upper arch with the help of E-chains. after canine retraction was complete Figure 1 (E-

F) 0.019x0.025 stainless steel boot loop was Figure 1 (G-I) placed in upper arch for incisors retraction and post its completion remaining spaces were closed with continuous e-chains. Final finishing and detailing was done in the both the arches and after 18 months of treatment case was debonded and removable Hawley’s retainers were given. Good aesthetic results were achieved in harmony with hard and soft tissues. Figure 3 (A-K), Tables 1, 2 and 3.

4. Discussion

Transposition can occur in any tooth, according to the literature. Etiology of transposition is not completely known. Tooth bud displacement or deviation during tooth development, genetic exchange between teeth buds, mechanical interferences in the eruption, early loss or longer retention of deciduous teeth are among the possible reasons.²

There are various treatment modalities present for a transposed tooth depending on the case. Figure 4 Treatment of all transposition disorders has as its primary objective the correction of the position of transposed teeth, but a number of criteria, such as the age, occlusion, aesthetics, and treatment duration of the patient, should be considered in order to prevent harm to the teeth and their supporting structures. Interceptive or fixed orthodontic treatment can be used to correct teeth that have been transposed if they are detected early sufficient. An early repair can be made by removing a primary anterior tooth. Correction of teeth that have emerged in their transposed locations or whose roots are parallel is not preferred once they have been identified as transposed due to a recognized transposition. “Because of the mandible’s thick and compact bone, the teeth should be aligned in their transposed shapes or alternative treatment options might be considered.

Clinical examination and radiographic findings in the mandibular canine and lateral incisors help to diagnosis the full form of transposition in the present instance, making it a rare case with an incidence of 0.03 %. in this case extraction treatment was decided for the case depending on clinical expertise and records analysis and it resulted into better functional and esthetic results with stable occlusion.

5. Conclusion

In mainly mandibular transposition as in the case presented attempts to correct tooth order may lead to gingival recession with loss of periodontal attachment, prolonged treatment time, and root resorption. Because of bone density and limited labiolingual dimension of the alveolar process in the mandible, teeth are better kept in their transposed position in the mandibular arch. Early diagnosis in mixed dentition can result better outcomes with preventive and interceptive orthodontics.

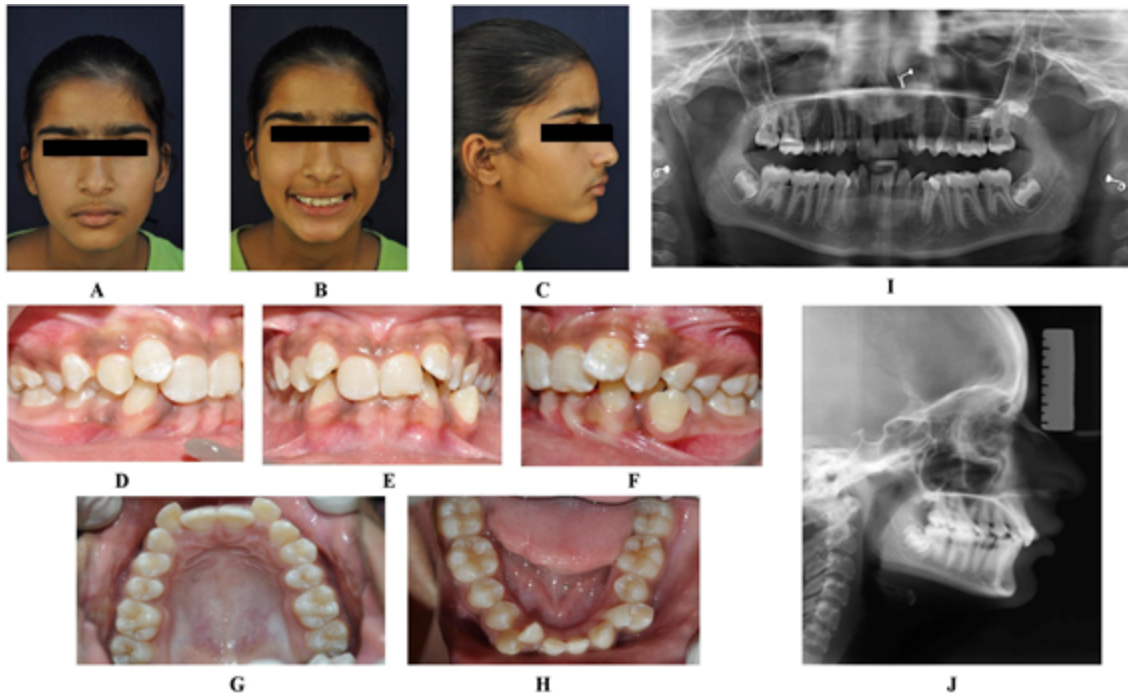


Figure 1: Pre-treatment extra-oral and intra-oral photographs (A-H); Orthopantomogram radiograph (I); Lateral cephalogram radiograph (J).

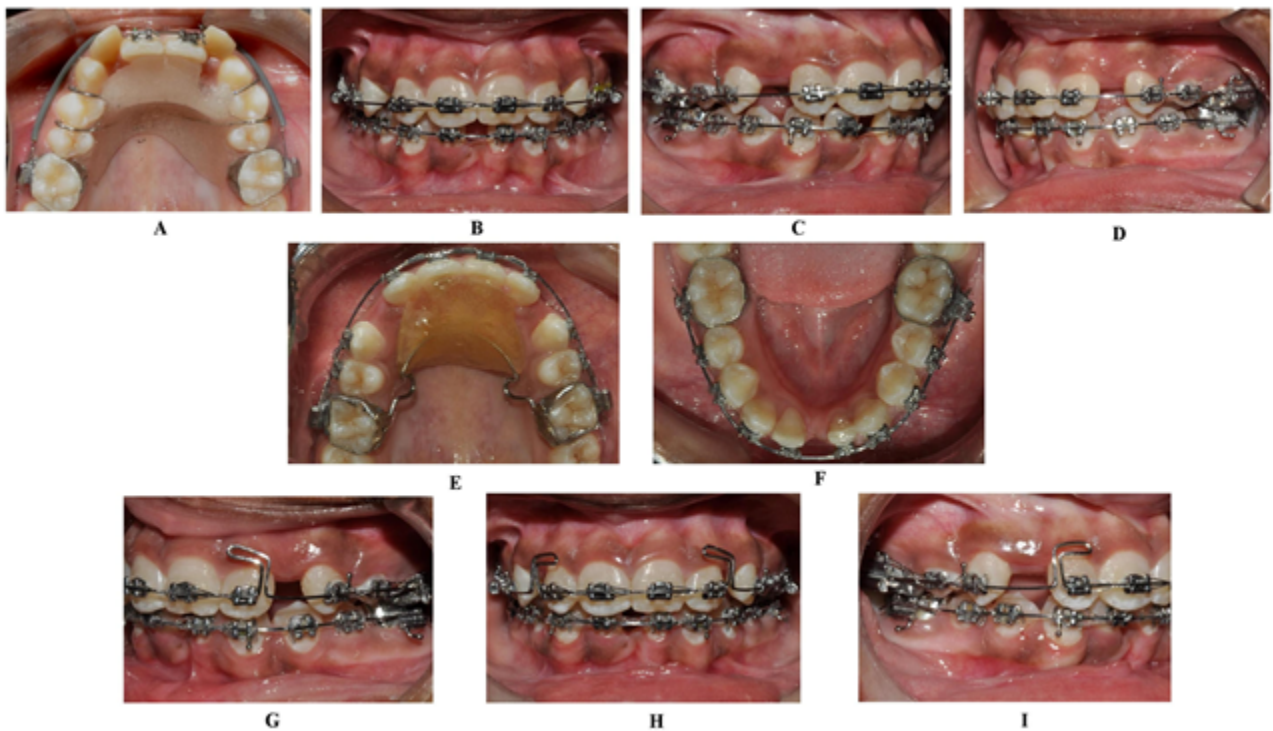


Figure 2: Intra-oral photographs; Protraction intrusion utility arch-stainless steel 0.016x0.022, removable anterior bite plate (A); mid treatment records post canine retraction with Nance's palatal button (B-F); incisor retraction with boot-loop mechanics-stainless steel 0.019x0.025 (G-I).

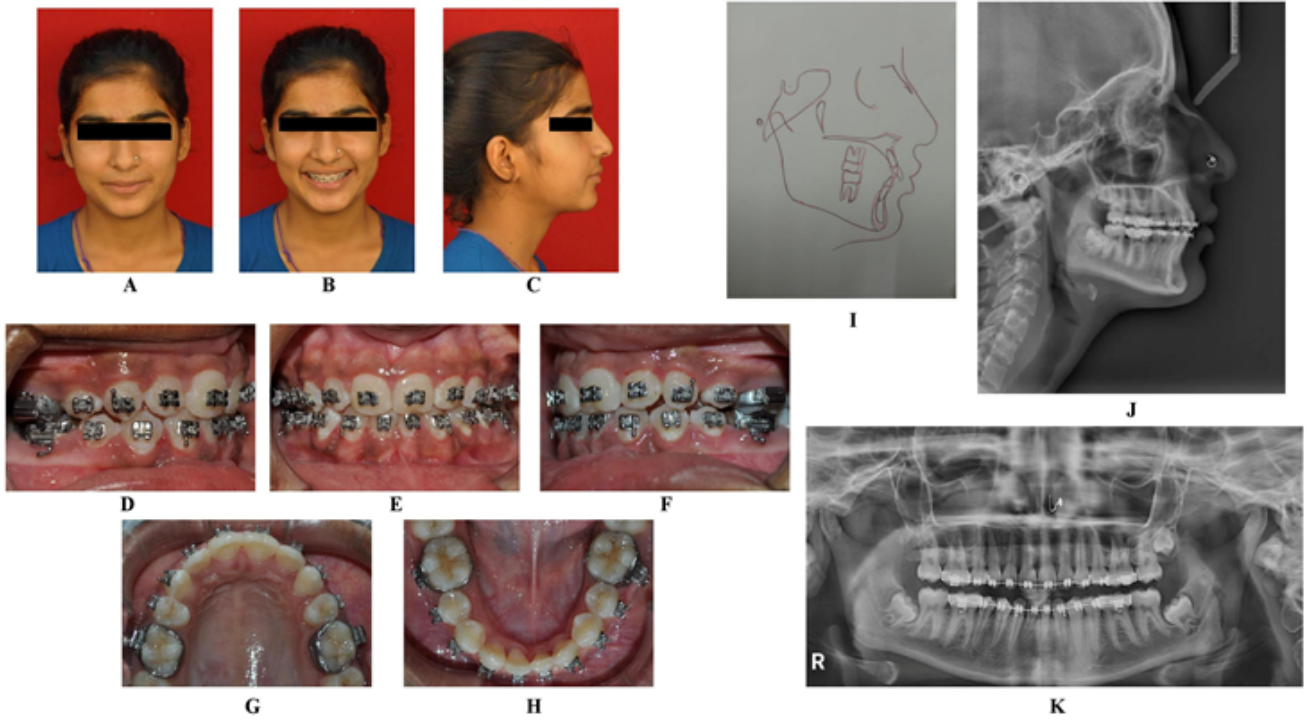


Figure 3: Post-treatment extra-oral and intra-oral photographs (A-H); Overall Steiner's superimposition (I); Lateral cephalogram radiograph (J) Orthopantomogram radiograph (K).

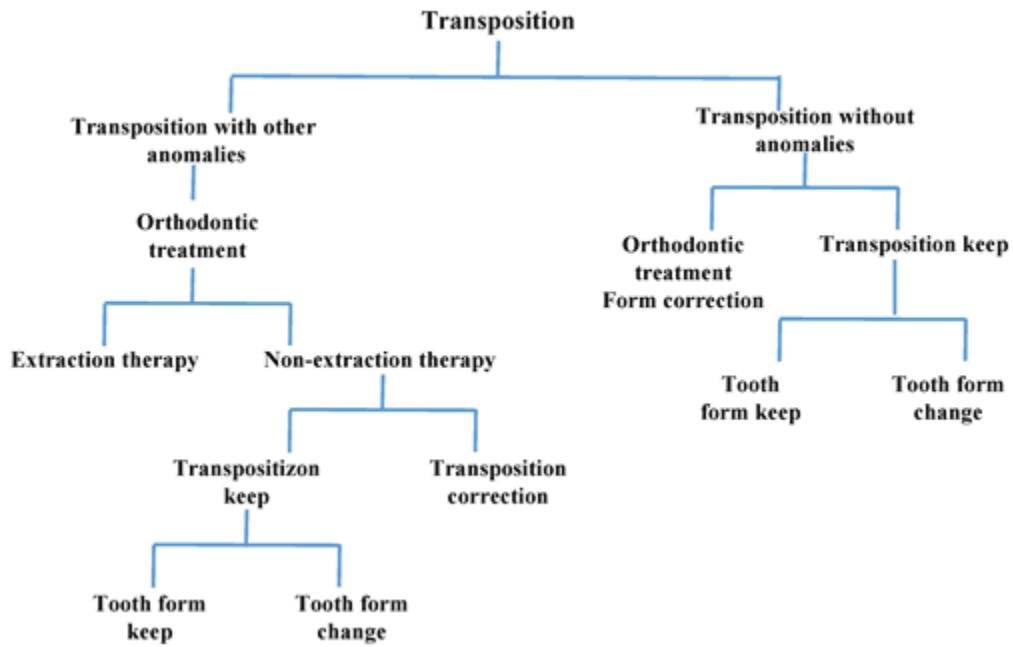


Figure 4: Transposition treatment modalities.

Table 1: Skeletal analysis.

Measurement	Mean value	Pre-treatment	Post-treatment
SNA (degrees)	82	79	81
SNB (degrees)	80	76	76
ANB (degrees)	2	3	5
WITS (mm)	-1(M), 0(F)	5	4
Effective length of Mandible (mm)		111	111
Effective length of Maxilla(mm)		85	88
Differential(mm)		26	23
Saddle angle (degrees)	123 ±5	122	120
Articular angle (degrees)	143±6	144	47
N Perp. To Point A (mm)	0-1	-9	-5
N Perp. Pog(mm)	0-4	-18	-15
Facial axis(degrees)	90±3.5	93	93
Y- axis (degrees)	59.4	64	69
MPA (degrees)	21.4	26	27
Sn- Go Gn(degrees)	32	28	32
Jarabak ratio	62-65	54	67
Palatal plane / occlusal plane (degrees)	11	10	6
Cant of occlusal plane	9.3	18	11
Basal plane angle(degrees)	25	19	20
Gonial angle (degrees)	128±7	139	124
Upper (degrees)	52-55	54	52
Lower (degrees)	72-75	74	72
LAFH	59-60	65	66
Bjork sum (degrees)	396±6	405	390

Table 2: Dentoalveolar analysis.

Measurement	Mean value	Pre-treatment	Post-treatment
Inter-incisal angle (degrees)	131	138	131
UI-SN (degrees)	102	102	91
UI - NA (mm)	4	6	3
UI- NA (degrees)	22	24	16
UI-A Pog (degrees,mm)	25,4	27,8	17,3
UI-N pog (mm)	2	9	4
UI - palatal plane (degrees)	110	115	104
LI- FH (degrees)	65	59	62
LI - MP (degrees)	90-95	96	93
LI - NB (degrees)	25	21	20
LI-NB (mm)	4	3	4
LI- A pog (mm)	1±2	1	0
LI- N Pog (mm)	-2to2	2	3

Table 3: Soft tissue analysis.

Measurement	Mean value	Pre-treatment	Post-treatment
E- line (Tip of Nose – Pog') (mm)	UL= 4mm LL =2 mm	UL= 3 LL= 0	UL= 4mm LL = 2mm
S- Line (Pog' – Midpoint of the S-shaped curve b/w Sn& nasal tip")		UL=6 LL= 4	UL= 4mm LL = 3mm
Naso- labial Angle (degrees)	92-110	90	99
Basic upper lip Thickness(mm)		18	12
Upper lip Thickness (mm)		18	12

6. Source of Funding

None.

7. Conflict of Interest

None.


References

1. Shapira Y, Kuftecc MM. Maxillary Canine - Lateral Incisor Transposition Orthodontic Management. *Am J Orthod Dentofac Orthop.* 1989;95(5):439–83.
2. Abu-Hussein M, Watted N, Yehia M, Proff P, Iraqi F. Clinical Genetic Basis of Tooth Agenesis. *J Dent Med Sci.* 2015;14(12):68–77.
3. Shapira Y, Kuftecc MM. Maxillary Tooth Transpositions: Characteristic Features And Accompanying Dental Anomalies. *Am J Orthod Dentofac Orthop.* 2001;119(2):127–61.
4. Chattopadhyay A, Srinivas K. Transposition of teeth and genetic etiology. *Angle Orthod.* 1996;66(2):147–52.
5. Peck S, Peck L. Classification of Maxillary Tooth Transpositions. *Am J Orthod Dentofac Orthop.* 1995;107(5):505–22.
6. Venkataraghavan K. Transposition of Mandibular Lateral Incisor-Canine (Mn.I2.C) Associated with Hypodontia. *J Clin Diagn Res.*

2014;8(4):4–6.

7. Abu-Hussein M, Watted N. Prevalence of Tooth Transposition in Arab Israelian(Arab48) Population; A retrospective study. *J Dent Med Sci.* 2015;14(1):65–71.
8. Jarvinen S. Mandibular Incisor-Cuspid Transposition: A Survey. *J Pedodontics.* 1982;6(2):159–63.

Author biography

Lucky Yadav, Senior Resident  <https://orcid.org/0000-0003-4731-8940>

Akanksha Jaswal, Senior Lecturer

Renuka Bamal, Senior Lecturer

Ashish Kumar, Senior Lecturer

Cite this article: Yadav L, Jaswal A, Bamal R, Kumar A. Complete transposition of mandibular lateral incisor–canine (Mn.I2.C): A rare clinical case. *J Contemp Orthod* 2022;6(3):130-135.