

Short Communication

Rapid steering towards successful derotation- A novel technique using hypodermic needle

Navnita Mishra¹, Shobha Sundareswaran^{1*}, Devi Priya A V¹¹Dept. of Orthodontics, Government Dental College, Calicut, Kerala, India

ARTICLE INFO

Article history:

Received 12-07-2022

Accepted 02-08-2022

Available online 13-09-2022

Keywords:

Derotation

Hypodermic needle

Rotation correction

ABSTRACT

Correction of rotated teeth requires significant time and efforts with conventional mechanics. Unwanted iatrogenic effects may also occur on the teeth adjacent to the rotated teeth if not undertaken correctly. The time taken for derotation of teeth can also add to the overall treatment time.

In this article, we are presenting a simple clinical technique using a hypodermic needle for faster and more efficient derotation of teeth. This technique has been found to be useful in correction of even severely rotated teeth.

This is an Open Access (OA) journal, and articles are distributed under the terms of the [Creative Commons Attribution-NonCommercial 4.0 International](https://creativecommons.org/licenses/by-nc/4.0/), which allows others to remix, and build upon the work non-commercially, as long as appropriate credit is given and the new creations are licensed under the identical terms.

For reprints contact: reprint@ipinnovative.com

1. Introduction

Derotation of teeth, both anterior and posterior offers a challenge to the clinician as it may cause unwanted iatrogenic effects if not undertaken correctly. The time taken for derotation is another matter of concern as it prolongs the overall treatment duration. Rotated posterior teeth occupy more space than they should, in contrast to rotated anteriors, which will need additional space for derotation. Literature reveals a number of methods, such as use of first order bends, rotation wedges, rotating springs, elastics, Nitinol wires, surgical derotation etc.¹⁻³ Considerable time and effort is needed while dealing with severe rotations.

According to Lindauer and Isaacson,⁴ the orthodontic appliances capable of producing the most well defined and dramatic tooth movements, are the ones that are the most simple biomechanically. One such effortless method of derotating teeth is being presented here by the use of a simple hypodermic needle which has greatly simplified the derotation process in our department.

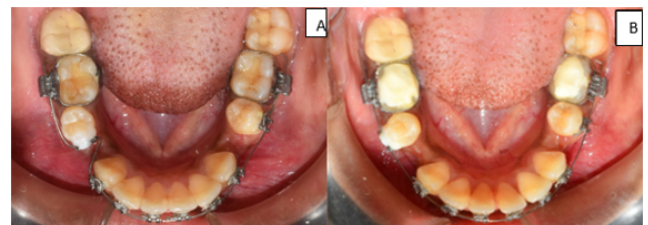

Figure 1: a: Mandibular right second premolar showing 100 degrees rotation (b): Derotation after 5 weeks.

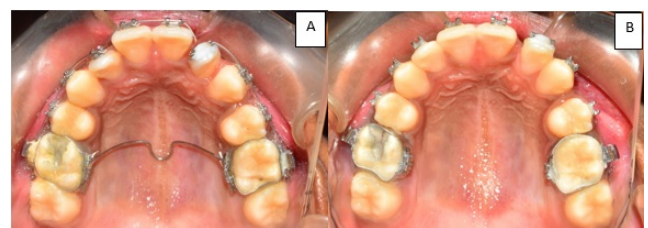


Figure 2: a: Maxillary left lateral incisor with 75degrees rotation (b): Derotation after 4 weeks.

* Corresponding author.

E-mail address: drshobhakumar@gmail.com (S. Sundareswaran).

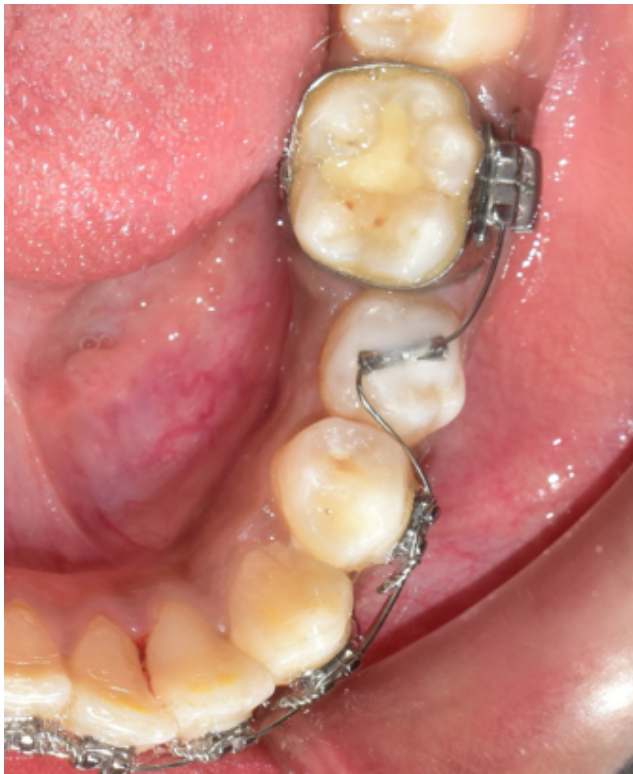

Figure 3: Needle placed on occlusal surface when buccalside is inaccessible.

2. Technique

The technique involves the use of an 18 Gauge Hypodermic needle. The needle is cut into a small piece of approximately 4-5mm length using either hard wire cutters or cutting discs. The ends of the needle can be smoothed by running it over an acrylic trimming bur. This provides us with a small, hollow, metallic tube. The rotated tooth is prepared to receive this small segment of needle by etching, rinsing and priming the buccal enamel surface. A small blob of composite is placed at the required location. The metallic tube is placed over the composite, pressed with slight finger pressure or with the back end of bracket holding tweezers and the composite is cured. After curing, an additional small blob of composite can be placed over the tube, in a direction perpendicular to its long axis and cured. This additional composite ensures firm attachment of the tube on the enamel surface. After the tube has been attached to the tooth surface, a thin flexible 0.012” Niti initial alignment archwire can be threaded gently through it and secured to the brackets placed on other well aligned teeth (Figure 1 A). Thus, the large diameter hollow needle acts as a channel for securing the flexible Niti wire.

3. Discussion

The derotation here is simplified due to the mechanical advantage obtained when the Nitinol wire is threaded through the tube to generate the necessary force akin to a wheel and axle. Bite turbos may be given to facilitate unlocking of the occlusion and providing a free movement during derotation. This method has been found to correct rotations even greater than 90° over a period of 4-5 weeks (Figure 1 A & B; Figure 2 A & B).

For very severely rotated teeth, where the buccal surface is not accessible, this tube can be attached on the occlusal surface in the same manner as described for the buccal method (Figure 3). In such cases, the resin covering the tube itself acts as a prop and allows faster derotation. This rapid derotation greatly reduces the time taken for initial leveling and aligning phase, which can have dramatic effects on the total duration of the treatment time.

4. Patient Consent

Patient consent has been obtained for the publication of photographs.

5. Source of Funding

None.


6. Conflict of Interest

None.


References

1. Shastri D, Tandon P, Singh GP, Singh A. A New rotation correction technique. *J Indian Orthod Soc.* 2014;48(4):566–9.
2. Jahanbin A, Baghahi B, Parisay I. Correction of a severely rotated maxillary central incisor with the Whip device. *Saudi Dent J.* 2010;22(1):41–4.
3. Park SH, Lee YK, Chun YS. Correction of palatally displaced maxillary lateral incisors using a tube system. *J Clin Orthod.* 2008;42(8):455–6.
4. Lindauer SJ, Isaacson RJ. One-couple orthodontic appliance systems. *Seminars Orthodontics.* 1995;1(1):12–24.

Author biography

Navnita Mishra, Resident in Orthodontics  <https://orcid.org/0000-0002-6126-4486>

Shobha Sundareswaran, Professor  <https://orcid.org/0000-0001-9605-5871>

Devi Priya A V, Resident in Orthodontics  <https://orcid.org/0000-0002-1778-5583>

Cite this article: Mishra N, Sundareswaran S, Devi Priya A V. Rapid steering towards successful derotation- A novel technique using hypodermic needle. *J Contemp Orthod* 2022;6(3):136-137.