



## Short Communication

## Dentoalveolar distraction with mandibular hyrax: A new vista

Deepak Chauhan<sup>1\*</sup>, Sanjeev Datana<sup>1</sup>, Varun Govindraj<sup>1</sup><sup>1</sup>Dept. of Dental Surgery and Oral Health Sciences, Armed Forces Medical College, Pune, Maharashtra, India

## ARTICLE INFO

## Article history:

Received 07-05-2022

Accepted 23-07-2022

Available online 13-09-2022

## Keywords:

Mandibular hyrax

Dentoalveolar distraction

Ridge expansion

Corticotomy

Adult treatment

## ABSTRACT

Management of adult orthodontic patient is always challenging as they need interdisciplinary approach and wants early completion of treatment. Adult patients generally have edentulous spaces due to various reasons. Orthodontic space closure of such old, edentulous areas especially in mandibular posterior region is the main challenge. To curtail treatment duration, a new technique of rapid Molar mesialization utilizing dentoalveolar distraction osteogenesis was used for orthodontic space closure. In this report, we presented a technique of orthodontic closure of edentulous spaces in the mandibular posterior region accelerated by corticotomy and alveolar ridge expansion utilizing dentoalveolar distraction by using a modified dentoalveolar distractor made from mandibular hyrax appliance. With this modified dentoalveolar distractor anchorage loss was minimum and edentulous space was closed in short time, also satisfactory function and esthetics were achieved without any restorative treatment.

This is an Open Access (OA) journal, and articles are distributed under the terms of the [Creative Commons Attribution-NonCommercial 4.0 International](https://creativecommons.org/licenses/by-nc/4.0/), which allows others to remix, and build upon the work non-commercially, as long as appropriate credit is given and the new creations are licensed under the identical terms.

For reprints contact: [reprint@ipinnovative.com](mailto:reprint@ipinnovative.com)

## 1. Introduction

Adult orthodontic patients are more common seeking orthodontic treatment these days. According to the American Association of Orthodontists, nearly one – third of all the patients receiving comprehensive orthodontic treatment are those older than 18 years. Management of adult orthodontic patient is different, as they generally require interdisciplinary interaction from the beginning of treatment. Another important aspect is that they demand early completion of Orthodontic treatment. Adult patients generally have missing teeth, especially in the mandibular posterior region. Management of such edentulous spaces is a challenge with limited options like: placement of fixed dental prosthesis or dental implants or orthodontic space closure. Orthodontic space closure demands prolonged treatment time and meticulous planning.

Dentoalveolar distraction osteogenesis for rapid orthodontic tooth movement is an optimistic alternative technique in management of edentulous space (orthodontic space closure) as well as it is a novel procedure that minimize the total orthodontic treatment period by approximately 70 to 80%, with no adverse effects on adjacent structures.<sup>1</sup>

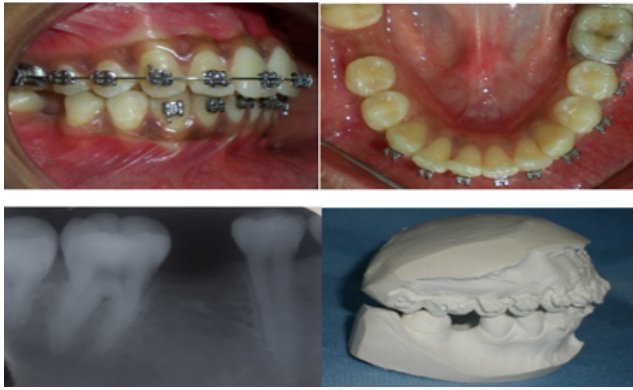
In present clinical innovation a case of young adult female presented with edentulous space in mandibular right posterior region was successfully managed with dentoalveolar distraction by utilizing a modified dentoalveolar distractor made from mandibular hyrax appliance.

### 1.1. Fabrication of the modified dentoalveolar distractor using mandibular hyrax

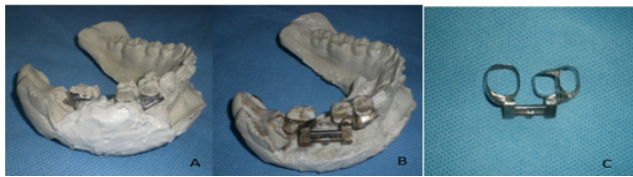1. Edentulous space 10 mm, old extraction at tooth number 46 region, was present in mandibular arch. Band selection was done for tooth number 44,45 and

\* Corresponding author.

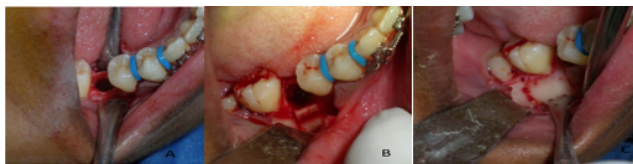E-mail address: [drdeepakchauhan99@gmail.com](mailto:drdeepakchauhan99@gmail.com) (D. Chauhan).



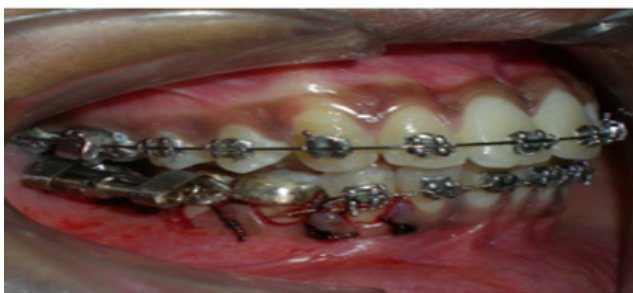**Figure 1:** Edentulous space in mandibular posterior region (Missing 46).



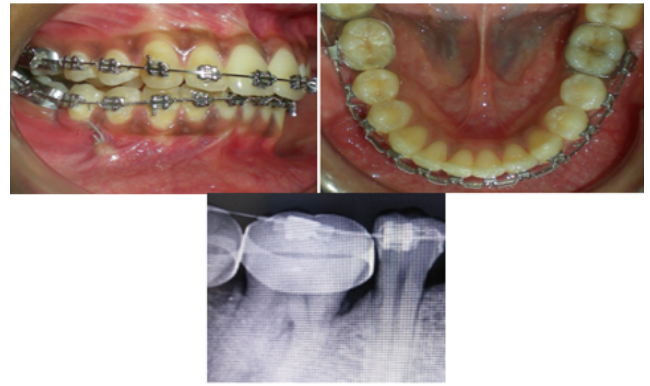
**Figure 2:** (A) Selection of appropriate mandibular hyrax and stabilization, (B) Soldering of mandibular hyrax appliance, (C) Trimmed, finished and polished modified mandibular hyrax appliance.



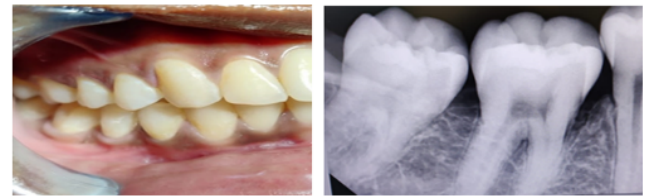
**Figure 3:** (A) softl incision and reflection of flap, (B): corticotomy ridge splitting and socket expansion, (C): intermittent bicortical perforations on distal side of mandibular second molar.



**Figure 4:** Intraoral placement of modified mandibular hyrax appliance.



**Figure 5:** Molar mesialization completed.



**Figure 6:** One year post retention status.

47 [Figure 1 A,B and C].

2. Band transfer was done and dental cast was made with type 2 dental stone [Figure 2 A]
3. Mandibular hyrax (11mm) fully opened, was adapted along the buccal surface in the mandibular posterior region right side. The assembly was stabilized with dental plaster and mandibular hyrax was soldered to molar and premolar bands. [Figure 2 A and B]
4. The new dentoalveolar distractor was appropriately trimmed, finished and polished [Figure 2 C].
5. The finished and polished distractor was checked for its adaptation in the patient's mouth and was kept ready for cementation after the surgical procedure.

## 2. Surgical Procedure

To facilitate rapid tooth movement i.e., accelerated molar mesialisation, corticotomy procedure was performed:

1. An alveolar crestal incision was given on the edentulous ridge and full thickness flap was raised. [Figure 3 A]
2. Ridge splitting and socket expansion was done to create space for molar mesialisation. [Figure 3 B]
3. On distal surface of mandibular second molar intermittent cortical perforations were done to facilitate rapid tooth movement. [Figure 3 C]

### 3. Discussion

In the present case dentoalveolar distraction was used to accomplish rapid molar mesialization, which helped in reduction of total treatment time, employing an innovative technique by modifying mandibular hyrax appliance. The edentulous space in mandibular right posterior region was four years old. It was decided to close the edentulous space by orthodontic tooth movement of posterior teeth.

Literature was searched to explore techniques to minimize treatment time for management of posterior edentulous space. Numerous surgically invasive procedures for elimination of the cortical bone obstruction to comfort or fast-track mesialization of posterior teeth into edentulous space have been enumerated in history which mainly includes corticotomy. The objective of corticotomy is to encourage the demineralization of the cortical bone of the residual alveolar ridge, which is the main barrier in tooth movement.<sup>2</sup> Another advantage of corticotomy procedure is initiation of RAP phenomenon, which accelerates physiological bone response.<sup>3</sup>

The distraction osteogenesis technique in the field of orthodontic tooth movement is utilizing the principle of distraction to move a group of teeth or a single tooth, with an aim to reduce the treatment time. Corticotomy procedure was done to expand the alveolar ridge in the mandibular posterior region and accomplish full closure of the edentulous spaces while decreasing the risks associated with removal of the alveolar ridge barrier. The procedure was similar to that used in earlier studies of ridge-split osteotomy, involving bucco-lingual expansion of the cortical bone, as is used commonly in implant dentistry.<sup>4</sup>

In the present case, similar principle of distraction to move individual tooth was utilized, with the custom-made, rigid, tooth-borne distractor [Figure 4]. The modified dentoalveolar distraction device made from mandibular hyrax appliance was helpful in achieving molar mesialization at a frequency of 0.5 mm per day. Complete molar mesialization was achieved in 15 days [Figure 5]. Prasad PN et al. (2018) proposed a modification of maxillary hyrax for maxillary molar protraction. A review of literature does not reveal any documented evidence of similar innovative use of mandibular hyrax for molar mesialization.

With this modified dentoalveolar distractor anchorage loss was minimized, since the interval of molar mesialization

was too small for movement of the anchorage unit and it was further enhanced by TAD, which was placed between two premolars. The sagittal and vertical anchorage losses were negligible and there were no clinical or radiographical confirmation of the complications, such as root resorption. This distractor should not be used in cases with knife edge ridge and pathological migration.

### 4. Conclusion

This novel innovation is easy to fabricate, utilizing commonly available mandibular hyrax and is very helpful in accomplishing rapid tooth movement, especially among adult patients with old extraction site.

### 5. Source of Funding

None.

### 6. Conflict of Interest

None.

### References

1. Alghamdi AS. Corticotomy facilitated orthodontics: Review of a technique. *Saudi Dent J.* 2010;22:1–5.
2. Wilcko MT, Wilcko WM, Bissada NF. An evidence based analysis of periodontally accelerated orthodontic and osteogenic techniques: a synthesis of scientific perspectives. *Semin Orthod.* 2008;14:305–321.
3. Frost H. The regional acceleratory phenomenon: a review. *Henry Ford Hosp Med J.* 1983;31:3–9.
4. González-García R, Monje F, Moreno C. Alveolar split osteotomy for the treatment of the severe narrow ridge maxillary atrophy: a modified technique. *Int J Oral Maxillofac Surg.* 2011;40:57–64.

### Author biography

**Deepak Chauhan**, Consultant (Orthodontics)

**Sanjeev Datana**, Associate Professor (Orthodontics)

**Varun Govindraj**, Consultant (Orthodontics)

**Cite this article:** Chauhan D, Datana S, Govindraj V. Dentoalveolar distraction with mandibular hyrax: A new vista. *J Contemp Orthod* 2022;6(3):140-142.