



Case Report

Class II malocclusion- mini plate assisted non-extraction treatment approach

Neeta Bhoir¹, Kretikka Sabharwal¹, Nitin Dinesh Gadhiya^{1*},
Sameer Narkhede¹, Karthick Shetty¹

¹Dept. of Orthodontics, DY Patil University School of Dentistry, Navi Mumbai, Maharashtra, India



ARTICLE INFO

Article history:

Received 29-07-2022

Accepted 11-11-2022

Available online 02-01-2023

Keywords:

Mini plates

Distalisation

Maxillo-mandibular Relation

ABSTRACT

Class II mal-occlusion and its non-extraction treatment approach can be quite a garbled decision for an orthodontic professional, as it has varied modalities to it depending on variety of factors such as patients facial type and profile, malocclusion of the teeth, age of the patient, overjet and overbite and many more. The non-extraction treatment of class II malocclusion without extraction mostly requires posterior movement of the maxillary dentition, anterior movement of the mandibular dentition or a combination of both; is a sine qua non. An era of appliance techniques have been developed over time and used to distalise the maxillary molars with positive clinical results, with no disposition to question their veracity. However patient co-operation remains the major concern, orthodontic mechanics requiring minimal patient co-operation are discernible and relevant. With the use of dental mini-implants and mini-plates as anchorage, the distal movement of anterior or posterior teeth or both without anchorage loss has become possible. Among these devices, mini-implants have been advantageous due to its easy placement and removal but it does have its share of setbacks being the failure rate with respect to long term retention and stability over the course of treatment. Hence mini-plates take over the dogmata of the mini-implants, even though it requires special minimal surgical technique and anatomic specificity for its placement but is very aberrant when it comes to retention and stability over a long period of time and minimal patient cooperation. Sliding mechanics with the aid of mini-plate assisted anchorage and its application for treatment of skeletal class I and class II malocclusion have been described and its application in non-extraction treatment will be enlightened. The following case reports the use of mini-plates as an anchorage aid for distalisation of maxillary molars.

This is an Open Access (OA) journal, and articles are distributed under the terms of the [Creative Commons Attribution-NonCommercial 4.0 International](https://creativecommons.org/licenses/by-nc/4.0/), which allows others to remix, and build upon the work non-commercially, as long as appropriate credit is given and the new creations are licensed under the identical terms.

For reprints contact: reprint@ipinnovative.com

1. Introduction

Class II mal-occlusion and its non-extraction treatment approach are often quite a garbled decision for an orthodontic professional, because it has varied modalities to it depending on variety of factors such as patients facial type and profile, malocclusion of the teeth, age of the patient, overjet and overbite and lots of more. Class II mal-occlusion treatment without removing any teeth

requires distalisation of maxillary dentition, or protraction of the mandibular dentition or combination of both; is a sine qua non. Various appliances have been used over time to distalise the maxillary molars, with no disposition to question their veracity. However patient co-operation remains the main concern, and the various mechanics used require minimal patient co-operation and are quite discernible and relevant.^{1,2} Intra oral devices for maxillary molar distalisation like the pendulum, push coils, magnets, super-elastic NiTi coil springs and wires, distal jet and therefore the molar sliders etc.³⁻⁸ Although these appliances

* Corresponding author.

E-mail addresses: neetabhoir19@gmail.com (N. Bhoir),
ningadhiya@yahoo.com (N. D. Gadhiya).

distalise both 1st and 2nd molars effectively, but also always exert reciprocal adverse side effects; which are mostly the forward movement of the anterior teeth which is contraindicated within the non-extraction treatment protocol in most cases. These factors definitely offset the treatment effects and liability of the appliances, these adverse effects should be minimized as much possible. The answer to these limitations has been deciphered by recent advances in implant dentistry and radiography.⁹ With the utilization of dental mini-implants and mini-plates as anchorage, the distal movement of anterior or posterior teeth or both without anchorage loss has become possible.^{10–13} Among these devices, mini implants are advantageous due to its easy placement and removal but it does have its share of setbacks being the failure rate with respect to long term retention and stability over the course of treatment. Hence mini-plates take over the dogmata of the mini-implants, although it requires special minimal surgical technique and anatomic specificity for its placement but is very aberrant when it comes to retention and stability over a long period of time and minimal patient cooperation. Sliding mechanics with the help of mini-plate assisted anchorage and its application for treatment of skeletal class I and class II malocclusion have been described and its application in non-extraction treatment will be enlightened. The subsequent case reports the utility of mini-plates as an absolute anchorage for distalisation of upper molars.

2. Diagnosis

A 23yr old male patient reported with end-on molar relation on both right and left side, moderate crowding in both maxillary and mandibular dentition, normal maxillamandibular relation with class II division 2 features anteriorly(Figure 1). Distalisation of the maxillary molars was planned and extractions were avoided as the patient had a straight pleasing profile. Miniplates were considered to serve the purpose for both distalisation and anchorage. Crowding in the lower arch was relieved by proclining the teeth and mild stripping.

2.1. Treatment outlay and progress

Upper 1st and 2nd molars were involved and 0.022" MBT system of brackets were used for the entire arch from 2nd premolar to 2nd premolar on both the sides. After aligning the anterior teeth, a segmental 0.019" × 0.025" stainless steel wire was placed to prevent distal tipping and rotation of molars. After this two y-shaped titanium miniplates were placed on both sides at the level of centre of resistance of the maxilla, zygomatic buttress area above the upper 1st and 2nd molar region acquiring the zygomatic anchorage.¹⁴

After a week, the miniplates were loaded with e-chain from the crimpable hook between the canine and lateral incisor with 0.019 x 0.025 inch stainless steel wire in place

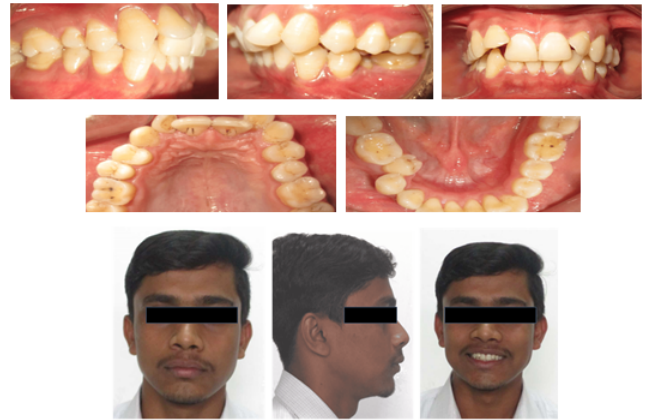

Figure 1: Pre-treatment photographs.

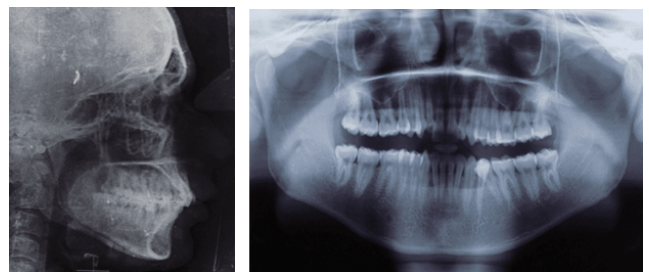


Figure 2: Pre-treatment x-rays

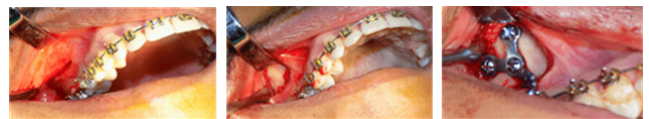

Figure 3: Surgical exposure and placement of Y-plates

for distalisation.

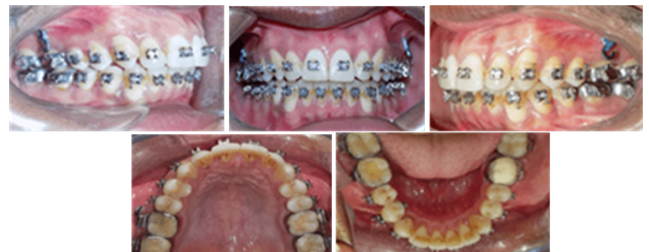

Figure 4: Before distalization intra-oral view

In a month's time, the right molar was distalised by 2mm and left molar by 1mm. After 3 months, molar distalisation of 3mm and 4mm was achieved on right and left side simultaneously. After achieving the required distalisation, ideal overjet and over bite was achieved. Final settling of occlusion was also achieved.

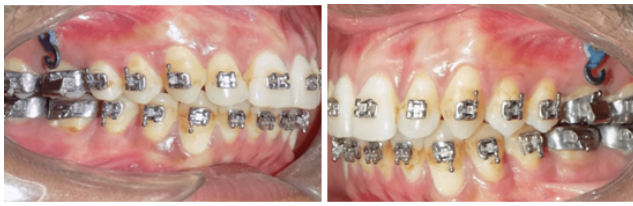

Figure 5: Distalization progress

2.2. Treatment effects

A full cusp Class I molar and canine relation on both sides was achieved with appreciable alignment in both the arches without any premolar extractions. The profile was also improved pleasingly.

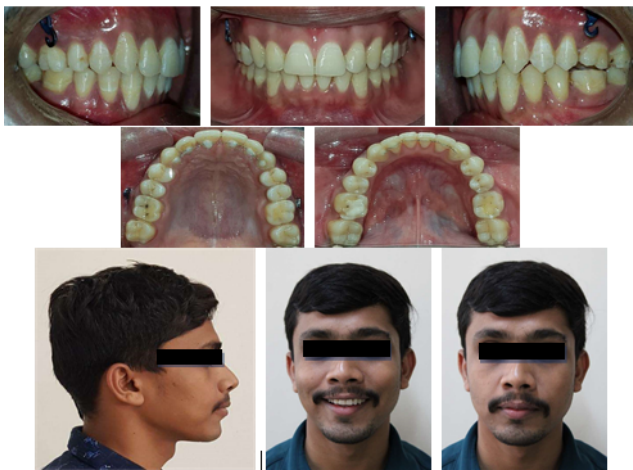

Figure 6: Post treatment photographs

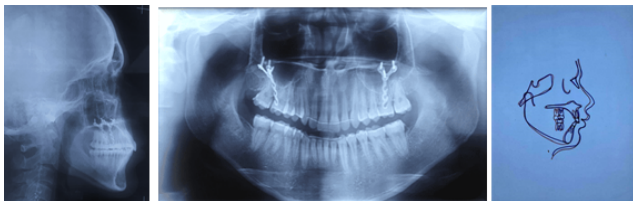


Figure 7: Post treatment x-rays and superimposition

3. Discussion

A major disadvantage of devices which are used for distalizing the upper molars is reciprocal opposite movement of premolars and anterior teeth in mesial direction. But during this case i.e. class II division 2 case the forward movement of anterior teeth was needed for better over-jet and overbite. Otherwise in other cases where molar distalization is done there is always some amount of anchor loss in form of maxillary anterior proclination.

Table 1: Cephalometric comparison table

Measurement	Normal	Pre Treatment	Post Treatment
SNA	82±2°	83°	81°
SNB	80±2°	78°	79°
ANB	2±2°	5°	2°
Wits Appraisal	-1mm	3mm	1mm
Nasion perpendicular to point A	0-1mm	1mm	0mm
SN plane -Mandibular plane	32±2°	35°	36°
FMA	16-28°	28°	29°
Facial Angle	87.8°	83°	82°
Angle of Convexity	0°	4°	1°
Upper Incisor to NA	4mm/22°	2mm/2°	4mm/24°
Upper incisor to SN plane	102±2°	82°	104°
Lower incisor to NB	4mm/25°	4mm/24°	6mm/28°
IMPA	90°	88°	94°
Inter incisal Angle	131°	154°	135°
FMIA	65°	64°	57°
Nasolabial Angle	90-110°	108°	112°

now we have to correct this anteriorly moved teeth by creating space by distalizing molars, where molars are used as an anchorage. Thus molars are strained and it affects the efficiency of distalizing devices. Moreover, there is a round-tripping as incisors are proclined during the distal movement of the molars and then again they are retracted into the space created by distalized molar. However in case of miniplates the entire buccal segment can be distalized without any strain on the anterior teeth. So use of miniplates don't produce any undesirable effect on the incisors.¹⁴ A systematic review by Antonarakis and Kiliaridis states that that tooth-borne distalizing appliances can move upper molars distally by around 2.9 mm; but there is undesirable mesial movement of incisors by 1.8mm.¹⁵ The findings of this case indicate that the orthodontic miniplates can be used as absolute anchorage with maximum molar distalization without any adverse effect on the incisors. When similar studies for distalization were compared, it was shown that the mean distal movement of upper molars is between 3.9mm to 6.4mm. All these studies also show that there is no adverse effect on the incisors and they remained stable. This clearly suggests that the distalization with miniplates is far superior to intraoral tooth born distalizing appliance.¹⁴⁻¹⁶

4. Conclusion

Distalisation of the molars or entire buccal posterior segment in maxillary arch can be successfully achieved by using the miniplates. In addition they shorten treatment duration as entire buccal posterior segment can be distalised without any adverse effect on the incisors. So, in cases such as Class II division 2 with straight profile and where extraction is contraindicated, molar distalization using plates could be the best option.

5. Source of Funding

None.

6. Conflict of Interest


None.


References


1. Gray JB, Steen ME, King JG, Clark AE. Studies on the efficacy of implants as orthodontic anchorage. *Am J Orthod*. 1983;83(4):311–28.
2. Byloff FK, Kärcher H, Clar E, Stoff F. An implant to eliminate anchorage loss during molar distalization: A case report involving the Graz implant-supported pendulum. *Int J Adult Orthod Orthognath Surg*. 2000;15(2):129–66.
3. Hilgers JJ. The pendulum appliance for Class II noncompliance therapy. *J Clin Orthod*. 1992;26(11):700–13.
4. Joseph A, Butchart CJ. An evaluation of the pendulum distalizing appliance. *Semin Orthod*. 2000;6(2):129–64.
5. Gianelly AA, Bednar J, Dietz VS. Japanese NiTi coils used to move molar distally. *Am J Orthod Dentofac Orthop*. 1991;99(6):564–66.
6. Gianelly AA, Vaitas AS, Thomas WM. Distalization of molars with repelling magnets. *J Clin Orthod*. 1988;22(1):40–4.
7. Gianelly AA, Vaitas AS, Thomas WM. The use of magnets to move molars distally. *Am J Orthod Dentofac Orthop*. 1989;96(2):161–7.
8. Locatelli R, Bednar J, Dietz VS, Gianelly AA. Molar distalization with superelastic NiTi wire. *J Clin Orthod*. 1992;26(5):277–9.
9. Melsen B. Overview of mini-implants: where are we? *J Clin Ortho*. 2005;39(9):539–86.
10. Sugawara M, Mitani J, Nagasaka H, Kawamura H. Skeletal anchorage system for open bite correction. *Am J Orthod Dentofac Orthop*. 1999;115(2):166–74.
11. Creekmore TD, Eklund MK. The possibility of skeletal anchorage. *J Clin Orthod*. 1983;17:266–69.
12. Park HS. The skeletal cortical anchorage using titanium microscrew implants. *Korean J Orthod*. 1999;29(6):699–706.
13. Park HS. The use of micro-implant as orthodontic anchorage. Seoul: Nare Pub Co; 2001. p. 5–192.
14. Sugiwara J, Kanzaki R, Takahashi I, Nanda R. Distal movement of maxillary molars in nongrowing patients with the skeletal anchorage system. *Am J Orthod Dentofac Orthop*. 2006;129(6):723–56.
15. Antonarakis GS, Kiliaridis S. Maxillary molar distalization with noncompliance intramaxillary appliances in Class II malocclusion. A systematic review. *Angle Orthod*. 2008;78(6):1133–73.
16. Patil N, Kerudi V, Harshal A, Patil PD, Tekale P. Siddhesh Dolas. Molar Distalization By Miniplates- A Review. *J App Dent Med Sci*. 2016;2(1):123–30.


Author biography

Neeta Bhoir, Post Graduate Student  <https://orcid.org/0000-0001-5652-9825>

Kretikka Sabharwal, Post Graduate Student  <https://orcid.org/0000-0002-0975-9289>

Nitin Dinesh Gadhiya, Professor  <https://orcid.org/0000-00002-7408-6666>

Sameer Narkhede, Professor and Head  <https://orcid.org/0000-0002-3417-9681>

Karthick Shetty, Professor  <https://orcid.org/0000-0001-8094-149X>

Cite this article: Bhoir N, Sabharwal K, Gadhiya ND, Narkhede S, Shetty K. Class II malocclusion- mini plate assisted non-extraction treatment approach. *J Contemp Orthod* 2022;6(4):192-195.