



Short Communication

Modified hiro method: A new and simple transfer tray method for indirect bonding

Siddharth Mehta^{1*}, Shweta Parashar¹, Kamal Bajaj¹¹Dept. of Orthodontics, Mahatma Gandhi Dental College and Hospital, MGUMST, Jaipur, Rajasthan, India

ARTICLE INFO

Article history:

Received 25-06-2022

Accepted 01-11-2022

Available online 29-03-2023

Keywords:

Indirect bonding

Lingual Orthodontics

Long axis marker

Modified Hiro

Tray handle

ABSTRACT

Indirect bonding is a very important step in the success of lingual orthodontics. This article provides a simple and time saving method of transfer tray preparation for indirect bonding of lingual brackets

This is an Open Access (OA) journal, and articles are distributed under the terms of the [Creative Commons Attribution-NonCommercial 4.0 International](https://creativecommons.org/licenses/by-nc/4.0/), which allows others to remix, and build upon the work non-commercially, as long as appropriate credit is given and the new creations are licensed under the identical terms.

For reprints contact: reprint@ipinnovative.com

1. Introduction

Indirect bonding is a very important step in the success of lingual orthodontics. Dr. Hiro described the Resin Core Indirect Bonding System (RCIBS) in 1998.^{1,2} Other authors have suggested single or dual tray methods with PVS, Dual vacuum formed tray, Dr. Echhari's method of CRC ready-made core individual tray with outer single overlay silicone tray.^{3,4} This article shows a new and simple method of transfer tray preparation.

1.1. Armamentarium needed (Figure 1)

1. Orthodontic model
2. Lingual brackets
3. Wooden tooth picks
4. Color
5. Denture reline material (Soft Liner) powder and liquid
6. Cold cure acrylic (DPI RR) powder and monomer
7. Separating medium
8. Dappen dish
9. Mixing spatula

* Corresponding author.

E-mail address: sidmehta100@gmail.com (S. Mehta).

10. Marker

1.2. Steps of the modified hiro transfer tray method

1. After HIRO setup, lingual brackets are bonded to the lingual surface of orthodontic model with the help of adhesive.
2. Undercuts beneath the lingual brackets are blocked out with the help of orthodontic wax. Long axis markers made with the help of wooden tooth picks are embedded in the wax according to the long axis of the tooth. (Figure 2)
3. Soft denture reline material (powder and liquid) is mixed and is used to make the inner core of transfer tray. This gives a soft resilient core which will not distort. (Figure 3)
4. Cold cure acrylic resin is then mixed and adapted on the occlusal and labial surface of the teeth. Thus, rigid outer core of the transfer tray is fabricated.
5. The final transfer tray is then marked individually according to the tooth number with a marker. (Figure 4)
6. Individual transfer tray is detached from the cast surface with the help of a probe. The long axis marker

also serves as tray handle. (Figure 5)

7. After sandblasting the bracket base and placement of orthodontic adhesive, bracket is positioned and cured on the designated tooth with the help of new transfer tray.
8. After bonding, transfer tray can be easily removed with a probe. (Figure 6)
9. On visual examination, long axis marker provides bracket placement along the long axis of the tooth. (Figure 7)
10. Entire bonding is then done with the help of the new transfer tray method and 0.012” nickel titanium wire ligated. (Figure 8)

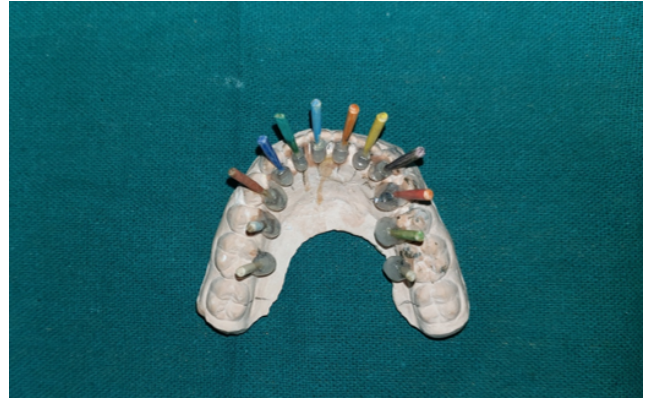

Figure 3: Soft denture reline material used to make the inner core of transfer tray



Figure 1: Armamentarium needed

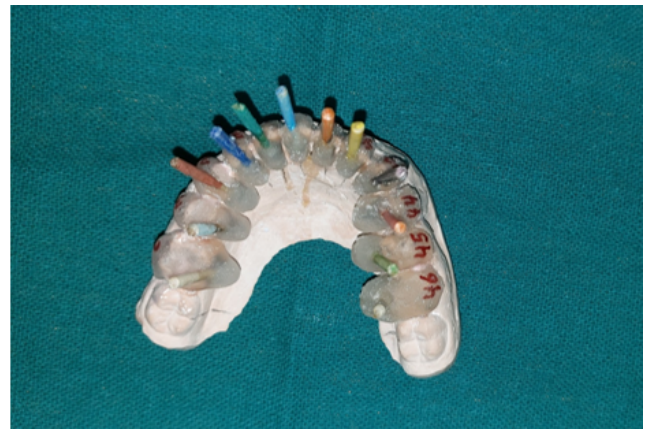

Figure 4: Cold cure acrylic resin used to make outer core of the transfer tray

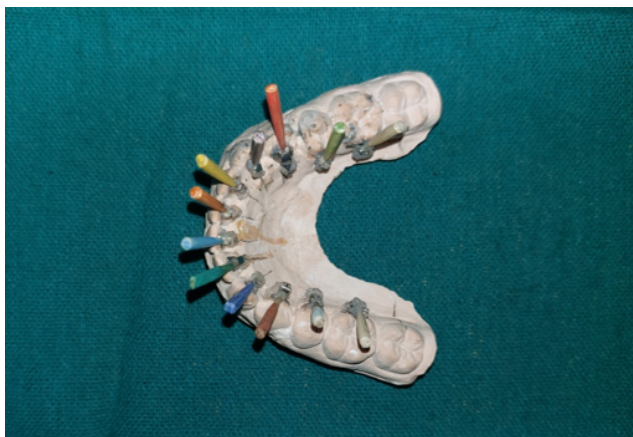

Figure 2: Undercuts blocked out with orthodontic wax and long axis markers embedded in the wax according to the long axis of the tooth.

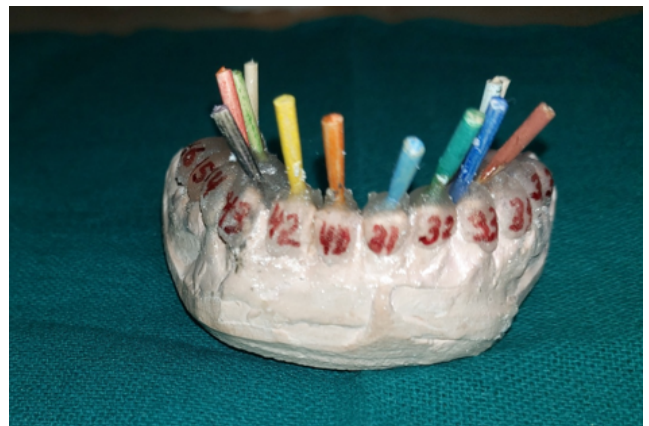

Figure 5: Transfer tray marked individually according to the tooth number.

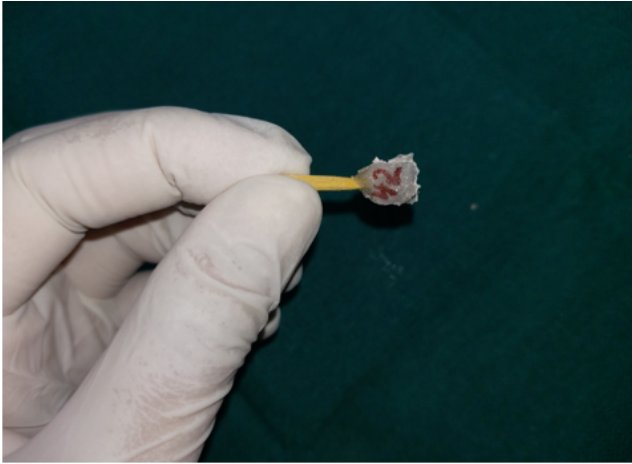


Figure 6: Individual transfer tray detached from the cast surface with long axis marker serving as tray handle

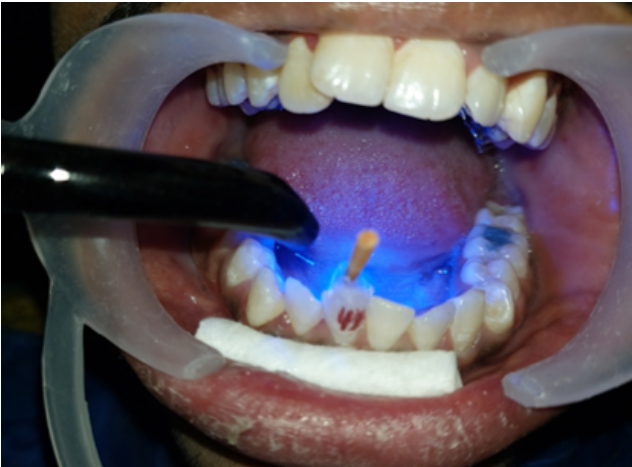

Figure 7: After sandblasting the bracket base and placement of orthodontic adhesive, bracket positioned and cured on the designated tooth with the help of new transfer tray.

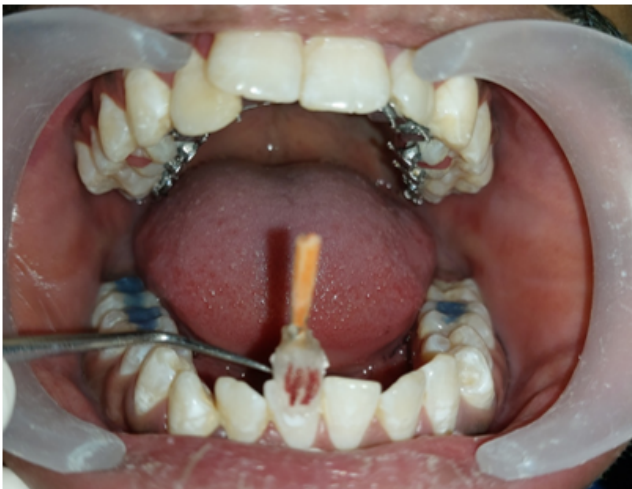

Figure 8: After bonding, transfer tray easily removed with a probe.

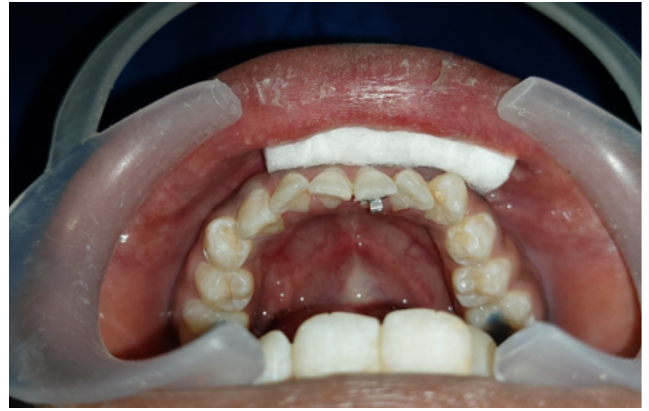

Figure 9: Bracket placed on the long axis of the tooth

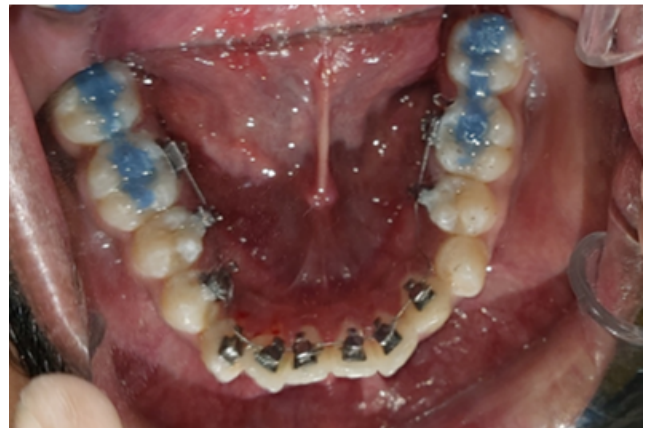

Figure 10: Entire bonding done and wire ligated

1.3. Advantages of the modified hiro transfer tray method

1. Simple and easy to fabricate.
2. Saves a lot of chair side time. This method when compared to double vacuum formed tray method held advantage as adaptation of vacuum formed sheet after cutting individual tray varies if not cut properly and long axis of the tooth cannot be figured out. Long axis markers can solve this issue even at a later date in case of debonding.
3. Materials used to build core have dimensional stability and can be reused for rebonding.
4. Long axis marker also serves as tray handle.

2. Conclusion

Modified Hiro transfer tray method is simple, effective and time saving method which can be easily followed by fellow practitioners.

3. Source of Funding

None.

4. Conflict of Interest

None.

References

1. Prabhuraj BK. Indirect bonding in lingual orthodontics - a review. *Ann Essences Dent.* 2011;3(4):79–84.
2. Hiro T, Iglesia FDL, Puigdollers A. Indirect bonding technique in lingual orthodontics: the HIRO system. *Prog Orthod.* 2008;9(2):34–55.
3. Rajveer S, Rajat P. Indirect bonding in lingual orthodontics. *J Dent Sci.* 2017;2(4):1–5.

4. Echarri P, Kim TW. Double transfer trays for indirect bonding. *J Clin Orthod.* 2004;38(1):8–13.

Author biography

Siddharth Mehta, Professor

Shweta Parashar, Post Graduate Student

Kamal Bajaj, Professor and Head

Cite this article: Mehta S, Parashar S, Bajaj K. Modified hiro method: A new and simple transfer tray method for indirect bonding. *J Contemp Orthod* 2023;7(1):70-73.