



Case Report

A case report on management of complex malocclusion using infra-zygomatic bone screws

Jeegar K. Vakil^{1*}, Ketan. K. Vakil¹

¹Dept. of Orthodontics, Private Practitioner, Surat, Gujarat, India



ARTICLE INFO

Article history:

Received 10-12-2022

Accepted 09-02-2023

Available online 16-06-2023

Keywords:

En masse distalization

passive selfligation

orthodontic bone screws

infrazygomatic crest

ABSTRACT

Here is a case report of a 20 year old male patient who reported with chief complaint of irregular teeth and un-esthetic smile. Patient was diagnosed with hypodivergent face pattern, retroclined upper incisors and anterior deep bite. Molars were in End-on relationship. Treatment was planned using passive self-ligation (Damon system) and enmasse arch distalization using Infra-zygomatic bone screws. Treatment result showed marked improvement in facial esthetics and occlusion by incorporating predictable biomechanics.

This is an Open Access (OA) journal, and articles are distributed under the terms of the [Creative Commons Attribution-NonCommercial 4.0 International](https://creativecommons.org/licenses/by-nc/4.0/), which allows others to remix, and build upon the work non-commercially, as long as appropriate credit is given and the new creations are licensed under the identical terms.

For reprints contact: reprint@ipinnovative.com

1. Introduction

Micro-implants and orthodontic bone screws have brought a renaissance to the field of orthodontics. Recently, Orthodontic bone screws have become an added armamentarium for the orthodontist as a part of treatment strategy in complex orthodontic cases.

Although it is common to place them in areas of the alveolar process located between the roots of the affected teeth, new sites have been proposed, called extra alveolars. Numerous authors recommend the infrazygomatic crest and the mandibular buccal shelf area as suitable places for a great number of orthodontic therapies that require an effective and safe adherence system, there by increasing treatment limits. The bone quality of the infrazygomatic crest and buccal shelf area are ideal for good stability of screw installation. This can with stand the force required for distalization without interfering with the roots of teeth.¹

A passive self-ligation system provides the least friction as compared to other bracket system. Thus, the forces generated by the archwire are transmitted directly to the teeth and supporting structures without absorption or

transformation by the ligature system. There is extended intervals between the treatment visits, particularly in early stages of treatment and reduced number of visits during the course of treatment.²

2. Case Report

A 20 year old male named N. R. reported to our clinic with the chief complaint of un-esthetic smile and very irregularly placed teeth. There was no significant medical history or drug allergy. Extra-oral features revealed hypo-divergent face type, no gross facial asymmetry and competent lips. Facial profile was mild convex. Smile was un-esthetic and patient mainly wanted correction of his unpleasant smile. (Figure 1)

Intra-oral features revealed severe crowding in upper and lower arches. There was presence of deep anterior overbite (7 mm). Overjet was reduced (1 mm). Molars were in End-on relation bilaterally. Upper and lower anteriors were retroclined. Upper arch form was squarish whereas lower arch was ovoid and asymmetric.

(Figure 2). There was severe tooth material- arch length discrepancy as depicted in pre-treatment study models. (Figure 3)

* Corresponding author.

E-mail address: dr.jeegarvakil@gmail.com (J. K. Vakil).

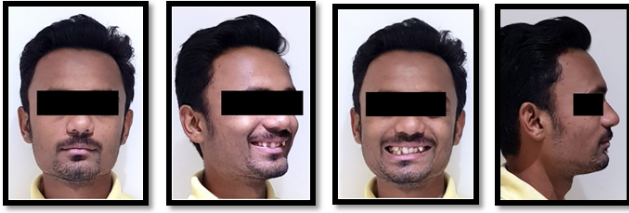

Figure 1: Pre-treatment extra-oral photographs

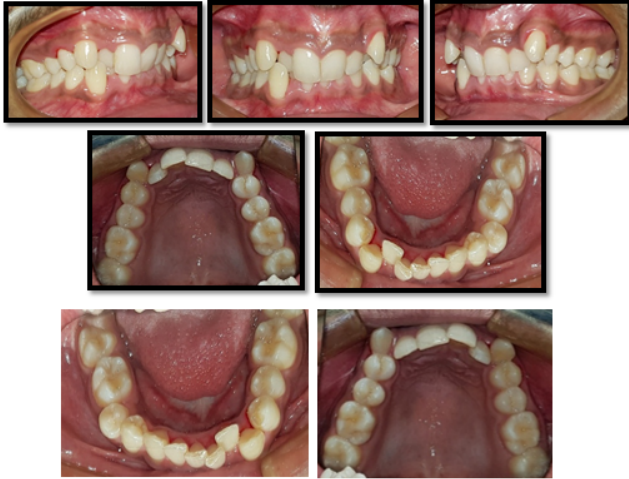

Figure 2: Pre-treatment Intra-oral photographs

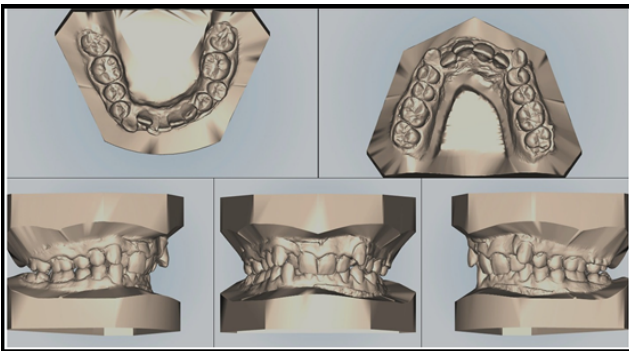


Figure 3: Pre-treatment study models

Pre-treatment panoramic radiograph revealed that temporomandibular joint (TMJ) of the patient was normal with bilaterally symmetrical condyles. The upper third molars were erupting whereas lower third molars were mesio-angularly impacted. (Figure 4)

Pre-treatment lateral cephalogram reveals Class II skeletal pattern due to retrognathic mandible. Mandibular plane angle was low and mentolabial sulcus was deep. Upper and lower incisors were retroclined and inter-incisal angle was increased. There was increased overbite and reduced overjet. (Figure 5)

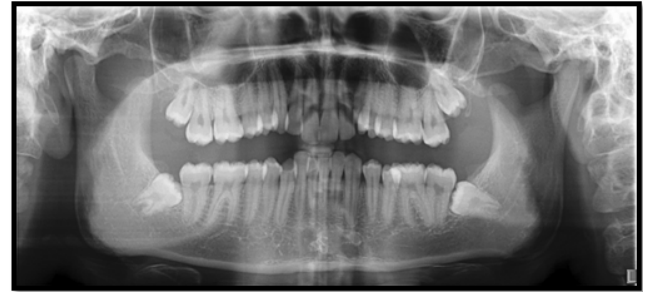


Figure 4: Pre-treatment OPG

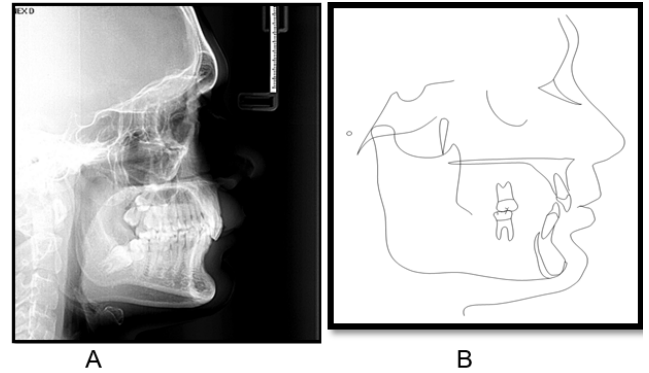


Figure 5: a: Pre-treatment lateral cephalogram b: Pre-Treatment tracing

2.1. Treatment objectives

Patient treatment objectives:

1. Correction of smile aesthetics
2. Correction of severe crowding in upper and lower arches
3. Achieve normal overbite and overjet
4. Achieve Class I molar, canine and incisor relation

Considering the soft-tissue profile of the patient, the treatment plan which was decided was

1. Extract 3rd molars in upper and lower arches
2. Distalize the upper arch dentition using Infra-zygomatic bone screws to achieve antero-posterior correction.

Passive self-ligation (Damon system- Ormco^R, Orange, Calif) with high torque brackets for upper anteriors and low torque for the lower anteriors was used. The main purpose of using these brackets was to take advantage of variable torque system.

2.2. Treatment progress

Initial leveling and alignment were achieved with 0.013'' CuNiTi, 0.014 × 0.025'' CuNiTi, and 0.018 × 0.025''

CuNiTi archwires respectively. There was increased patient comfort with CuNiTi wires.

High torque brackets in the upper anteriors were preferred for the correction of inclination, whereas low torque was used in the lower anteriors for maintaining the roots of lower incisors in the cancellous bone.

After the leveling and alignment stage, Infra-zygomatic extra-radicular bone screws with a long collar (Bioray A1-P) 2 mm x 14 mm were placed between 1st and 2nd molars under local anaesthesia. Extra-radicular infrazygomatic bone screws caused the full-arch distalization of the upper arch without any interference with the roots of teeth.

Retraction mechanics were performed by applying force by means of power chain from the screw to the crimpable hooks between lateral incisor and canine on both the sides (Figure 6). The rationale behind placing the hooks distal to lateral incisors was to avoid gingival impingement of power chains. The force of 250-300 grams was applied bilaterally. The en-masse distalization of all maxillary was completed in 8 months, with a total treatment period of 18 months.

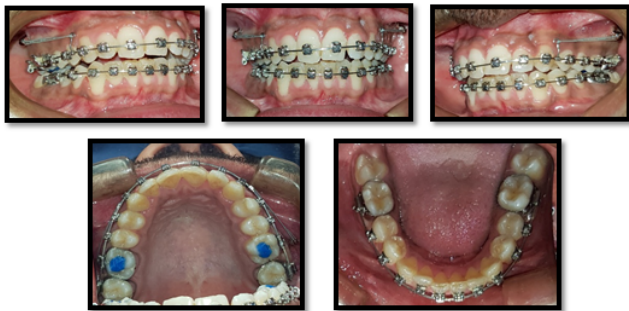

Figure 6: Mid-treatment intra-oral photographs with IZC screws

2.3. Treatment results

Post-treatment records show that the treatment goals have been achieved. Extra-oral photographs show improvement in facial aesthetics. A consonant smile arc was achieved and smile aesthetics improved significantly, thus addressing patient’s chief complaint. (Figure 7)

The case was finished with Class I incisor relationship with normal overjet and overbite of 2 mm. The upper and lower dental midlines matched at the end of the treatment. The right and the left buccal segment finished with a Class I molar and canine relationship. All displacements were corrected by the end of the treatment. No occlusal wear facets were noted with mutually protected occlusion and canine guided excursive movements established. Arch forms are symmetrical. (Figure 8)

Lateral cephalogram reveals almost normal inclinations of maxillary and mandibular incisors and Class I molar and canine relation with a straight facial profile. (Figure 9)

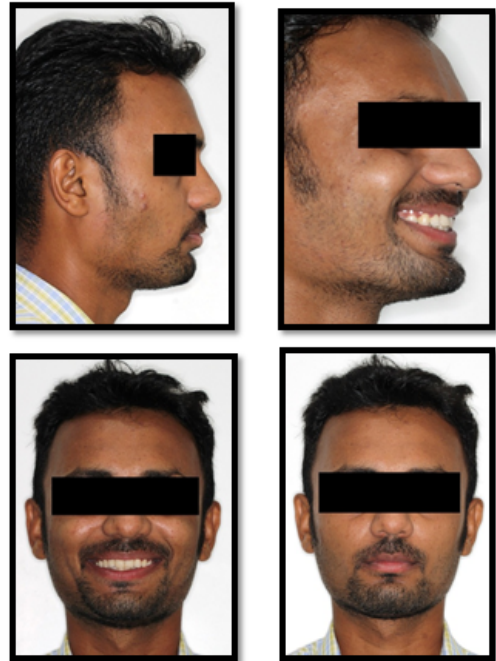

Figure 7: Post-treatment extra-oral photographs

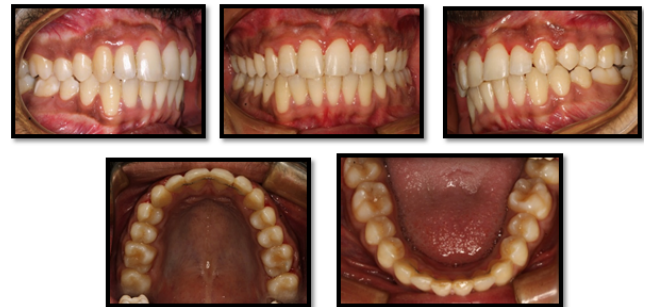

Figure 8: Post-treatment intra-oral photographs

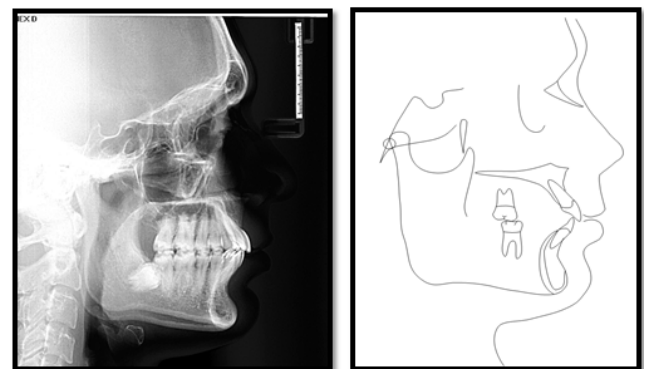


Figure 9: a: Post-treatment Lateral cephalogram b: Post-Treatment Lateral Cephalogram tracing

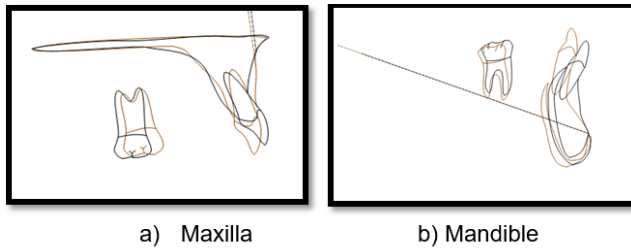


Figure 10: Super-impositions

Table 1: Comparison of cephalometric parameters

Variable	Pre-Treatment	Post-treatment
Sagittal skeletal relationships (°)		
SNA	890	880
SNB	830	840
ANB	60	40
Wit's appraisal	+5 mm	+3 mm
Dental base relation (mm/0)		
Upper incisor to NA	100 /-1 mm	330/+3 mm
Lower incisor to NB	190 /1 mm	310/+3 mm
IMPA	770	1120
Inter-incisal angle	1490	1190
Vertical skeletal relation (0)		
Maxillary-mandibular plane angle	220	220
SN-Mandibular plane	100	120
FMA	110	130
Soft-tissues		
Lower lip to Rickett's E-line (mm)	2 mm	0
Upper lip to S line (mm)	0	0
Nasolabial angle (0)	1150	1180

3. Discussion

Facial aesthetics and unpleasant smile was the main reason for seeking orthodontic treatment.

In the present case, there was severe crowding in upper and lower arches. So, passive self-ligation Damon system was selected which helps to reduce the friction during initial stage of treatment and easier correction of crowding.³ High torque brackets in upper anteriors proved to be beneficial for correcting the inclination of incisors and also to achieve proper torque.

Low torque brackets were used for lower anteriors to maintain the position of lower incisors.

For distalization of the dental arch, the position of mini-implant or bone screw plays an important role. The preferred site for placement of infra-zygomatic crest screws is higher and lateral to the 1st and 2nd molar region.⁴ The sites like the infrazygomatic crest region, buccal shelf area, and

retromolar region are with thicker cortical bone layer. The placement of screws at a distance away from the tooth root is preferred to avoid interference with dental movements. The center of resistance (Cres) of the maxillary dentition was shown to be close to the center of the premolar roots.⁵

The position of the miniscrews in relation to the Cres determined the magnitude and direction of the force vector and helped to achieve arbitrary arch rotation.⁶

3.1. Critical appraisal

From an orthodontic point of view, treatment result is very much acceptable. The desired treatment goals like correction of crowding, correction of anterior deep bite and upper arch distalization were well achieved. (Figure 11). Patient's concern of unesthetic smile was well addressed and good change in facial aesthetics was noticed at the end of treatment.

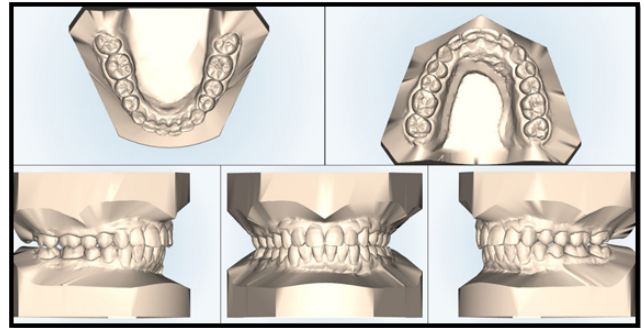


Figure 11: Post-treatment study models

Patient was advised extraction of all 3rd molars before the start of orthodontic treatment itself. However, despite being advised, patient was not willing for surgical disimpaction of lower 3rd molars. Root Uprighting of lower 2nd molars was not achieved due to interference of impacted 3rd molars. (Figure 12)

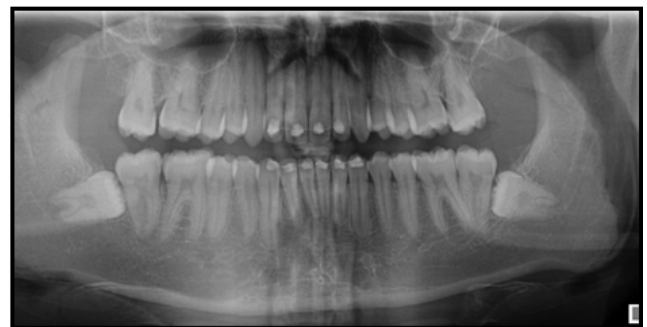

Figure 12: Post-treatment OPG

The marginal ridge relation of upper 1st and 2nd molars should have been better. The root parallelism is not ideal, however it is in acceptable limit.

Inter-cuspatation of posterior segment is well achieved and post-treatment relapse is not much expected as patient has passed the growth phase. Patient has been given fixed retainers in upper and lower anteriors along with thermoplastic retainer for upper arch as retention protocol.

4. Conclusion

Proper case selection, use of passive self-ligation (Damon system- Ormco^R), incorporating Infra-zygomatic bone screws with predictable biomechanics along with understanding of anatomic limits for distalization were the important factors that helped us in achieving desired treatment outcome.

It is undeniable that extra-radicular screws have revolutionized Orthodontics by broadening the treatment horizons and will continue to do so in future.

5. Statement of Informed Consent

Written informed consent was obtained from the subject for the use of photographs for publication.

6. Source of Funding

The authors have no financial interest with respect to authorship and/or publication of the article.

7. Declaration of Conflict of Interest

The authors declared no potential conflicts of interest with respect to authorship and/or publication of the article.

References

1. Almeida MR. Biomechanics of extra-alveolar mini-implants. *Dental Press J Orthod.* 2019;24(4):93–109.
2. Birnie D. The Damon passive self-ligating appliance system. *Semin Orthod.* 2008;14(1):19–35.
3. Damon DH. The Damon low friction bracket: A biologically compatible straight wire system. *J Clin Orthod.* 1998;32(11):670–80.
4. Lin J, Roberts E. CBCT imaging to diagnose and correct the failure of maxillary arch retraction with IZC screw anchorage. *Int Orthop Implantol.* 2014;35:4–17.
5. Jeong GM, Sung SJ, Lee KJ, Chun YS, Mo SS. Finite element investigation of the center of resistance of the maxillary dentition. *Korean J Orthod.* 2009;39(2):83–94.
6. Bechtold TE, Kim JW, Choi TH, Park YC, Lee KJ. Distalization pattern of the maxillary arch depending on the number of orthodontic miniscrews. *Angle Orthod.* 2013;83(2):266–73.

Author biography

Jeegar K. Vakil, Private Practitioner

Ketan. K. Vakil, Private Practitioner

Cite this article: Vakil JK, Vakil KK. A case report on management of complex malocclusion using infra-zygomatic bone screws. *J Contemp Orthod* 2023;7(2):145-149.