



Case Report

Driftodontics: A neglected treatment approach

Yash Agarwal^{1*}, Mukesh Kumar¹, Manish Goyal¹, Atam Jain², Md Abrar¹

¹Dept. of Orthodontics and Dentofacial Orthopaedics, Teerthanker Mahaveer Dental College and Research Centre, Bagadpur, Uttar Pradesh, India

²Santosh Medical College, Ghaziabad, Uttar Pradesh, India



ARTICLE INFO

Article history:

Received 03-04-2023

Accepted 11-05-2023

Available online 16-06-2023

Keywords:

Driftodontics

Transpalatal arch

Mesoproscopic

ABSTRACT

Clear aligners have become increasingly popular in recent years due to patients' esthetic and comfort needs. Many movements are still unachievable, highlighting the limitations of clear aligner therapy. Moreover, it is expensive and many patients cannot afford it for orthodontic correction. Long-term fixed orthodontic devices are painful for patients, with complaints of discomfort and ulceration during their treatment. This can be reduced by minimizing the duration of appliance wear, as driftodontics allows the teeth to adjust naturally without applying any active force. The duration of active fixed orthodontic therapy is significantly reduced compared to the hybrid approach (partial fixed appliances combined with clear aligners) as well as conventional fixed orthodontic therapy. In this case report, after all first premolar extractions, physiologic drift was used to decrowd the arches and an active TPA to correct unilateral crossbite within five months only, followed by another 5 months of active fixed orthodontic appliance. Over a total period of 10 months, we achieved a bilateral Class I molar and canine relationship with significant improvement in lip competency.

This is an Open Access (OA) journal, and articles are distributed under the terms of the [Creative Commons Attribution-NonCommercial 4.0 International](https://creativecommons.org/licenses/by-nc/4.0/), which allows others to remix, and build upon the work non-commercially, as long as appropriate credit is given and the new creations are licensed under the identical terms.

For reprints contact: reprint@ipinnovative.com

1. Introduction

Orthodontic rectification of malocclusion is a tedious procedure and every patient wants to be treated in the shortest time frame with an esthetic treatment approach. Aligners are comfortable option for orthodontic treatment and have gained immense popularity over the last decade. In contemporary orthodontic practice, clear aligner therapy is frequently the preferred treatment, especially for patients with mild to moderate discrepancies who do not require extraction.¹

For more severe cases, fixed appliances are needed since clear aligners therapy is less efficient.² Premolar extraction is typically performed to rectify a tooth size arch length size disparity, to allow correction of the axial tilt of anterior

teeth, or to correct the lower vertical height of the face. Spontaneous adjustment of dentition is induced in the space created by the extraction. Bourdet³ termed this adjustment "physiologic drift" and defined it as a natural adjustment of dentition following tooth loss. To alleviate the crowding of the anterior region, Alexander recommended postponing lower arch bonding so that the teeth could drift naturally.⁴ The maxillary first molars and canines migrate into the gap at a comparable rate, suggesting that molar mesial drift following premolar extraction may result in some molar anchorage loss. In instances where maximal molar anchorage control is required, this should be prevented as soon as possible following premolar extraction.⁵

This case report describes the effective orthodontic treatment of a young growing male patient with crowding in the upper and lower anterior region, by driftodontics in conjunction with a delayed fixed orthodontic therapy after

* Corresponding author.

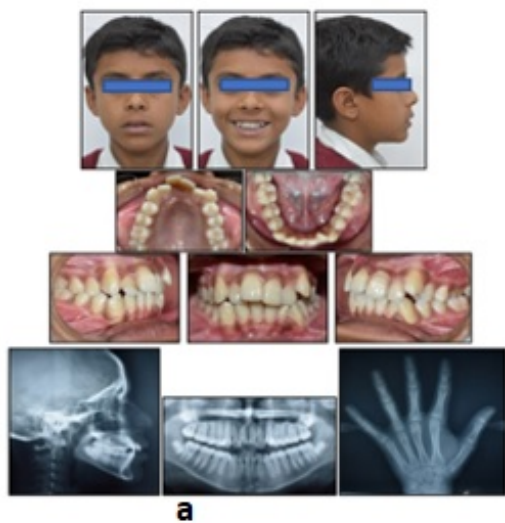
E-mail address: dragarwalyash@gmail.com (Y. Agarwal).

four premolars extraction.

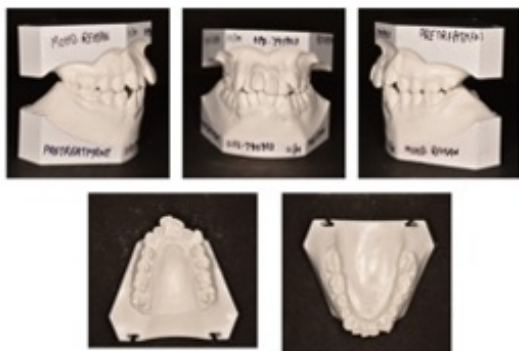
2. Case Presentation

2.1. Diagnosis

A 12-year-old male patient came to the orthodontic department, with the main concern being crowding in both the maxillary and mandibular anterior regions. Extra-oral clinical examination revealed mesocephalic head shape, mesoprosopic facial form with incompetent lips and acute nasolabial angle with orthognathic facial divergence, while intraoral examination depicted a Class I molar relationship on the right side and end-on molar relation on the left side with 5 mm of overjet and 2 mm of overbite, crowding in both upper and lower arches with crossbite in relation to the upper left first molar (26) (Figure 1 a, b). Lateral cephalometric analysis (Table 1) revealed a skeletal class I malocclusion (ANB, 2°) with hyper divergent growth pattern (SN-Go-Me, 42°), with proclined upper and lower incisors (U1 to N-A, 34°/7 mm, L1 to N-B, 26°/5mm).



a



b

Figure 1: a: Pre-treatment records **b:** Pre-treatment models.

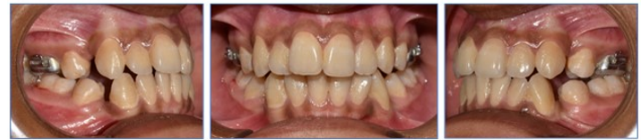

Figure 2: Intra-oral photographs after 5 months of physiological drift following all first premolar extractions.

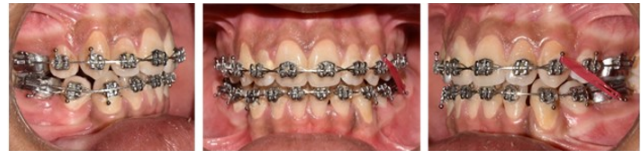

Figure 3: Mid treatment intra-oral photographs.

3. Treatment Objective

Our major goals, in this case, were to (a) level and align both upper and lower arches, (b) correct incisor inclinations, (c) achieve a bilateral Class I molar and canine relation, (d) achieve lip competency, (e) improve smile esthetics and (f) provide an aesthetic soft-tissue profile with optimum overjet and overbite.

3.1. Treatment alternative

1. Fixed orthodontic treatment after all four premolar extractions.
2. Delay bonding of both the upper and lower arches following the extraction of four first premolars to allow the teeth to drift and decrowd naturally, subsequently finish the treatment with a fixed orthodontic appliance.

3.2. Treatment progress

Since factors such as patient’s age, profile, and arch discrepancy favor the physiological drift of dentition hence, extraction of all the first premolars was decided, and the patient was referred to the Department of Oral and Maxillofacial Surgery. The patient was recalled after two weeks of extractions. A transpalatal arch (TPA) was fabricated for anchorage and correction of crossbite. TPA was expanded by 2 mm and a buccal root torque on the upper right first molar (16) was given for anchorage, so that unilateral expansion of the upper left first molar (26) can be achieved. As we had planned to resolve the anterior crowding by driftodontics, the patient was recalled for evaluation every month. After 5 months, a substantial reduction in crowding was evident, which indicated the commencement of the fixed orthodontic treatment (Figure 2).

Pre-adjusted edgewise appliance (0.022”x0.028” slot MBT prescription, 3M Unitek) was bonded in both upper

Table 1: Cephalometric analysis values of pre-treatment and post-treatment.

Sl. No.	Measurements	Range/Normal Value	Pre-Treatment	Post-Treatment
1	SNA	82°	83°	82°
2	SNB	80°	81°	80°
3	ANB	2°	2°	2°
4	N perpendicular to point A (N⊥Pt A)	0-1 mm	2 mm	2 mm
5	N perpendicular to Pogonion (N⊥Pog)	-4 to 0 mm	0 mm	-2 mm
6	Mandibular plane angle (SN-Go-Me)	32°	42°	41°
7	Angle of inclination (Pal. Plane to Pn⊥)	85°	80°	79°
8	Y-axis (S-N to S-Gn (outer angle)	66°	70°	71°
9	Facial axis angle (B-Na to Ptm-Gn) Inner angle	90°	86°	84°
10	Bjork sum (Sum of Posterior angles)	394° ± 6°	399°	402°
11	U1 to N-A (mm)	4 mm	7 mm	3 mm
12	U1 to N-A (angle)	22°	34°	24°
13	L1 to N-B (mm)	4 mm	5 mm	3 mm
14	L1 to N-B (angle)	25°	26°	23°
15	U1 to L1 (interincisal angle)	131°	116°	133°
16	Upper incisor to S-N plane	102° ± 2°	120°	98°
17	U1 to point A distance	4-6 mm	6 mm	3 mm
18	IMPA (incisor mandibular plane angle)	90°	90°	88°
19	S line to Upper lip	0-2 mm	3 mm	0 mm
20	S line to Lower lip	0-2 mm	3.5 mm	1.5 mm

and lower arches. Leveling and alignment was initiated with 0.014" and completed using 0.016" and 0.016"×0.022" NiTi archwires. For the correction of anterior tooth inclination, 0.017"×0.025" and 0.019"×0.025" SS arch wires were used. Class 2 elastics were used on a 0.019"×0.025" SS wire on the left side for proper occlusion (Figure 3). Debonding was done after 10 months of overall treatment (5 months of Driftodontics followed by 5 months of active fixed orthodontic therapy), and fixed upper and lower lingual retainers were bonded.

4. Treatment Result

A good result was achieved only in 5 months of active fixed orthodontic therapy, the outcomes were a bilateral Class I molar and canine relationship with an ideal overjet and overbite. and an aesthetic improvement in facial profile (Figure 4 a, b). Post-treatment cephalometric analysis (Table 1) showed normal inclination of the upper and lower anterior teeth (U1 to N-A, 24°/3 mm, L1 to N-B, 23°/3mm), SN-Go-Me, 41°, IMPA, 88°, fair improvement in lip competency.

The superimposition of pre- and post-treatment cephalometric tracings is shown in Figure 5. The intra-oral images of the patient at 1-year follow-up (Figure 6) revealed a stable result.

5. Discussion

Force equilibrium is the prime factor that maintains the stability of dentition. To establish balance, the tongue's physiological force, along with biting force, drives the tooth forward until the posteriorly directed counter pressure from the lips stops it. Biting pressure from opposing teeth, pressures from neighboring teeth, or forces from the tongue, cheeks, and lips, along with some stabilizing forces from the periodontal ligament and alveolar bone, aid in the maintenance of this equilibrium. However, when a tooth is extracted, the aforementioned equilibrium is disrupted, and various modifications must occur in order to achieve a proper balance.

First-premolar extractions are usually required in patients with significant anterior crowding. In orthodontic therapy, physiologic drift is critical, which is used in several orthodontic procedures, such as the Alexander and PASS systems, to make treatment easier. Fei Teng et al.⁶ in their study found that tipping was the most common type of movement during physiological drift after extraction, supporting the theory that transseptal fibres play a significant role in physiological drift. Mandibular dentition has been the topic of previous clinical studies.^{7,8} The researchers observed mesial movement of the first molar and distal movement of the canines, including tipping and

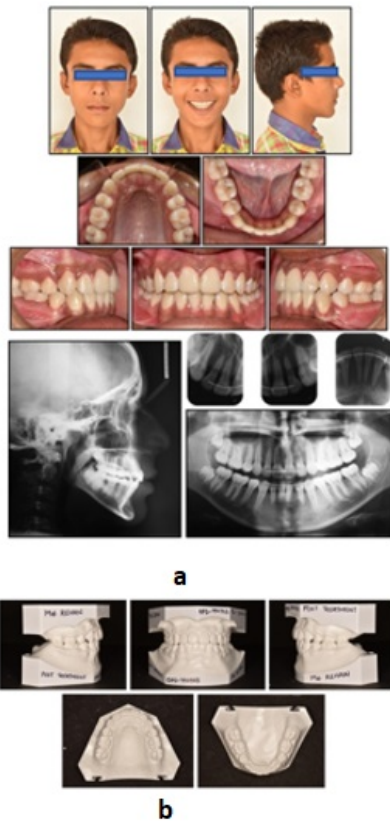


Figure 4: a: Post-treatment records. b: Post-treatment models.

translation, after the lower premolar extraction. According to Weber the mandibular canines moved distally by approximately 4.4 mm during the 2.5 years following the first premolar extraction.⁹ According to certain studies,^{10,11} the mesial drift of the first molars took up just 1/3–1/4 of the first premolar extraction sites, whereas the distal drift of the canine was responsible for the majority of the gap closure. However, studies have revealed that the movement of these lower first molars is minimal, contributing for just a tiny portion of the premolar extraction gap closing during the drift.^{9,12}

Physiologic drift is not limited to the lower arch; in fact, only a few studies have looked at physiologic drift in the maxillary dentition, and even fewer have looked at it in orthodontics. Fei Teng et al.⁶ studied maxillary dentition and found that while the pattern of physiologic drift of

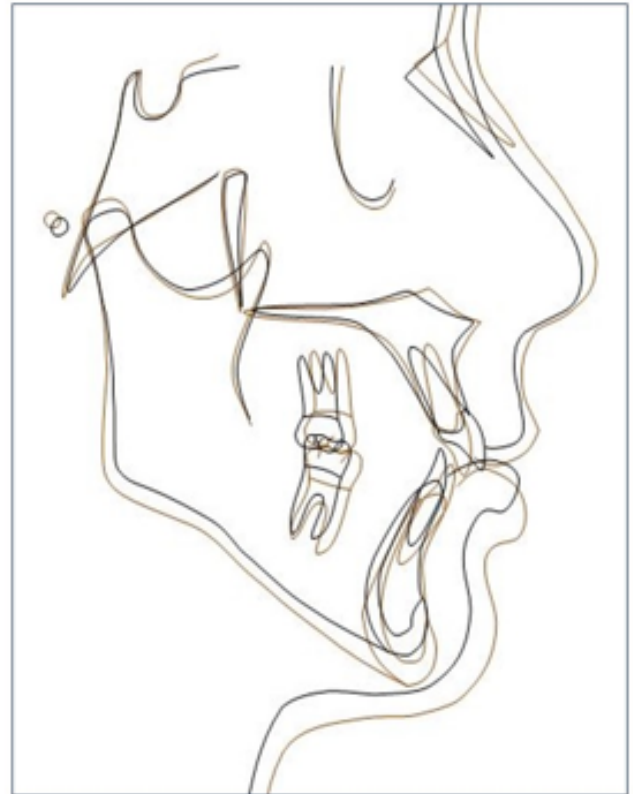


Figure 5: Superimposition (Black-Pretreatment, Red-Posttreatment)

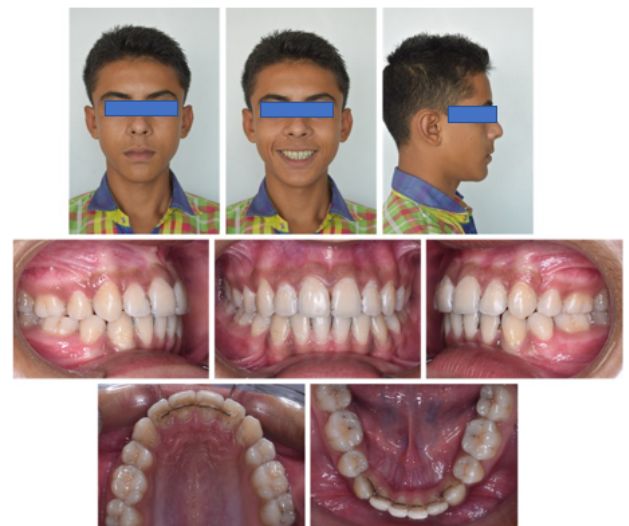

Figure 6: 1-year follow up record.

maxillary teeth was comparable to that of mandibular teeth, the pace of drift was different. They concluded that drift length, age, and crowding before the extraction were important influences on physiologic drift, however, neither gender nor angle categorization had any effect on drift.⁶ The space created by the maxillary first premolar extraction reduced by an average of 0.792 mm/month following extraction, resulting in a 4-mm decrease over 6 months.⁶

The soft tissues that surround the teeth can alter their position, yet they stay stable in the stomatognathic system's equilibrium state of forces.¹³ In younger patients, extraction spaces tended to close rapidly, and crowding had a favorable effect on space closure. Jiang Ruoping et al.¹⁴ in their study found that physiological tooth movement for individual teeth started as early as 10 days after extraction, and the amount of teeth drift continuously increased over time, and the phenomenon being detected even 240 days after the extraction. They found that molar anchor loss was more in second premolar extraction cases as compared to first premolar extraction cases especially in the first 180 days after the extraction. Age-related tissue response,¹⁵ osteoclastic activity,¹⁶ and cell proliferation rate¹⁷ may explain the higher drift in the young population. Certain exogenous factors such as common prescription drugs, smoking and alcohol abuse influence tooth movement as well as physical drift.

Aligner therapy is expensive and many patients cannot afford it for orthodontic correction. The outcome of therapy depends on compliance. Whatever the aesthetic value of the aligner is, some patients especially the younger group do not like having a foreign object inside their oral cavity.

6. Conclusion

In Driftodontics since the teeth align with each other without the use of any external orthodontic force and the patient can enjoy their regular oral activities, it should be considered as a treatment option when developing a treatment plan.

7. Source of Funding

None.

8. Conflict of Interest


None.

References

- Zheng M, Liu R, Ni Z, Yu Z. Efficiency, effectiveness and treatment stability of clear aligners: A systematic review and meta-analysis. *Orthod Craniofac Res.* 2017;20(3):127–60.


- Rossini G, Parrini S, Castroflorio T, Deregibus A, Debernardi CL. Efficacy of clear aligners in controlling orthodontic tooth movement: a systematic review. *Angle Orthod.* 2015;85(5):881–9.
- Bourdet M. *Researches et Observations. Sur toutes les parties de l'art du Dentiste.* vol. 2. Paris; 1957. p. 366.
- Alexander RG. The Vari-simplex discipline. Part 3: extraction treatment. *J Clin Orthod.* 1983;17(8):537–84.
- Tsourakis AK, Johnston LE. Class II malocclusion: the aftermath of a “perfect storm”. *Semin Orthod.* 2014;20(1):59–73.
- Teng F, Du FY, Chen HZ, Jiang RP, Xu TM. Three-dimensional analysis of the physiologic drift of adjacent teeth following maxillary first premolar extractions. *Sci Rep.* 2019;9(1):1–2.
- Campbell-Wilson M. Preliminary investigation into the movement of the lower labial segment following loss of first premolars. *Brit J Orthod.* 1975;2(1):25–33.
- Stephens CD. The rate of spontaneous closure at the site of extracted mandibular first premolars. *Br J Orthod.* 1983;10(2):93–100.
- Weber AD. A longitudinal analysis of premolar enucleation. *Am J Orthod Dentofac Orthop.* 1969;56(4):394–402.
- Proffit WR. Equilibrium theory revisited: factors influencing position of the teeth. *Angle Orthod.* 1978;48(3):175–86.
- Williams R, Hosila FJ. The effect of different extraction sites upon incisor retraction. *Am J Orthod Dentofac Orthop.* 1976;69(4):388–410.
- Glauser RO. An evaluation of serial extraction among Navajo Indian children. *Am J Orthod Dentofac Orthop.* 1973;63(6):622–54.
- Weinstein S, Haack DC, Morris LY, Snyder BB, Attaway HE. On an equilibrium theory of tooth position. *Angle Orthod.* 1963;33(1):1–26.
- Jiang R, Teng F, Du F, Chen H, Xu TM. Drift dentition and low-friction appliance. In: and others, editor. *Physiologic Anchorage Control: A New Orthodontic Concept and its Clinical Application.* Springer; 2017. p. 103–20.
- Göz G. The age dependence of the tissue reaction in tooth movements. *Fortschr Kiefer orthop.* 1990;51(1):4–7.
- Li X, Li M, Lu J, Hu Y, Cui L, Zhang D, et al. Age-related effects on osteoclastic activities after orthodontic tooth movement. *Bone Joint Res.* 2016;5(10):492–501.
- Kyomen S, Tanne K. Influences of aging changes in proliferative rate of PDL cells during experimental tooth movement in rats. *Angle Orthod.* 1997;67(1):67–72.

Author biography

Yash Agarwal, Consultant Orthodontist  <https://orcid.org/0000-0002-6082-2247>

Mukesh Kumar, Professor  <https://orcid.org/0000-0002-6000-3321>

Manish Goyal, Professor and Head  <https://orcid.org/0000-0002-0187-723X>

Atam Jain, Senior Lecturer  <https://orcid.org/0000-0001-9593-4356>

Md Abrar, Consultant Orthodontist  <https://orcid.org/0000-0002-9706-5438>

Cite this article: Agarwal Y, Kumar M, Goyal M, Jain A, Abrar M. Driftodontics: A neglected treatment approach. *J Contemp Orthod* 2023;7(2):150–154.