

Reliability and Accuracy of Tweed's Triangle, Mandibular Length & Corpus Size on Lateral 2D Cephalogram and 3D CBCT Scan

To cite: Renuka A. Patel, Ashish B. Panday, Falguni N. Mehta, Vimal S. Parmar, Vishal D. kathiriya

Reliability and Accuracy of Tweed's Triangle, Mandibular Length & Corpus Size on Lateral 2D Cephalogram and 3D CBCT Scan

J Contemp Orthod 2020;4(3): 36-43

Received on: 28-08-2020

Accepted on: 18-09-2020

Source of Support: Nil

Conflict of Interest: None

¹Renuka A. Patel, ²Ashish B. Panday, ³Falguni N. Mehta, ⁴Vimal S. Parmar, ⁵Vishal D. kathiriya

¹Professor, ³Professor & H.O.D ^{2,4,5}Postgraduate Student

^{1,2,3,4,5}Department of Orthodontics & Dentofacial Orthopaedics, Government Dental college & hospital, Ahmedabad

ABSTRACT

Objectives- To assess the precision and reliability of Tweed's Triangle and effective mandibular length, corpus size on 2 dimensional conventional lateral cephalogram and 3D CBCT scan.

Methods - 30 male adults are selected for (group A) - manual tracing, (group B) - on screen digitized tracing by software for lateral 2D cephalogram, & (group C)- digital tracing by software for 3D CBCT scan for angular measurements of Tweed's Triangle (FMA, IMPA, FMIA) and linear measurements of effective mandibular length (Co-Gn) and corpus size(Go-Gn).

Results- Statistical analysis by ANOVA and post HOC-LSD test reveals significant difference for FMA ($p < 0.022$), IMPA ($p < 0.013$) and highly significant for FMIA ($p < 0.000$) in Tweed's Triangle. Statistically highly significant difference for effective mandibular length ($p < 0.000$) and non-significant difference for mandibular corpus size between 2D conventional cephalogram and 3D CBCT scan, with lesser value for 3D CBCT analysis. However, nonsignificant difference between manual and digital tracing for angular and linear measurements on 2D cephalogram.

Conclusions -3D CBCT scan for Tweed's triangle, effective mandibular length and corpus size can be more precise and reliable for diagnosis and treatment planning.

Keywords-

Lateral cephalogram, Tweed's triangle, Effective mandibular length, Mandibular corpus size, 3D CBCT scan.

INTRODUCTION

Moyer's et al defined cephalogram for abstracting the human skull in measurable geometric scheme, which have "errors of projection" with distortion and differential magnification of craniofacial structure. In conventional 2-dimensional lateral cephalogram, bilateral landmarks usually give a dual image and 3D structures are usually defined on 2D views, so there are "errors of identification " and less accuracy of measurements. Manual tracing is more time consuming, digital tracing by software is good option by adjusting contrast and grey scale for better landmark identification. But in the current scenario, new generation of CT scans has gained access in Dentistry, are efficient to resolve the limitations and controversy and may be of great help for transition of 2D cephalometric analysis to 3D analysis. Hence, the present study was performed to analyse angular measurements of Tweed's Triangle (FMA, IMPA, FMIA) and linear measurements of effective mandibular length (Co-Gn), mandibular corpus size (Go-Gn) by manual tracing and digital tracing with CS v 6.14.3 software on lateral 2 dimensional cephalogram with 3D CBCT scan by using CS v

9300 v 3.5.18.0 software to assess the compatibility of 3D CBCT scan with 2D cephalograms to find out a method for obtaining normative values for 3D cephalometric analysis. 2D cephalometric norms could be readily used for 3D qualitative analysis if correlated for cephalogram distortion.

MATERIAL & METHODS

The present study was conducted for 30 subjects in the age range (18 – 25 years) with Angle's Class I molar & canine relation bilaterally, normal overjet and overbite, well aligned arches and no previous history of orthodontic treatment, surgery, trauma. It was approved by the ethical committee.

ARMAMENTARIUM

Carestream (CS 9300 v 3.5.18.0) Point of Care 3D CT (Carestream Health, Rochester, NY, USA). CS 9300 all in one imaging system for obtaining 2D conventional lateral cephalogram as well as CBCT derived 3D lateral cephalogram, CS 9300 v 3.5.18.0. software for digital tracing of CBCT derived 3D lateral cephalogram.

METHOD

2D Conventional Lateral cephalogram was obtained with CS 9300 all in one imaging system, which offers CBCT, panoramic and Cephalometric imaging in one system. The distance from source to midsagittal plane was 152.4 cm (5 feet). A photostimulable phosphor plate was used as detector and positioned 11.5 cm from the mid-sagittal plane. The subjects were positioned in a cephalostat by fixing between ear rods in natural head position with Frankfort horizontal plane parallel to the floor and mid-sagittal plane perpendicular

11.26 sec, voxel size of $300 \times 300 \times 300 \mu\text{m}$. The subjects were oriented by adjustment of the chin support in natural head position with Frankfort horizontal plane parallel to the floor and the mid-sagittal plane perpendicular to the floor. A single 360° rotation, 11.26 sec scan, comprising 306 basis projection were made of each skull with a 17.0 cm (diameter) \times 13.5 cm (height) field of view (figure 1). (and in this field view cephalometric landmarks are located and measurements can be derived without full skull CBCT imaging).

Table (1): Descriptive statistics of all parameters for -Group A, B & C

CEPHALOMETRIC PARAMETER	N	MEAN	STD. DEVIATION	STD. ERROR	MAX VALUE	MIN. VALUE	CONFIDENCE INTERVAL (95%)
GROUP A							
FMA	30	19.7	4.7	0.867	24	9	18.03 - 21.36
IMPA	30	95.5	7.1	1.31	111	85	93 - 98.06
FMIA	30	64.8	8.4	1.528	77	49	61.8 - 67.8
Co-Gn	30	111.200	4.4983	0.850	122	107	109.70 - 112.83
Go-Gn	30	75.300	3.4600	0.638	83	72	74.23 - 76.53
GROUP B							
FMA	30	19.5	4.9	0.913	24.1	8.6	17.50 - 21.04
IMPA	30	97.1	6.8	1.23	111.8	87.4	95.26 - 99.82
FMIA	30	63.4	8.14	1.486	74.8	48.1	60.5 - 66.3
Co-Gn	30	110.890	4.2816	0.808	120.6	105.8	108.98 - 112.31
Go-Gn	30	73.250	3.2000	0.619	80.7	69.8	72.15 - 74.54
GROUP C							
FMA	30	22.7	5.1	0.922	27.4	11.2	20.75 - 24.35
IMPA	30	100.8	7.0	1.280	115.7	90.4	98.37 - 103.44
FMIA	30	56.5	8.73	1.5943	66.7	40.2	53.4 - 59.6
Co-Gn	30	106.360	4.5543	0.857	116.0	101.2	104.74 - 108.10
Go-Gn	30	73.150	3.5000	0.640	82.2	70.4	73.96 - 76.27

Intergroup comparison by one-way ANOVA test (Table 2) (figure 6 & 7) shows statistically significant values for FMA, IMPA and highly significant for FMIA and Co - Gn.

to the floor. The digital lateral cephalometric images were then printed with Carestream Dry view 5700 Laser Imager on $8'' \times 10''$ (20×25 cm) high-quality blue 7-mil polyester 31 base T-MAT films (to avoid absorption spreading), at a scale of 1:1 to avoid magnification error.

For same subject, CBCT image was acquired with CS 9300 all in one imaging system which was operated at 90 kvp, 5mA and 0.7 mm nominal focal spot size with exposure time of

A simulated 3D Lateral Cephalogram was produced by adjusting sagittal reference plane on the axial image to coincide with midpoint of sella turcica and increasing the slice thickness from $899 \mu\text{m}$ (figure 2) to 168.3 mm. Finally, CBCT scan of slice thickness of 168.3 mm was derived (figure 3).

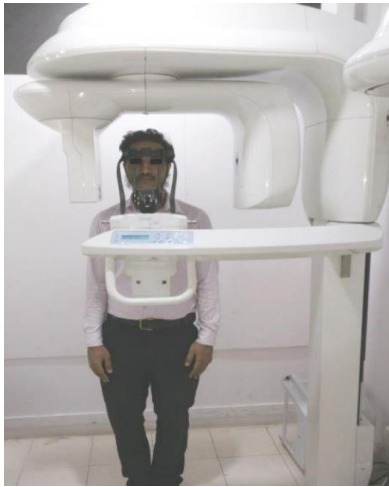

Fig. 1: Single 360° rotation for CBCT scan

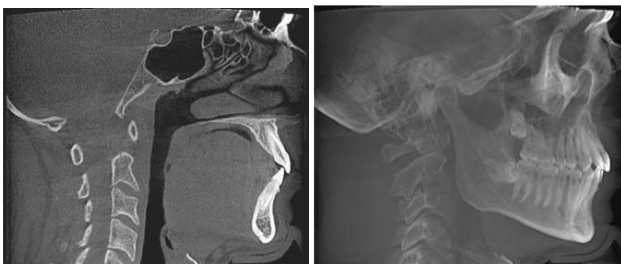

Fig. 2: CBCT scan at slice thickness. **Fig. 3:** CBCT scan at slice thickness of 168.3mm of 899 μm

Angular measurements of Tweed's triangle.

FMA- It is anterior-inferior angle formed by Frankfort Horizontal plane and Mandibular plane.

IMPA- formed by the intersection of mandibular plane with a line passing through incisal edge and apex of root of the mandibular central incisor.

FMIA- formed by intersection of line passing through incisal edge and apex of the root of mandibular central incisor with Frankfort Horizontal plane.

Linear measurement

Effective mandibular length (Co-Gn): The straight-line distance between Condylion and Gnathion.

Mandibular Corpus Size (Go-Gn): Linear distance between Gonion & Gnathion.

All subjects were evaluated for different tracing techniques in three groups as follows:

Group A: Tracing was done manually on 0.36 μm acetate sheet of paper using 0.5 mm lead pencil for angular measurements of Tweed's triangle (FMA, IMPA, FMIA) and linear measurements of effective mandibular length and corpus size for 2D conventional lateral cephalogram.

Group B: Dental Imaging Software CS v 6.14.3 for on screen

digitized 2D conventional lateral cephalogram. Craniofacial structures and cephalometric landmarks were automatically drawn and located by the program.

Group C: 3D lateral cephalogram was derived by importing 3D CBCT in DICOM format (Digital Imaging and Communication in Medicine) and digital tracing by CS 3D Dental Imaging software v 3.5.18.0.(figure 4).

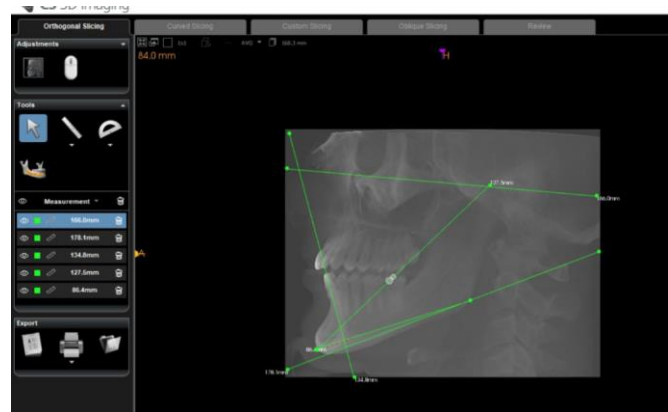


Fig. 4: Digital tracing of CBCT derived 3D lateral cephalogram using cs Imaging v3.5.18.0

RESULTS & DISCUSSION

RESULTS

Data was collected for 30 male adult subjects in 3 groups. Statistical analysis was done by SPSS version 22. Table 1 shows descriptive statistics for angular measurement of Tweed's triangle and linear measurement of effective mandibular length and corpus size. FMIA has more standard deviation and error as well as effective mandibular length in all the groups.

Post-hoc LSD test reveals that mean score of FMA angle is more in Group C which is statistically significant ($p \leq 0.021$) and the results of a Pearson correlation and two tailed T test shows significant positive correlation between manual tracing for 2D cephalogram and digital tracing for 3D CBCT Scan [$p = 0.0213^*$], greater values in 3D CBCT Scan. On comparing between Group B ($M = 19.5^\circ \pm 4.9^\circ$) and C [$M = 22.7^\circ \pm 5.1^\circ$] is also statistically significant ($p \leq 0.013$), with positive correlation [$p = 0.0160^*$] between the 2D cephalogram and 3D CBCT Scan [$r = 0.242, p = 0.022^*$].

Statistically significant ($p \leq 0.004^*$) difference of IMPA with the mean score of Group A ($M = 95.5^\circ \pm 7.1^\circ$) and C [$M = 100.8^\circ \pm 7^\circ$], significant positive correlation between manual tracing of 2D cephalogram and digital tracing for 3D CBCT Scan [$r = 0.971, p = 0.005^{**}$] and greater value found for 3D CBCT Scan.

Likewise, between Group B ($M = 97.1 \pm 6.8$) and C [$M = 100.8^\circ \pm 7^\circ$] which is also statistically significant ($p \leq 0.044^*$) and positive correlation between software tracing of 2D and 3D

CBCT Scan [$r = 0.986, p = 0.0437^*$].

FMIA is statistically highly significant ($p \leq 0.0004^*$) with mean score for Group A ($M = 64.8^\circ \pm 8.4^\circ$) and C [$M = 56.5^\circ \pm 8.73^\circ$], positive correlation between manual tracing of 2D cephalogram and digital tracing for 3D CBCT Scan [$r = 0.972, p = 0.0004$], lesser values found in 3D CBCT Scan, Similarly in group C than B with the mean score for Group B ($M = 63.4 \pm 8.14^\circ$) and C [$M = 56.5^\circ \pm 8.73^\circ$] which is also highly significant ($p \leq 0.0024^*$) and positive correlation between 2D cephalogram and 3D CBCT Scan [$r = 0.988, p = 0.0024$].

Effective mandibular length is statistically highly significant ($p \leq 0.00^*$) with mean score for Group A ($M = 111.2 \text{ mm} \pm 4.49 \text{ mm}$) and C [$M = 106.36 \text{ mm} \pm 4.55 \text{ mm}$] and significant negative correlation between manual tracing for 2D cephalogram and digital tracing for 3D CBCT Scan [$r = -0.397, p = 0.0001^{**}$], lesser values are found in 3D CBCT Scan. similarly, between Group B ($M = 110.89 \text{ mm} \pm 4.28 \text{ mm}$) and C [$M = 106.36 \text{ mm} \pm 4.55 \text{ mm}$] which is statistically highly significant ($p \leq 0.00^*$) with negative correlation between software tracing for 2D and 3D CBCT Scan [$r = -0.960, p = 0.0002^{**}$].

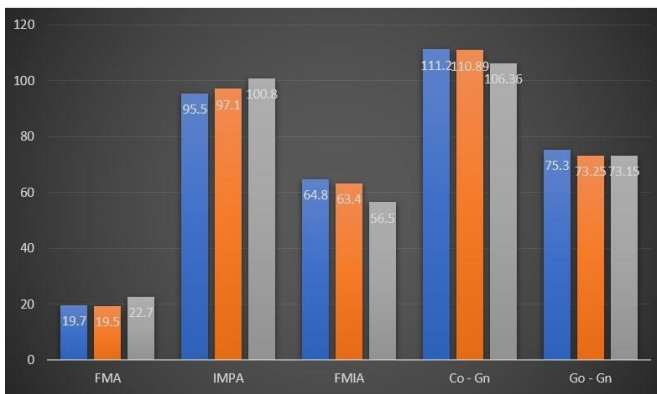


Fig. 5: Graph shows Comparison of mean values of tweed's triangle and linear parameters for all the groups+

DISCUSSION

2D cephalometry is one of the important diagnostic tool for treatment planning, but for linear & angular measurements, the use of 2D views in the analysis of 3D objects can cause overlapping of structures and lead to landmark identification errors. Which has in turn led to a search for new techniques - CBCT modalities that have come into use over the past decade have been found to overcome the limitations associated with traditional cephalometric analysis. CBCT have been used for orthodontic patients but the lack of 3D standard population norms has restricted CBCT from routine orthodontic use. For using database of information linking 2D standardized cephalogram to orthodontic diagnosis, treatment planning and outcomes, cephalometric measurements

performed on 3D CBCT Scan may be compatible with measurements on conventional cephalograms. So, present study was conducted to analyse the accuracy & reliability of angular measurement of Tweed's triangle & linear measurement of mandible to check the null hypothesis of 2D cephalometric measurement traced manually and by software with CBCT derived 3D cephalogram.

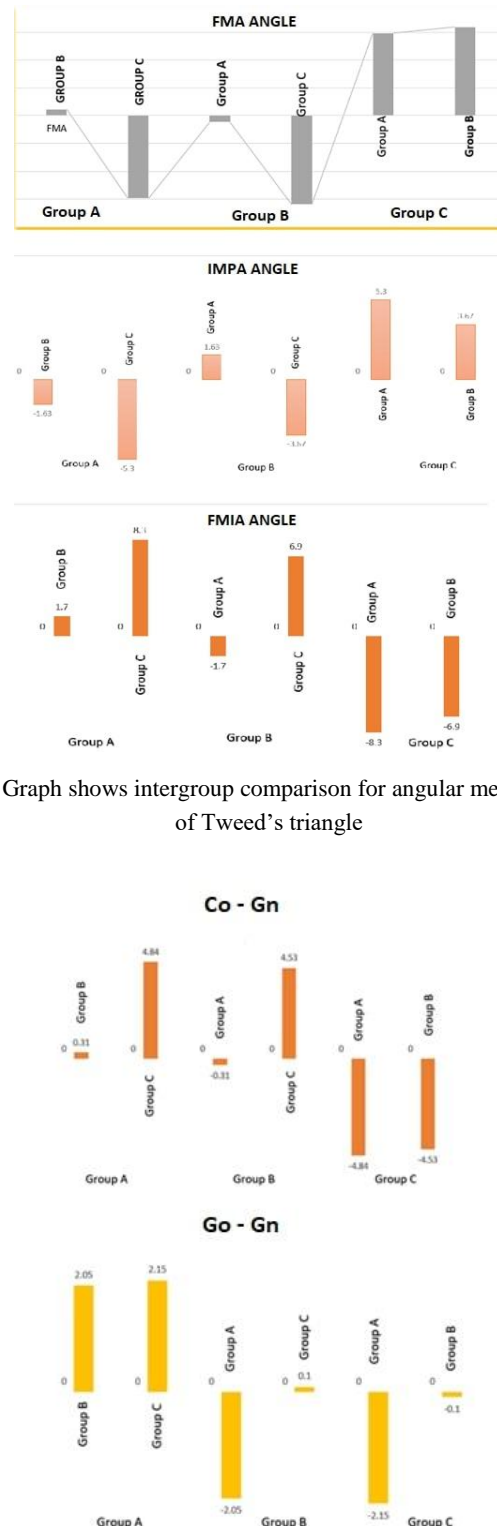


Fig. 6: Graph shows intergroup comparison for angular measurements of Tweed's triangle

Fig.7:Graph shows intergroup comparison for linear measurements

FMA angle shows statistically significant difference within group [$p \leq 0.022^*$] which is in accordance with the findings of V Kumar *et al.*¹ but this contradicts the findings of N Farhadian *et al.*², Mauricio Barbosa *et al.*³.

accurately.

Incisor Mandibular Plane Angle (IMPA) is statistically significant within the groups [$p \leq 0.013^*$] which is in agreement with Olivier J. C. *et al.*⁴ and Mauricio Barbosa *et al.*³ but this dispute the R Nalcaci⁵, Olivier J. C. *et al.*⁶, Farhadian *et al.*² and

TABLE (2): INTERGROUP COMPARISON OF ALL PARAMETERS

		Sum of squares	Df	Mean square	F	Sig.
FMA	Between group	190.454	2	95.227	4.001	0.022*
	Within group	2070.771	87	23.802		
	Total	2261.225	89			
IMPA	Between group	442.158	2	221.079	4.568	0.013*
	Within group	4210.323	87	48.395		
	Total	4652.481	89			
FMIA	Between group	1181.018	2	590.509	8.3306	0.0049**
	Within group	6166.938	87	70.8843		
	Total	7347.956	89			
CO – GN	Between group	440.426	2	220.213	11.139	0.000**
	Within group	1719.939	87	19.769		
	Total	2160.365	89			
GO – GN	Between group	72.611	2	36.306	3.157	0.058
	Within group	966.035	84	11.500		
	Total	1038.646	86			

*-Statistically Significant (P<0.05), **-Highly Significant (P<0.01), NS-Not Significant(P>0.05)

Non-significant positive correlation is seen between manual tracing and software tracing for 2D cephalogram [$r = 0.987$, $p = 0.859$]. FMA angle shows greater standard error in 3D CBCT Scan.

V Kumar *et al.*¹ stated that the landmarks like Porion which define the Frankfort horizontal plane have greater margins of error. Superimposition of the bilateral middle ear and other temporal fossa structures makes it difficult to locate the anatomic Porion and so influences the measurement of FMA angle.

While viewing three dimensions anatomy, it is evident that accurate landmarks often do not exist. The sharp edges seen in 2D projections are replaced by surfaces and curves in the 3D rendering images so landmarks like Porion and orbitale, which located on curved surfaces are difficult to identify

Chang *et al.*⁷.

In our study non-significant positive correlation is found between manual tracing and software tracing for 2D cephalogram [$r = 0.994$, $p = 0.366$]. IMPA angle has a more standard error in Group A than Group C and B.

Olivier J. C. *et al.*⁶ found significant difference which were less than the standard error and hence clinically acceptable. They stated that an explanation for this could be that in the 3D models the angle between two planes were calculated, compared with angle between two lines in conventional cephalometry. So, there was a chance that the planes have a different orientation compared with the corresponding lines, so different angle with other planes compared with the use of the lines.

The difference between mandibular contours of 2D Digital Cephalometric & 3D CBCT images are noticed which probably

contributed to the difference between the two-measurement method.

Table 3 & 4 depicts post hoc LSD test and Pearson correlation between groups for significant parameters.

Table (3): Post hoc LSD test for intergroup comparison in significant parameters

Parameter	Group(I)	Group(J)	Mean Difference (I – J)	Sig.
FMA	Group A	Group B	0.220	0.862
		Group C	-2.9700*	0.021
	Group B	Group A	-0.2200	0.862
		Group C	-3.1900*	0.013
	Group C	Group A	2.9700*	0.021
		Group B	3.1900*	0.013
IMPA	Group A	Group B	-1.6300	0.367
		Group C	-5.3000*	0.004
	Group B	Group A	1.6300	0.367
		Group C	-3.6700*	0.044
	Group C	Group A	5.3000*	0.004
		Group B	3.6700*	0.044
FMIA	Group A	Group B	1.7	0.529
		Group C	8.3**	0.0004
	Group B	Group A	-1.7	0.529
		Group C	6.9*	0.0024
	Group C	Group A	-8.3**	0.0004
		Group B	-6.9	0.0024
Co – Gn	Group A	Group B	0.3100	0.788
		Group C	4.8400*	0.000
	Group B	Group A	-0.3100	0.788
		Group C	4.5300*	0.000
	Group C	Group A	-4.8400*	0.000
		Group B	-4.5300*	0.000
Go – Gn	Group A	Group B	2.05	0.838
		Group C	2.15	0.8676
	Group B	Group A	-2.05	0.838
		Group C	0.1	0.1212
	Group C	Group A	-2.15	0.8676
		Group B	-0.1	0.1212

* - Statistically significant (P<0.05), **. The mean difference is significant at the 0.05 level.

Frankfurt Mandibular Incisor Angle (FMIA) is statistically highly significant within the groups [F (2,87) = 8.330, $p \leq 0.0049^{**}$]. This contradicts the findings of R Nalcaci⁵, N Farhadian et al², Chang et al⁷.

In the present study, non-significant positive correlation is observed between manual tracing and software tracing for 2D cephalogram [r = 0.992, p = 0.529]. There is greater standard error in Group C than Group A and B.

more than those that were closer to the film. A point which is placed outside the mid-sagittal plane is difficult to locate accurately on 2D cephalogram which results in shortening due to projection of these oblique distance. CT scan provides more precise evaluation of linear measurements. U Oz et al.¹⁰ stated difficulties in identification and measurements of landmarks located on the curved surface (such as Go and Co) from CBCT generated cephalogram are still prone to error. Secil Aksoy et al.¹¹ found that the 2D and 3D generated cephalograms from

Table (4): Pearson correlation between groups for all parameters

Group A & B	FMA	IMPA	FMIA	Co – Gn	Go – Gn
N	60	60	60	60	60
Pearson correlation	0.987	0.994	0.992	0.9551	0.9399
Sig.(2 – tailed)	0.859	0.366	0.529	0.785	0.0838
Group A & C					
Pearson correlation	0.963	0.971	0.972	0.957	0.966
Sig.(2 – tailed)	0.0213*	0.0050*	0.0004*	0.0001*	0.8676
Group B & C					
Pearson correlation	0.982	0.986	0.988	0.961	0.865
Sig.(2 – tailed)	0.0160*	0.0437*	0.0024*	0.0002*	0.1213
*. Correlation is significant at the 0.05 level (2-tailed).					

Effective Mandibular length (Co-Gn) is statistically highly significant within the groups [F(2,87) = 11.139, $p \leq 0.000^{**}$] which is in accordance with V Kumar et al.⁸, HuseyinOlmez et al.⁹, U Oz et al.¹⁰ and SecilAksoy et al.¹¹. But not according to findings of Danielle R et al.¹² and Bruno et al.¹³.

However non-significant negative correlation is observed between the manual tracing and software tracing for 2D cephalogram [r = -0.499, p = 0.785].

Effective mandibular length has greater standard error in Group C than Group A and B.

V Kumar et al.⁸ found linear mid-sagittal measurements were significantly greater than skull measurements for perspective CBCT because of magnification and distortion due to inability of Dolphin 3D software to simulate conventional cephalogram which exhibit a mid-sagittal magnification greater than 1:1, unlike Dolphin 3D software which simulate perspective distortion of bilateral structures only maintaining 100% magnification of mid-sagittal plane. HuseyinOlmez et al.⁹ stated that structures farthest from the film were magnified

various rendering software were similar, however measurements on curved surfaces are not easily reproducible for 3D software.

Mandibular corpus size(Go-Gn) is statistically nonsignificant, negative correlation between 2D cephalogram and 3D CBCT Scan [r = -0.018, p = 0.868] for all the groups [F(2,87) = 3.157, p = 0.058] which is in accordance with the findings of Danielle R et al.¹², N Farhadian et al.², Secil et al.¹¹.

3D cephalometric, in which the linear and angular measurements are made directly on 3D surface and volume-rendered images obtained from computed tomography (CT) scan, the accuracy of these have been previously evaluated and findings showed that direct 3D measurements are highly accurate with no significant discrepancy from physical measurements.

In our study only male adult subjects with normal occlusion are considered, so further study with more sample size and gender comparison along with other malocclusion types and full skull 3D CBCT Scan is advised to assess the intra observer and inter observer error.

CONCLUSION

Non significant difference is observed between manual tracing

and digital tracing by software for 2D conventional lateral cephalogram for angular parameters of Tweed's triangle (FMA, IMPA, FMIA) and linear measurements of effective mandibular length and corpus size. On comparing between 2D lateral cephalogram & 3D CBCT Scan, which reveals significant greater value of FMA and IMPA whereas highly significant lesser value of FMIA in 3D CBCT. Lesser value is found for linear measurements in 3D CBCT scan, however effective mandibular length is statistically highly significant but mandibular corpus size is non-significant.

- This discrepancy may be due to technical specifications and magnification error of 2D and 3D images, distortion in curved surface, bilateral landmarks (anatomic Porion, orbitale, Condylion, gonion) and unilateral landmark (gnathion). 3D CBCT scan provides more precise landmark, so less chances of identification error.

- Based on recognized 2D cephalometric norms to shift the conversion from 2D to 3D cephalometric analysis by using derived mathematical data design of distortion/magnification error and identification error for 3D analysis is needed.

References

1. Vandana Kumar; John Ludlow; Lucia Helena Soares Cevidanes, Andre' Mol. In Vivo Comparison of Conventional and Cone Beam CT Synthesized Cephalograms. *Angle Orthodontist*, Vol 78, No 5, 2008; 873-879.
2. N. Farhadian, A. Miresmaeili and R. Mahvelati, A.Sajedi. A comparative cephalometric analysis between conventional and CBCT generated lateral cephalograms. *Iranian Journal of Orthodontics*, Vol. 7, 2012, 22-26.
3. Maurício Barbosa Guerra da Silva, Bruno CabúsGois and Eduardo Franzotti Sant Anna. Evaluation of the reliability of measurements in cephalograms generated from cone beam computed tomography. *Dental Press J Orthod*. 2013 JulyAug;18(4):53-60.
4. O. J. C. van Vlijmen, T. Maal, S. J. Berge, E. M. Bronkhorst, C. Katsaros, A. M. Kuijpers-Jagtman. A comparison between 2D and 3D cephalometry on CBCT scans of human skulls. *Int. J. Oral Maxillofac. Surg*. 2010; 39: 156–160.
5. R Nalcaci, F Ozturk, O Sokucu. A comparison of twodimensional radiography and three dimensional computed tomography in angular cephalometric measurements. *Dentomaxillofacial Radiology* (2010) 39, 100–106.
6. Olivier J.C. van Vlijmen, Stefaan J. Bergé, Gwen R.J. Swennen, Ewald M. Bronkhorst, Christos Katsaros and Anne M. KuijpersJagtman. Comparison of Cephalometric Radiographs Obtained From Cone-Beam Computed Tomography Scans and Conventional Radiographs. *American Association of Oral and Maxillofacial Surgeons: J Oral MaxillofacSurg* 2009-67; 92-97.
7. Chang-Seo Park, Jae-Kyu Park, Huijun Kim, Sang-Sun Han, Ho-Gul Jeong and Hyok Park. Comparison of conventional lateral cephalograms with corresponding CBCT radiographs. *Imaging Sci Dent* 2012; 42 : 201-5.
8. V Kumar, JB Ludlow, A Mol and L Cevidanes. Comparison of conventional and cone beam CT synthesized cephalograms. *Dentomaxillofacial Radiology* (2007) 36, 263–269.
9. HuseyinOlmez, Serkan Gorgulu, Erol Akin, Ali Osman Bengi, Ibrahim Tekdemir and FatihOrs. Measurement accuracy of a computer-assisted three-dimensional analysis and a conventional two-dimensional method. *Angle Orthod*. 2011;81:375–382.
10. U Oz, K Orhan and N Abe. Comparison of linear and angular measurements using two dimensional conventional methods and three-dimensional cone beam CT images reconstructed from a volumetric rendering program in vivo. *Dentomaxillofacial Radiology* (2011) 40, 492–500.
11. Secil Aksoy, UmayKelahmet, EvrenHincal, Ulas Oz and Kaan Orhan. Comparison of linear and angular measurements in CBCT scans using 2D and 3D rendering software. *Biotechnology & Biotechnological Equipment*, 2016 Vol. 30, No. 4, 777-784
12. Danielle R. Periago; William C. Scarfe; Mazyar Moshiri; James P. Scheetz; Anibal M. Silveira; Allan G. Farman. Linear Accuracy and Reliability of Cone Beam CT Derived 3- Dimensional Images Constructed Using an Orthodontic Volumetric Rendering Program. *Angle Orthodontist*, Vol 78-3, 2008; 387-395.
13. Bruno FrazaoGribel, Marcos Nadler Gribel, Diogo Campos Frazao, James A. McNamara Jr, Flavio Ricardo Manzi. Accuracy and reliability of craniometric measurements on lateral cephalometry and 3D measurements on CBCT scans. *Angle Orthod*. 2011; 81:26–35. 34.