

CASE REPORT

To cite: Tusar Kanti Nayak, Smruti Bhusan Nanda, Payada Patnaik, Lipika Mali, Abhik Sinha

Class III Malocclusion
Treatment Strategies: Case Report

J Contemp Orthod 2020;4(4): 1-5.

Received on:
20-10-2020

Accepted on:
23-11-2020

Source of Support: Nil

Conflict of Interest: None

Class III Malocclusion Treatment Strategies: Case Report

¹Tusar Kanti Nayak, ²Smruti Bhusan Nanda, ³Payada Patnaik, ⁴Lipika Mali, ⁵Abhik Sinha

¹⁻²Professor, ³⁻⁴Senior Lecturer

¹⁻⁵Institute of Dental Sciences, SOA University, Bhubaneswar.

ABSTRACT

Abstract: Class III malocclusion is highly prevalent among Asian population, especially in the form of a midface deficiency. This case report describes three such cases that have been treated using growth modification and orthodontic decompensation with orthognathic surgery. Case report 1 is of a 12 years old female patient having Angle's class III malocclusion based on skeletal class III jaw bases with 12 mm of reverse overjet, 0 mm of overbite, proclined maxillary anteriors, retroclined and crowded mandibular anteriors and rotated 13 and 23. Case report 2 describes a 12 years old male patient diagnosed with Angle's class III malocclusion based on skeletal class III jaw bases with 2 mm of reverse overjet and 5mm of overbite and anterior crossbite i.r.t. 11,12-31, 41. Case report 3 demonstrates a 22 years old male patient with Angle's class III malocclusion based on skeletal class III jaw bases with 3 mm of reverse overjet and -2 mm of overbite with proclined maxillary anteriors and retroclined mandibular anteriors; spacing in the upper anteriors and crowding in lower anteriors, with anterior crossbite. Treatment in all the cases achieved good functional stability.

Keywords: III malocclusion, Midface deficiency, Decompensation, Overjet, Crossbite.

INTRODUCTION

Prevalence of class III malocclusion was reported to be 1-3% among Caucasians, 13-14% among the Chinese and Japanese.¹⁻⁴ More than 60% of such cases are due to skeletal discrepancies.⁵ Asian countries see a higher prevalence of class III malocclusion than the west, especially in the form of a midface deficiency.⁶ Such a malocclusion could result from skeletal as well as dental compensations like mandibular prognathism, maxillary retrognathism, retrusive mandibular dentition, protrusive maxillary dentition or a combination of the aforementioned conditions.⁷ A patient with a class III malocclusion demonstrates edge-to-edge bite or a large reverse overjet which might become difficult to treat for an orthodontist.⁸⁻¹⁰ The treatment plan for a class III malocclusion aims at dental decompensation, skeletal maxillary protrusion to improve point A, backwards rotation of the mandible to reduce point B prominence, or a combination.¹¹ The management options include – growth modification, orthodontic camouflage, dental decompensation, orthodontic surgery, and bone-anchored maxillary protraction after pubertal growth spurt.^{12,13} This case report describes three such class III malocclusion cases that have been treated using – growth modification and orthodontic decompensation with orthognathic surgery.

CASE REPORT 1:

A 12 year old female patient reporting to the department of orthodontics and dentofacial orthopedics at Institute of dental sciences, Bhubaneswar was diagnosed with Angle's class III

malocclusion based on skeletal class III jaw bases with 12 mm of reverse overjet, 0 mm of overbite, proclined maxillary anteriors, retroclined and crowded mandibular anteriors and rotated 13 and 23. The pre-treatment orthopantomogram and lateral cephalograms have been shown in **Figure 1** and the intraoral and extraoral photographs in **Figure 2**. The treatment plan included extraction of the grossly decayed 26 and retained deciduous root stumps in 55 and 65.

The treatment was started with upper and lower pre-adjusted edgewise appliances (0.022" x 0.028" slot) with MBT prescription. Dental decompensation was done using the 0.014" NiTi, 0.016" NiTi, 19 x 25" NiTi and 19 x 25" SS. Facebow transfer was done before surgery (**Figure 3**) to record the orientation of maxilla and mandible, following which distraction osteogenesis of the maxilla was done using le Fort 1 osteotomy. The treatment duration was about 22 months, during which an overjet of 3 mm was achieved, with good intercuspation and the patient was satisfied with the overall progress of the treatment. The post treatment records have been shown in **Figure 4**.

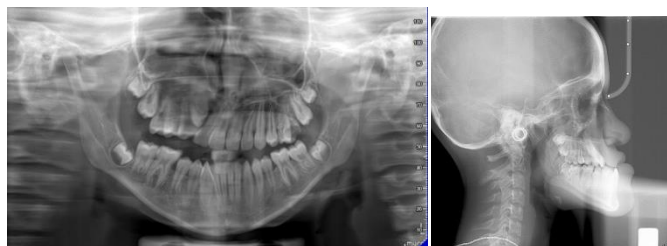

Figure 1: Pre-treatment OPG and lateral cephalogram

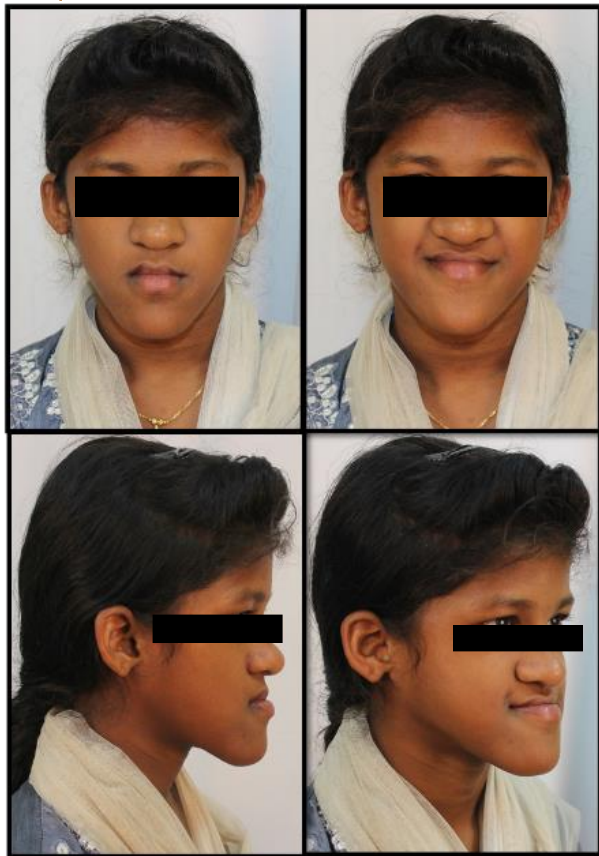

Figure 2: Pre-treatment intra-oral and extra-oral photographs.

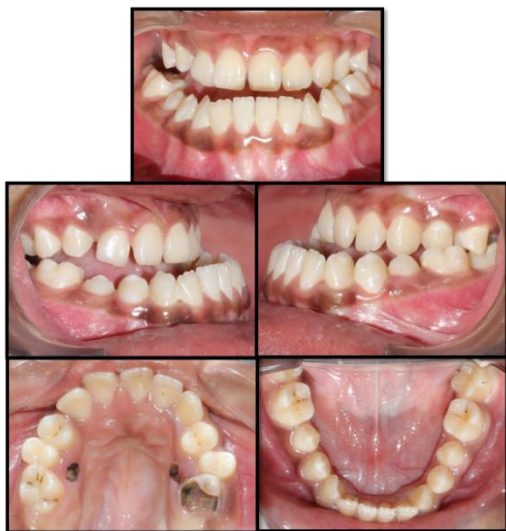

Figure 3: Facebow transfer to record the orientation of the jaws before orthognathic surgery.

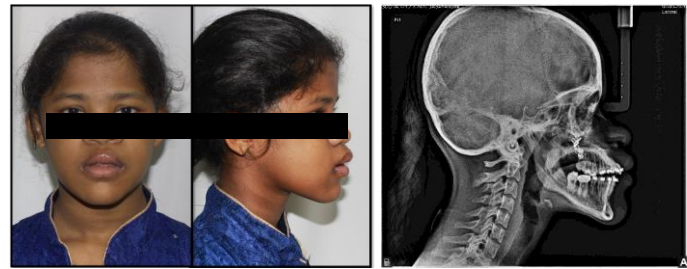


Figure 4: Post distraction osteogenesis photograph and lateral cephalogram

CASE REPORT 2:

A 12 years old male patient visited the same department and was diagnosed with Angle's class III malocclusion based on skeletal class III jaw bases with 2 mm of reverse overjet and 5mm of overbite and anterior crossbite i.r.t. 11,12-31,41. The pre-treatment OPG, lateral cephalogram are shown in **Figure 5**, intraoral and extraoral photographs were taken as shown in **Figure 6**. A non-extraction treatment plan was decided, making use of the rapid maxillary expansion with hyrax and protraction using reverse pull headgear.

The treatment proceeded with a hyrax expander placed over the patient's palate for 9 days to open the mid palatal suture. This was followed by giving the patient a reverse pull headgear which was asked to be worn for 14 hours a day for 11 months using a force of 350 gm/side as can be seen in **Figure 7**. After the maxillary expansion was achieved, upper and lower pre-adjusted edgewise fixed appliance (0.022" x 0.028" slot) with MBT prescription was used to align the arches starting with 0.012" NiTi, followed by 0.014" NiTi, 0.016 NiTi, 19 x 25 NiTi and 19 x 25 SS. The post treatment changes can be appreciated in **Figure 8**.

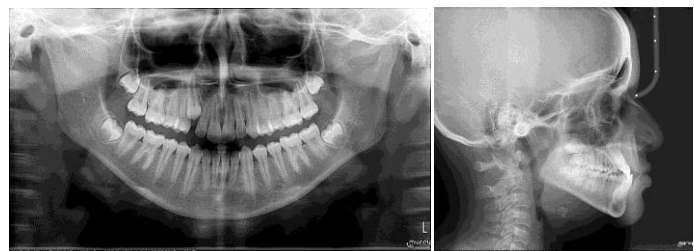


Figure 5: Pre treatment OPG and lateral cephalogram.

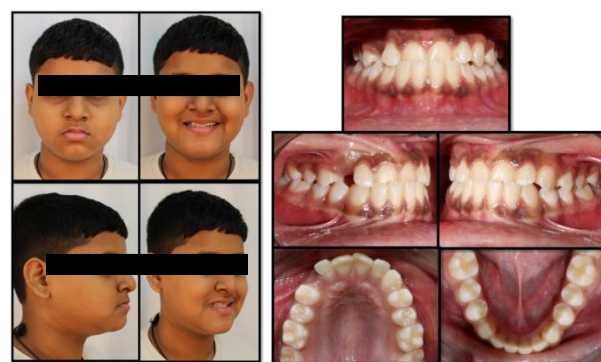


Figure 6: Pre treatment intraoral and extraoral photographs.

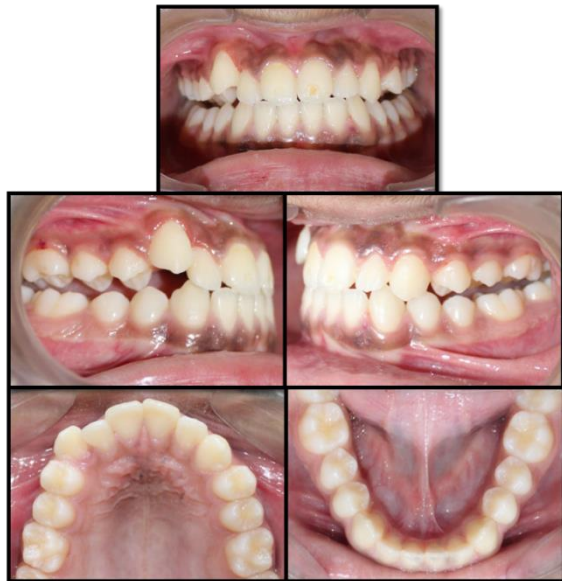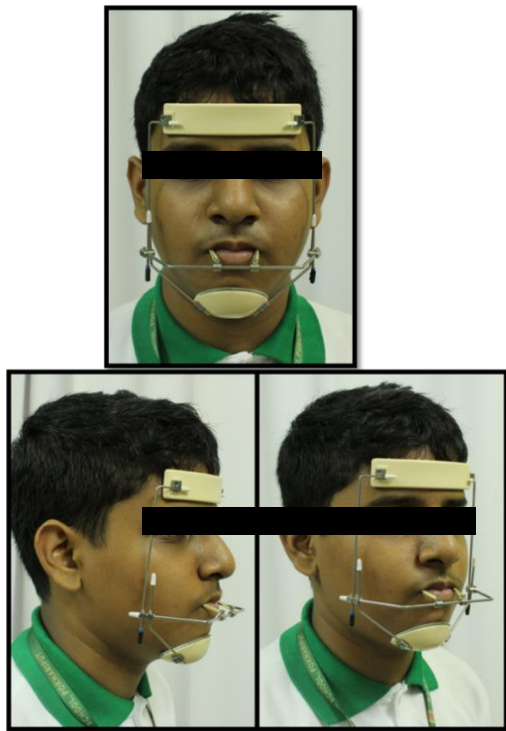


Figure 7: Reverse pull headgear being given to the patient and introral photographs showing the treatment changes with the appliance

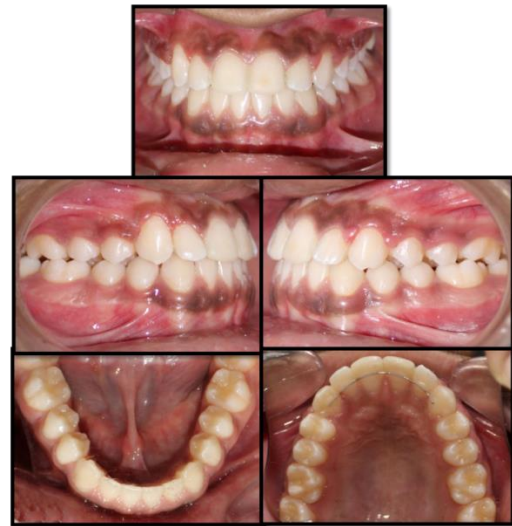

Figure 8: Post treatment intraoral and extraoral photographs

CASE REPORT 3:

A 22 years old male patient reporting to the same department was diagnosed with Angle's class III malocclusion based on skeletal class III jaw bases with 3 mm of reverse overjet and -2 mm of overbite with proclined maxillary anteriors and retroclined mandibular anteriors; spacing in the upper anteriors and crowding in lower anteriors, with anterior crossbite. The pre-treatment radiographs and intraoral as well as extraoral photographs have been shown in **Figure 9** and **Figure 10**. The treatment plan included extraction of 14 and 24 with dental decompensation, followed by orthognathic surgery with le Fort I in the maxillary arch and BSSO in the mandibular arch.

The treatment proceeded with bonding of teeth using upper and lower pre-adjusted edgewise fixed appliances (0.022" x 0.028" slot) with MBT prescription. The initial wire was 0.014" NiTi. This was followed with 0.016" NiTi, 19 x 25 NiTi and 19 x 25 SS. After the levelling alignment helped achieve dental decompensation (**Figure 11**), facebow transfer of the patient was done to record the orientation of the maxilla and mandible. The orthognathic surgery was finally done with le Fort I in the maxillary arch and BSSO in the mandibular arch followed by post-surgical orthodontics to achieve the desired treatment results as can be seen in **Figure 12** and **Figure 13**.

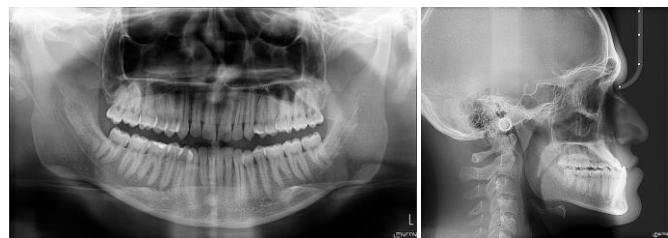

Figure 9: Pre treatment OPG and lateral cephalogram

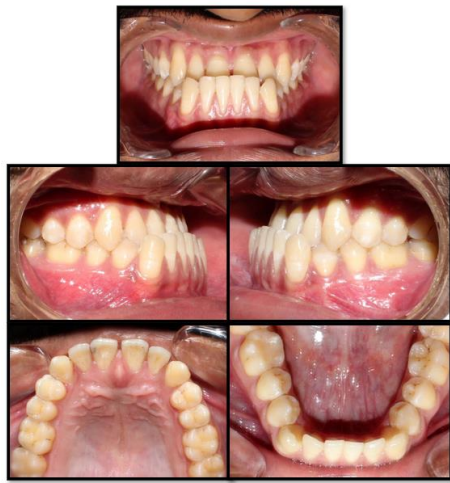


Figure 10: Pre treatment intraoral and extraoral photographs.

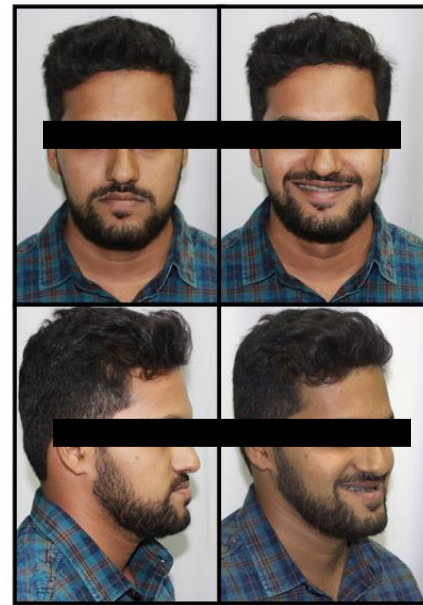
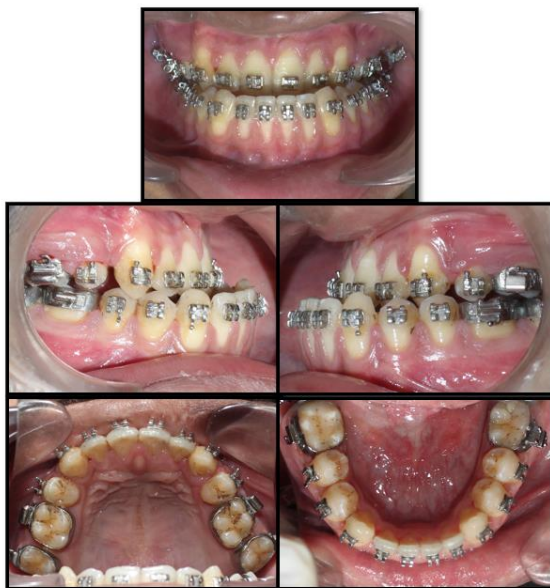

Figure 11: Pre-surgical orthodontics to obtain levelling and alignment and dental decompensation

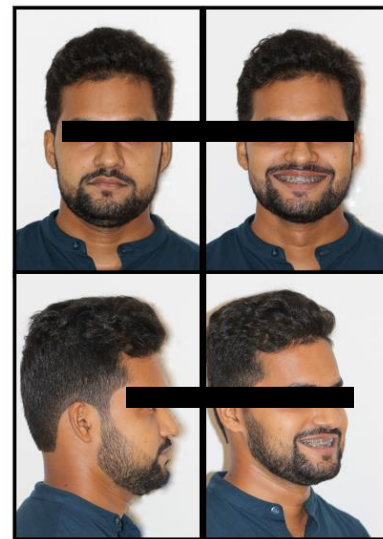
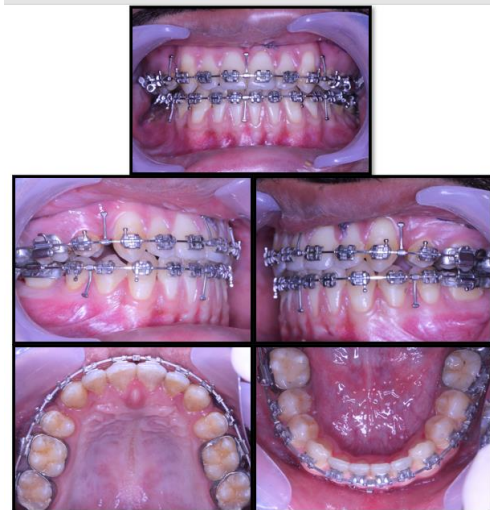
Figure 12: Post-surgical intraoral and extraoral photographs

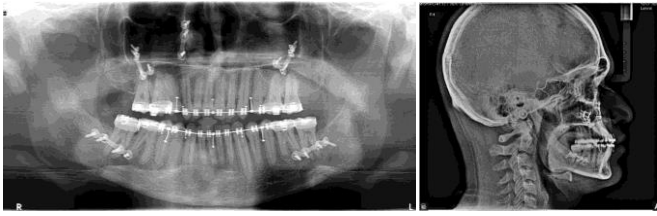


Figure 13: Post surgical OPG and lateral cephalogram

CONCLUSION

Orthodontic limitations in a class III patient has to be identified early to determine whether an orthodontic camouflage can be performed or an orthognathic surgery would be needed. Camouflage has its limitations in terms of the soft tissue changes that can be achieved. The orthodontic camouflage is a form of dental displacement along with its supporting tissues to compensate for a maxillomandibular discrepancy. The treatment of such malocclusions have to be planned adequately based on the treatment objectives, stability of the changes achieved, and acceptability of treatment by the patient. The cases discussed in this case report achieved good functional stability.

REFERENCES

1. Fu M, Zhang D, Wang B, Deng Y, Wang F, Ye X. The prevalence of malocclusion in China—an investigation of 25,392 children. *Chinese Journal of Stomatology*. 2002;37(5):371–373.
2. Irie M, Nakamura S. Orthopedic approach to severe skeletal Class III malocclusion. *American Journal of Orthodontics*. 1975;67(4):377–392.
3. Bukhary MT. Comparative cephalometric study of Class III malocclusion in Saudi and Japanese adult females. *Journal of Oral Science*. 2005;47(2):83–90.
4. Celikoglu M, Akpınar S, Yavuz I. The pattern of malocclusion in a sample of orthodontic patients from Turkey. *Medicina Oral, Patologia Oral y Cirugia Bucal*. 2010;15(5):791–796.
5. Staudt CB, Kiliaridis S. Different skeletal types underlying Class III malocclusion in a random population. *American Journal of Orthodontics and Dentofacial Orthopedics*. 2009;136(5):715–721.
6. Cevidanes L, Baccetti T, Franchi L, McNamara Jr. JA, De Clerck H. Comparison of two protocols for maxillary protraction: bone anchors versus face mask with rapid maxillary expansion. *The Angle Orthodontist*. 2010;80(5):799–806.
7. Celikoglu M, Oktay H. Effects of maxillary protraction for early correction of class III malocclusion. *European Journal of Orthodontics*. 2014;36(1):86–92.
8. Khan MB, Karra A. Early treatment of class III malocclusion: a boon or a burden? *International Journal of Clinical Pediatric Dentistry*. 2014;7:130–136.
9. Moyers RE. *Handbook of Orthodontics*. Year Book Medical Publishers. 1988.
10. Proffit WR, Fields Jr. HW, Sarver DM. *Contemporary Orthodontics*. Elsevier Health Sciences, Philadelphia, Pa, USA. 2014.
11. Mouakeh M. Cephalometric evaluation of craniofacial pattern of Syrian children with Class III malocclusion. *American Journal of Orthodontics and Dentofacial Orthopedics*. 2001;119(6):640–649.
12. Sugawara J, Asano T, Endo N, Mitani H. Long-term effects of chin cap therapy on skeletal profile in mandibular prognathism. *American Journal of Orthodontics and Dentofacial Orthopedics*. 1990;98(2):127–133.
13. Baccetti T, Rey D, Angel D, Oberti G, McNamara Jr. JA. Mandibular cervical headgear vs rapid maxillary expander and facemask for orthopedic treatment of class III malocclusion. *The Angle Orthodontist*. 2007;77(4):619–624.