

To cite: Akanksha Shukla, Gurkeerat Singh, Raj Kumar Singh, Varun Goyal, Nishant Gupta, Gaurav Saluja, Ritu Gupta

Comparative evaluation of facial soft tissue changes using 3D scanning and 2D photography in bimaxillary protrusion extraction treatment cases.

J Contemp Orthod 2020;4(4): 21-28.

Received on:
11-11-2020

Accepted on:
20-12-2020

Source of Support: Nil

Conflict of Interest: None

Comparative Evaluation of Facial Soft Tissue Changes Using 3D Scanning and 2D Photography in Bimaxillary Protrusion Extraction Treatment Cases.

¹Akanksha Shukla, ²Gurkeerat Singh, ^{*3}Raj Kumar Singh, ⁴Varun Goyal, ⁵Nishant Gupta, ⁶Gaurav Saluja, ⁷Ritu Gupta

^{1,6,7}Post-Graduate Resident, Department Of Orthodontics And Dentofacial Orthopaedics, Sudha Rustagi College Of Dental Sciences And Research, Faridabad, Haryana, India.

²Vice Principal, Professor and Head, Department Of Orthodontics And Dentofacial Orthopaedics, Sudha Rustagi College Of Dental Sciences And Research, Faridabad, Haryana, India.

^{3,4,5}Associate Professor, Department Of Orthodontics And Dentofacial Orthopaedics, Sudha Rustagi College Of Dental Sciences And Research, Faridabad, Haryana, India.

ABSTRACT

Introduction – This prospective clinical study was undertaken to analyze the three-dimensional facial soft tissue changes in bimaxillary protrusion extraction treatment cases using 3D structured light based scanner and facial photographs and to compare the two modalities.

Materials and Methods – 25 Indian adult patients of 18 - 23 years of age with dentoalveolar bimaxillary protrusion malocclusion and all four premolar extraction with maximum anchorage as treatment plan were taken. A pre-operative and post-operative extra oral 3D scan and 2D photographs were obtained for each subject. A prospective comparative evaluation of 12 lateral and 10 frontal soft tissue parameters was done.

Results – Significant changes were seen in distance of Sn, Pog, Ls, and Li from TVL, Ls and Li from E line and S line, Inf sulcus to H line, Naso-labial angle, H angle, and Merrifield Z angle ($p < 0.05$). However no statistical difference was found between the results obtained from 3D scan and facial photographs.

Conclusion – Significant soft tissue profile changes are obtained from pre-treatment to post-treatment in all first four premolar extraction bimaxillary protrusion cases mainly in antero-posterior direction. The changes observed through evaluation of scans were similar to the ones obtained through photographs.

Key Words: Soft tissue profile changes, Extraction treatment, structured light based Scanner, Photographs, 3D versus 2D.

INTRODUCTION

In today's world, most individuals seeking orthodontic treatment are looking for a pleasant facial profile. Improved soft tissue esthetics have become the primary objective of orthodontic treatment.¹

Bimaxillary protrusion characterized by proclined maxillary and mandibular incisors is the commonest chief complaint of patients seeking orthodontic treatment.² Such patients are routinely treated with all four first premolar extraction with maximum anchorage consideration.²⁻⁴ The soft tissue response to such treatment is currently debatable. Some studies have reported a high degree of correlation between retraction of upper incisors and lip retraction,⁵⁻⁷ while others reported that a definite proportional change in the soft tissue does not necessarily follow changes in the dentition.^{8,9}

Cephalometric radiographs and photographs have by far been the most popular means of evaluating soft tissue changes in extraction cases. Lateral cephalograms have an inherited problem of vertical and horizontal displacement of images

owing to radiographic midsagittal projection errors.¹⁰ Photographs provide limited information regarding the soft tissue changes and is influenced by factors such as angulation and direction of taking the photograph.¹¹

3-Dimensional (3D) imaging techniques have been recently developed for the evaluation of facial soft tissue changes such as Cone Beam Computed Tomography (CBCT), Laser based scanning systems and Structured light based Scanners.¹² 3D facial diagnosis gives a better visualization of facial soft tissue profile of the patient and also helps motivate the patients to appreciate the changes brought by long duration orthodontic treatments.

One critical problem with most of the 3D scanning systems is its cost and exposure to radiations. A structured light based scanner is a fast processing alternative that captures photorealistic images in a non invasive manner. It makes use of ambient white light making it safe to use for young children and pregnant women where lasers and radiation exposure pose a great

biological risk.¹³

The light projector unit projects an organized pattern of grids, dots, or stripes of white light onto the surface of the object. The projected light is then captured by a camera. It uses a sensor to identify how the patterns appear after being distorted by the object under different illumination condition to eventually recover the 3D geometry.¹⁴

The structured light based scanner used in this study was a USB powered portable hand held scanner compatible with Windows® 8 and 10. It uses a short range scanning technology from Intel® with a full HD colour camera.¹⁵

AIM

Comparative evaluation of facial soft tissue changes using 3D scanning versus 2D photography in bimaxillary protrusion extraction treatment cases.

OBJECTIVES

1. To evaluate the soft tissue changes pre- and post- treatment with the help of 3D extra oral scanner and 2D photographs in bimaxillary protrusion extraction treatment cases.
2. To do a comparative evaluation of the soft tissue changes recorded using scanner and photographs..

MATERIALS AND METHOD

- Structured light-based scanner – Sense™ 3D
- DSLR camera- Nikon™ D5600
- Tripod Setup
- 3D analysis software- MeshLab,3D Builder™,
- Photograph Analysis Software- Tracker™. Adobe® Photoshop 7.0

Sample size estimation: The sample size estimation was done by using **GPower software (version 3.0)**. The power of the study was taken to be 80% and Confidence Interval (C.I.) of 95% ($p < 0.05$). The sample size was estimated to be a minimum of 8 as assessed from a similar study

Sample distribution: 25 bimaxillary protrusion orthodontic patients within the age group of 18 to 23years indicated for fixed orthodontic treatment with all four first premolar extraction.

INCLUSION CRITERIA

1. Patient's in the age group of 18-23 years.
2. Patient's with Class I bimaxillary protrusion to be treated with all 4 pre-molar extraction.
3. Permanent dentition with second molars erupted.
4. No history of previous orthodontic intervention.

5. Patients capable of maintaining good oral hygiene.

EXCLUSION CRITERIA

6. Patient who require habit or functional treatment.
7. Patients with a history of any congenital anomalies such as supernumerary teeth.
8. Patients who are irregular or cannot maintain proper oral hygiene.
9. Patients who do not give consent to be part of the study.

METHODOLOGY

Treatment records including 2D photographs and 3D scans were made pre- and post- extraction orthodontic treatment. Patients were informed about the study and their consent for participation was taken. Clearance from the concerned ethical committee was obtained before proceeding with the study

For the photographs:

Two different 2D pictures were made under standardized conditions in a portrait mode: one frontal and one lateral (right profile) taken by DSLR camera. Photographs were taken by making subjects sitting upright; head in the natural posture with the Frankfort Horizontal plane (FH plane) parallel to the floor, eye level behind the camera as shown in Figure 1.

The photographs were standardized by using a tripod set up and a chair placed at 1.5 meters distance from camera lens which was marked using a green tape as shown in Figure 2. The focal length was set to 70 mm to standardize the magnification also.




Figure1: standardized photographs taken at eye level. **Figure2:** Tripod setup at 1.5 metres.

Magnification error was further removed by measuring the inter-pupillary distance of the patient and calibrating it in the software Tracker™ using a calibrating Stick. Every reading was recorded three times by three different operators and the average reading was recorded in the proforma of the patient for the purpose of the study. Other parameters were then measured to scale in accordance to this reference measurement.

For the scans:

Scans were done by using structured light based soft tissue scanner by Sense™(figure 3)

Individual subjects in rest position were scanned from Ear to Ear laterally and anteriorly from hairline to the most prominent soft tissue point on the chin i.e. pogonion.

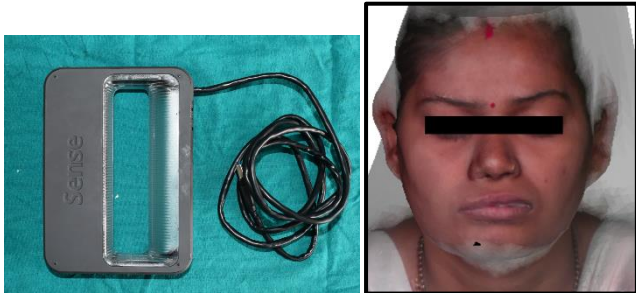

Figure 3 Structured light based scanner. **Figure 4** 3D scan

The scanner was moved 180° around the patient’s face to record facial scan. The scans were made by asking patient to look straight ahead, keeping their heads parallel to the FH plane. (figure 4)

Scans were internally calibrated by the sense software with the mean error less than 1%.

The acquired 2D (TIFF file) and 3D images (.obj file) were afterwards transferred to a computer for further analysis of soft tissue landmarks.

QUANTITATIVE ASSESSMENT OF FACIAL MORPHOLOGY

A total of 14 facial landmarks - were identified twice on each of the 2D and 3D images. To place the landmarks on the 2D images, software Tracker™ was used. 3D Builder™ was used for landmark identification on the 3D images.

Following landmarks were used for frontal/ lateral analysis. (Figure 5 and 6)

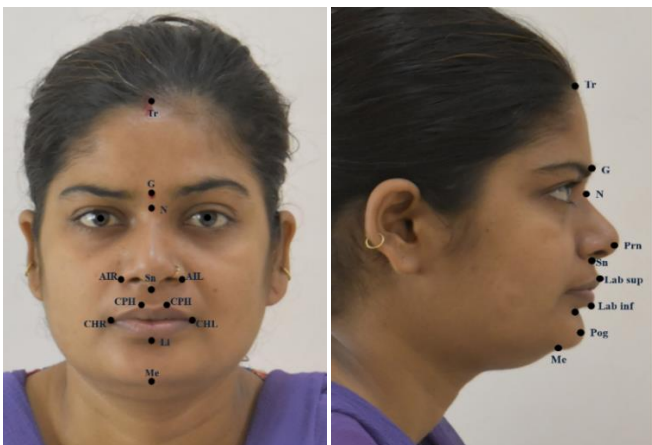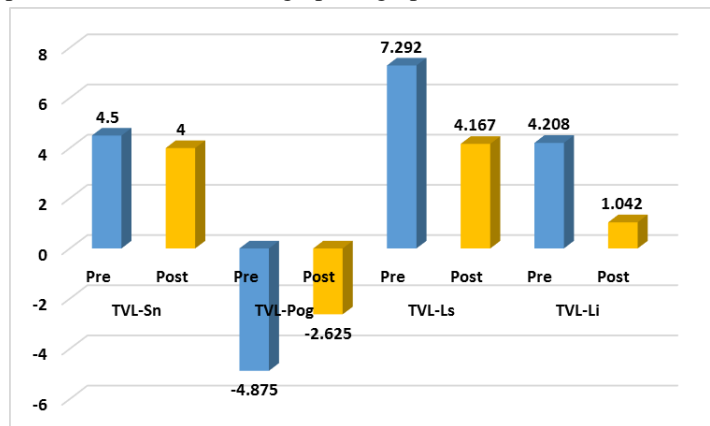


Figure5 Frontal analysis landmarks. **Figure6** Lateral analysis landmarks.

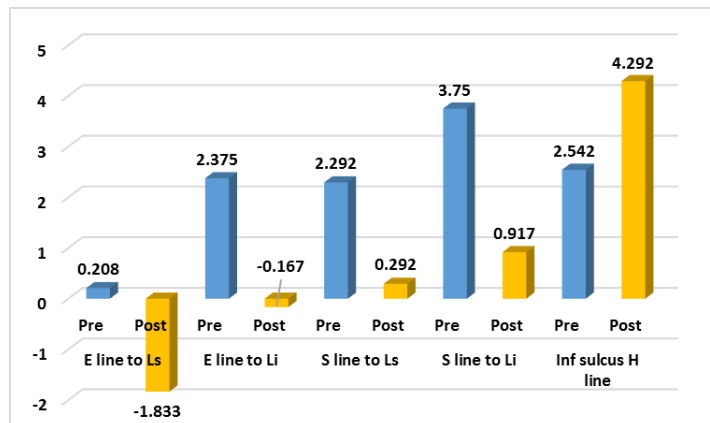
RESULTS

Data was analyzed using Statistical Package for Social Sciences (SPSS) version 21.0, IBM Inc. Descriptive data was reported for each variable. Descriptive statistics such as mean and standard deviation for continuous variables was calculated. Shapiro Wilk test was used to check the normality of the data. As the data was found to be normally distributed bivariate analyses was performed using Independent t test and paired t test. Level of statistical significance was set at p-value less than 0.05.

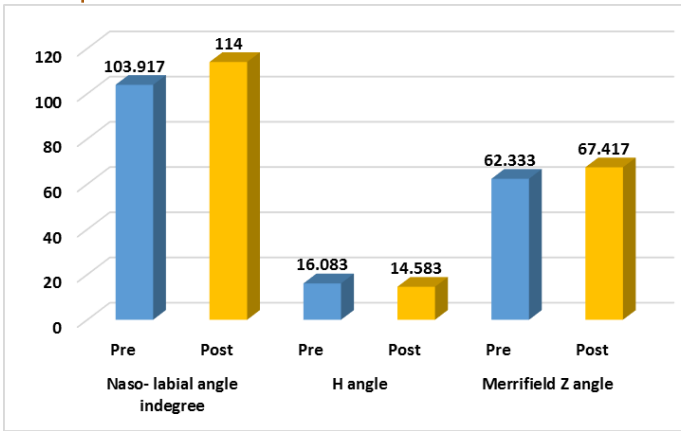
Graph 1, 2 & 3 shows Pre to post treatment changes in lateral parameters assessed through photographs.



Graph 1 There was a significant difference seen in parameters TVL-Sn, TVL- Pog, TVL-Ls, TVL-Li.

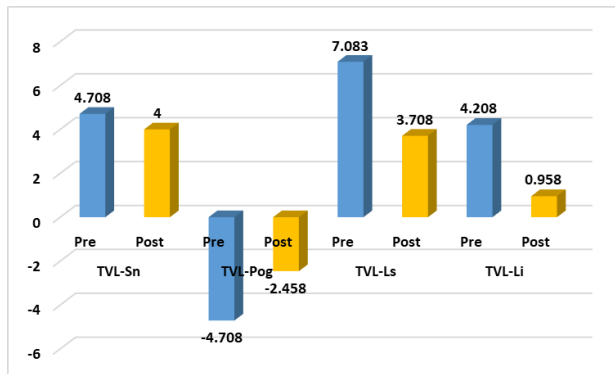


Graph 2 There was a significant difference seen in parameters E line to Ls, E line to Li, S line to Ls, S line to Li, Inf sulcus- H line.

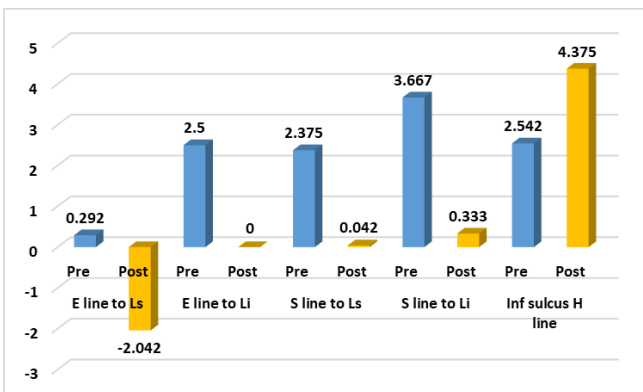


Graph 3 There was a significant difference seen in parameters Naso-labial angle, H angle, Merrifield Z angle.

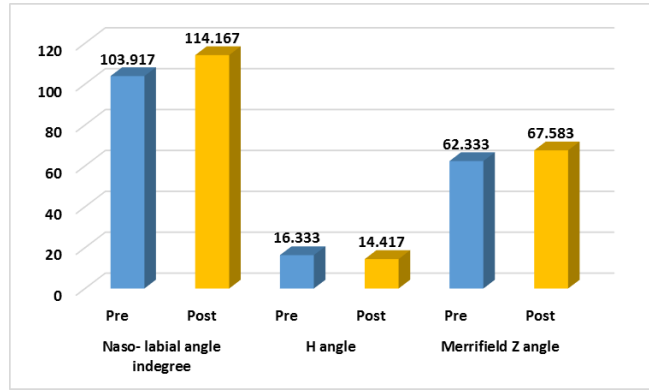
Graph 4, 5 & 6 shows Pre to post treatment changes in lateral parameters assessed through scans.



Graph 4 There was a significant difference seen in parameters TVL-Sn, TVL-Pog, TVL-Ls, TVL-Li.

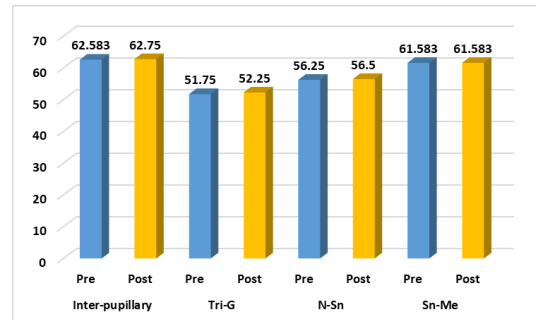


Graph 5 There was a significant difference seen in parameters E line to Ls, E line to Li, S line to Ls, S line to Li, Inf sulcus- H line.

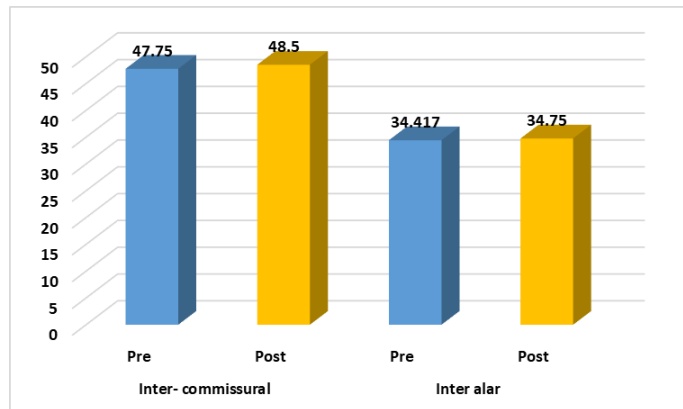


Graph 6 There was a significant difference seen in parameters Naso-labial angle, H angle, Merrifield Z angle.

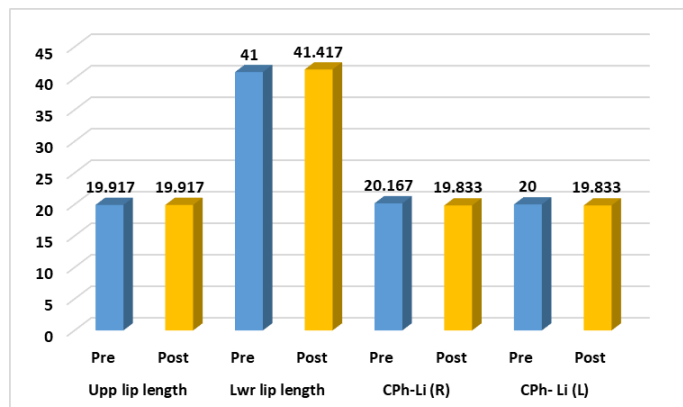
Graph 7, 8 & 9 shows Pre to post treatment changes in Frontal parameters assessed through photographs



Graph 7 There was no significant difference seen in the frontal parameters Inter-pupillary, Tri-G, N-Sn, Sn-Me.

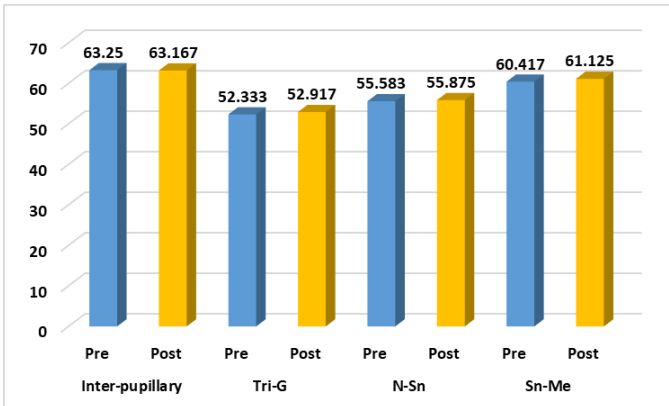


Graph 8 There was no significant difference seen in the frontal parameters Inter-commissural, Inter alar,

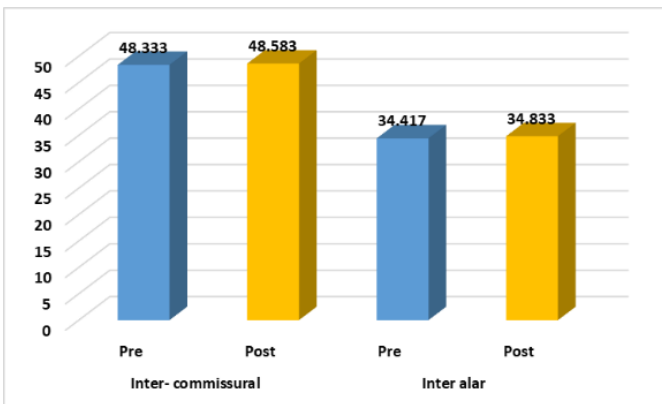


Graph 9 There was no significant difference seen in the frontal parameters Upp lip length, Lwr lip length, CPh-Li (R) and CPh- Li (L)

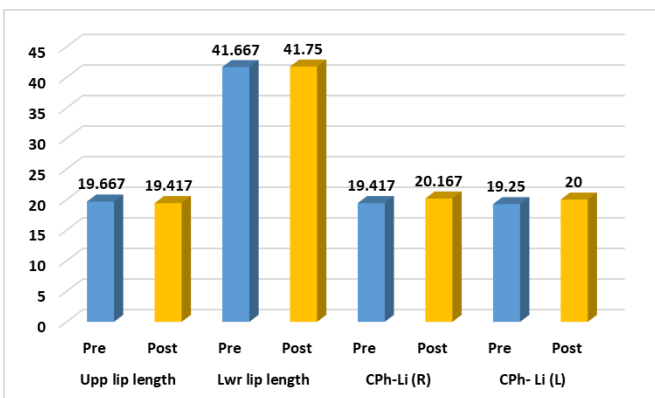
Graph 10, 11 & 12 shows Pre to post treatment changes in Frontal parameters assessed through Scans.



Graph 10 There was no significant difference seen in the frontal parameters Inter-pupillary, Tri-G, N-Sn, Sn-Me.



Graph 11 There was no significant difference seen in the frontal parameters Inter-commissural, Inter alar.



Graph 12 There was no significant difference seen in the frontal parameters Upp lip length, Lwr lip length, CPh-Li (R) and CPh- Li (L)

There was no significant difference seen in lateral and frontal parameters when 3D scans were compared with 2D photographs using t test as $p > 0.05$.

DISCUSSION

Pretreatment records are the basis of good orthodontic diagnosis. Clinical photographs have long been considered the gold standard for orthodontic diagnosis.¹⁶ They are used not only to record the pre-treatment and post-treatment extra oral and intra oral clinical conditions, but also to keep a track of and record the treatment progress.

The major drawback however of these photographs is that they record the facial profile in a 2D manner. With advances in 3D imaging technology, the orthodontists now have access to overcome this disadvantage. As the soft tissue esthetics take a center stage in seeking orthodontic treatment, the diagnostic tools need to be more accurate and predictable.¹⁷ We used a structured light based scanner The Sense[®] by 3D systems[™] for scanning in our study. Lili Ma and Tianmin Xu in 2009¹³ validated a three-dimensional facial scanning system based on structured light techniques and concluded that treatment evaluation, growth and surgery planning can very well be approached with these systems without any radiation hazards.

Adult patients with Class I bimaxillary malocclusion need extractions of all first premolars and maximum retraction to achieve an esthetic profile. The preoperative and postoperative photographs and 3D scans of individual subjects taken prior to bonding and at the end of the treatment respectively in a standardized manner were evaluated for ten frontal and twelve lateral parameters before and after the treatment. The changes observed by both modalities were then compared with each other.

Soft tissue adaptation after orthodontic therapy shows a wide range of variability and adaptability with respect to every individual. Leonardi et al in 2010¹⁸ in their systematic review on soft tissue changes following the extraction of premolars in non-growing patients with bimaxillary protrusion demonstrated that upper and lower lips retract by 2-3.2 mm and 2-4.5 mm respectively alongwith increase in nasolabial angle after treatment with all first four pre molar extractions in biprotrusive patients. Similar observations were made in our study also. The statistically significant reduction in the value of Ls and Li from TVL, E line and S line indicates that there has been an overall

retraction in the position of upper and lower lip.

However, a statistical increase unlike our study was found by Janson et al. in 2015¹⁹ in distance of Ls and Li to S line, reporting it to be 0.2 ± 2.79 mm and 1.2 ± 2.8 mm respectively. The difference could be due to the variance in subjects as Class II patients were also considered in this study. Solem et al.²⁰ reported that the soft tissue lip changes extend upto the columella area. Since soft tissues are known to follow the underlying hard tissue structures, it can be inferred that soft tissue changes observed in our study at Sn and inferior sulcus depth might be the result of the same.

The increase in nasolabial angle and Merrifield Z angle with a decrease in H angle can be attributed to the retraction of the upper and lower lips concurrent with backward movement of Sn and forward movement of the Pog.

From the above mentioned findings we can see that the changes observed in the photographic evaluation and evaluation through scans were very similar and statistically non-significant. This means that the analysis through scans is as reliable as that of the photographs.

As for the frontal parameters, none of the readings were statistically significant indicating that in adult patients with bimaxillary protrusion treated with all first four premolar extraction with maximum retraction, the changes seen in profile are more in antero-posterior dimension. There is no change in vertical or transverse dimension of the facial soft tissue.

When the frontal parameters such as inter-pupillary distance, inter-alar width and inter-commisural length was clinically evaluated with the subject it was found that the measurements from the scans were closer to the ones obtained on subjects. The accuracy level which is claimed by the sense company i.e. 0.060 mm²¹ is, therefore, clinically reliable.

3D imaging was born in 1970s and has ever since evolved for craniofacial growth analysis and facial morphology recording. In 2013, Kazu Hayashi and others²² concluded that clinically reliable and accurate results are obtained with 3D systems. The non-invasive 3D technology not only assists in pre-treatment and post-treatment assessment of dento skeletal relationship and facial esthetics, but also enable us to plan our treatment precisely, predict the changes more accurately, and

ultimately lead to more satisfied patients. The use of 3D scans when superimposed with other modalities like CBCT, can be a boon to oral and maxillofacial surgeons and prosthetic surgeons in predicting the exact facial response after their surgeries.²³ A range of customized extra oral appliances could therefore be constructed to maximize their benefits with better adaptation to facial anatomy and contours which cannot be done with photographic records.

As the technological advancements are taking place, it has become imperative that the diagnostic tools are upgraded so that better treatment results can be achieved. On one hand we have the long trusted photographic records which do not give us a complete picture of soft tissue esthetics in all the three planes of dimension. There are certain problems of standardization associated with them that makes their use for post treatment and pre-treatment comparisons questionable and for appliance customizations not suitable. Whereas on the other hand we have 3D Scanning systems available which are technologically advanced and far superior to conventional photographs. They help in studying the face from all aspects, with accurate replication and precision landmark identification. They also open doors for advent of newer treatment procedures and devices which are more effective, efficient, predictable and accurate and less uncertain.

The findings in the study have clearly indicated the reliability and efficacy of 3D scans in clinical orthodontics. The aforementioned advantages of 3D over conventional photographs further emphasize the need to adopt this trending technology and use it to expand the quality of orthodontic diagnosis and treatment.

CONCLUSION

From the present study it can be seen that:

- Soft tissue profile changes from pre-treatment to post-treatment in all first four premolar extraction bimaxillary protrusion cases are majorly seen in antero-posterior direction.
- There is significant reduction in upper and lower lip protrusion and increase in nasolabial angle and flattening of the facial profile. Since all the subjects in this study were adults, such soft tissue changes can be attributed more to

the orthodontic treatment than the changes associated with ageing and growth.

- It was also found that the changes observed through evaluation of scans were similar to the ones obtained through photographs. But scans offer the advantage of being 3-dimensional, making the visualization in all three planes possible. This further helps in more effective and comprehensive treatment planning so that best facial esthetics can be achieved.

REFERENCES

1. Ahn H W, Chang Y J, Kim K A, Joo S H, Park Y G, Park K H. Measurement of three-dimensional perioral soft tissue changes in dentoalveolar protrusion patients after orthodontic treatment using a structured light scanner. *Angle Orthod* 2014; 84(5):795–802.
2. Lew K. Profile changes following orthodontic treatment of bimaxillary protrusion in adults with the Begg appliance. *Eur J Orthod*. 1989;11:375–381.
3. Tan TJ. Profile changes following orthodontic correction of bimaxillary protrusion with a preadjusted edgewise appliance. *Int J Adult Orthod Orthognath Surg*. 1996;11:239–251.
4. Kusnoto J, Kusnoto H. The effect of anterior tooth retraction on lip position of orthodontically treated adult Indonesians. *Am J Orthod Dentofacial Orthop*. 2001;120:304–307.
5. Caplan MJ, Shivapuja PK. The effect of premolar extractions on the soft-tissue profile in adult African American females. *Angle Orthod* 1997;67:129-36.
6. Bravo LA. Soft tissue facial profile changes after orthodontic treatment with four premolars extracted. *Angle Orthod* 1994;64:31-42.
7. Diels RM, Kalra V, DeLoach N Jr., Powers M, Nelson SS. Changes in soft tissue profile of African-Americans following extraction treatment. *Angle Orthod* 1995;65:285-92.
8. Neger M. A quantitative method for the evaluation of the soft tissue facial profile. *Am J Orthod* 1959;45:738-51.
9. Hershey HG. Incisor tooth retraction and subsequent profile change in post adolescent female patients. *Am J Orthod* 1972;61:45-54.
10. Nassef, Essam & Attia, Khaled & Al-Hadithiy, Saba & Mostafa, Yehya. (2009). Soft tissue cephalometrics: an overdue evaluation. *World journal of orthodontics* 2009;10: 301-4.
11. Lane C, Harrell W Jr. Completing the 3-dimensional picture. *Am J Orthod Dentofacial Orthop*. 2008;133:612–620
12. Kau CH, Richmond S, Incrapera A, English J, Xia JJ. Three dimensional surface acquisition systems for the study of facial morphology and their application to maxillofacial surgery. *Int J Med Robot*. 2007;3:97–110.
13. Ma L, Xu T, Lin J. Validation of a three-dimensional facial scanning system based on structured light techniques. *Comput Methods Programs Biomed*. 2009;94:290–298.
14. Webster, J.G., Bell, T., Li, B. and Zhang, S. (2016). Structured Light Techniques and Applications. In *Wiley Encyclopedia of Electrical and Electronics Engineering*, J.G. Webster (Ed.)
15. 3D systems. 3D systems software support user guide. Available from <https://softwaresupport.3dsystems.com/sense2-scanner/> [Accessed 10 march 2020]
16. Gosman S D, Vineland N J. Anthropometric method of facial analysis in orthodontics *Am J Orthod* 1950; 36(10):749-762
17. Bloom, L. A. Perioral profile changes in orthodontic treatment. *Am J Orthod* 1961;47(5): 371–379
18. Kocadereli İ. Changes in soft tissue profile after orthodontic treatment with and without extractions. *American Journal of Orthodontics and Dentofacial Orthopedics*. 2002;122(1):67-72
19. Stephens C, Boley J, Behrents R, Alexander R, Buschang P. Long-term profile changes in extraction and nonextraction patients. *American Journal of Orthodontics and Dentofacial Orthopedics*. 2005;128(4):450-457.

20. Georgopoulos, A., Ioannidis Ch., & Valanis, A. Assessing the performance of a structured light scanner. *International Archives of Photogrammetry, Remote Sensing and Spatial Information Sciences*. 2010; 38(5): 250-255
21. Almeida-Pedrin RR, Guimarães LBM, Almeida MR, Almeida RR, Ferreira FPC. Assessment of facial profile changes in patients treated with maxillary premolar extractions. *Dental Press J Orthod*. 2012 Sept-Oct;17(5):131-7.
22. Shirvani A, Sadeghian S, Abbasi S. Prediction of lip response to orthodontic treatment using a multivariable regression model. *Dent Res J* 2016;13:38-45
23. Cevidanes LH, Bailey LJ, Tucker Jr GR, Styner MA, Mol A, Phillips CL, Proffit WR, Turvey T. Superimposition of 3D cone-beam CT models of orthognathic surgery patients. *Dentomaxillofacial Radiology*. 2005 Nov;34(6):369-75.