

## Clinical Pearl

**To cite:** Peeyush Jain, Ashish Kushwah, Saurabh Singh

A Simplified Anchorage Assessment Jig

J Contemp Orthod 2020;4(4): 41-43.

**Received on:** 19-10-2020

**Accepted on:** 12-12-2020

**Source of Support:** Nil

**Conflict of Interest:** None

# A Simplified Anchorage Assessment Jig

<sup>1</sup>Peeyush Jain, <sup>2</sup>Ashish Kushwah, <sup>3</sup>Saurabh Singh

<sup>1</sup>Reader, <sup>2,3</sup>Senior lecturer

<sup>1</sup>Department of Orthodontics & Dentofacial Orthopaedics, Pacific Dental College & Research Centre, Udaipur, Rajasthan.

<sup>2</sup>Department of Orthodontics & Dentofacial Orthopaedics, Institute of dental education & advanced studies, Gwalior, Madhya Pradesh.

<sup>3</sup>Department of Orthodontics & Dentofacial Orthopaedics, Eklavya Dental College, Kothputli, Rajasthan.

## ABSTRACT

Anchorage in orthodontics is one of the most important consideration during extraction treatment planning. Unwanted movement of molars in extraction space is called anchorage loss. Anchorage loss can be assessed by Cephalometrics but superimposition is one of the main disadvantages of this method. Thus, in this article we used a modified "Nance palatal arch" which helps to assess anchorage loss during different stages of treatment.

**Keywords:** - Anchorage, Anchorage loss, Nance palatal arch, Superimposition.

## INTRODUCTION

Anchorage planning in orthodontics has his own importance. Anchorage is the most important factor for deciding treatment outcomes. Usually crowding and bimaxillary protrusion cases require anchorage auxiliaries to enhance the anchorage value. In spite of all these preparations sometime unwanted tooth movement of posteriors occur in the extraction space.<sup>1</sup> Anchorage loss is the reciprocal movement of posterior teeth occurring during retraction of anterior segment for correction of anteroposterior discrepancy. For assessment of anchorage loss a anatomical landmark is required which is stable in overall orthodontic treatment.<sup>2</sup> According to Bailey et al palatal rugae area was a stable landmark in extraction and non extraction cases to assess anchorage loss. Anchorage loss can be easily assessed on cephalograms or CBCT record but this method was quite expensive and required radiographic exposure.<sup>3,4</sup>

In this article we discussed a simplified anchorage assessment jig which is a modified "Nance palatal arch".<sup>5</sup> This helps the clinician to assess anchorage loss on plaster model at any stage of the treatment and on the basis of the jig measurement clinician can modify their treatment plan.

## ARMAMENTARIAM

1. 20 gauge stainless steel round wire.
2. Universal plier.
3. Hard wire cutter.

4. Separating media (Cold mould seal).
5. Cold cure acrylic resin.
6. Pre-treatment/ Pre- retraction plaster model.

## DESIGN AND FABRICATION

1. The design of the "Anchorage Assessment Jig" is a modification of "Nance palatal arch".
2. Take one 10 cm length 20 gauge stainless steel wire.
3. Adopt it in pre-treatment/ pre- retraction maxillary model at palatal rugae area in a fashion that both end of the wire should be towards maxillary first molar.
4. Make a 90° bend upward & outward at the junction of proximal contact area of second premolar and first molar.
5. After 5 mm of 90 bend make another bend towards central fossa of maxillary first molar and cut the excess wire.
6. Apply separating media (cold mould seal) on palatal rugae area and make a palatal button at the rugae area over the wire.
7. By placing this jig at any stage of retraction a clinician can assess anchorage loss. (Figure A, B, & C)

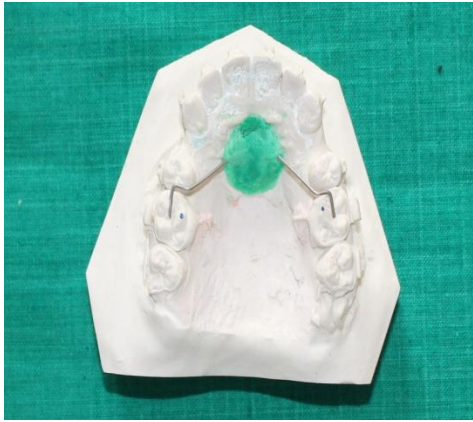


Figure A. Jig placement before retraction

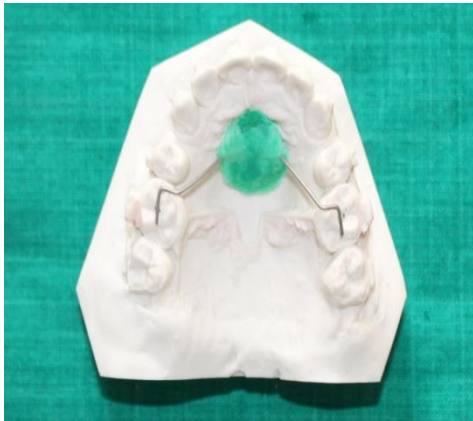

Figure B. Jig placement at mid of retraction

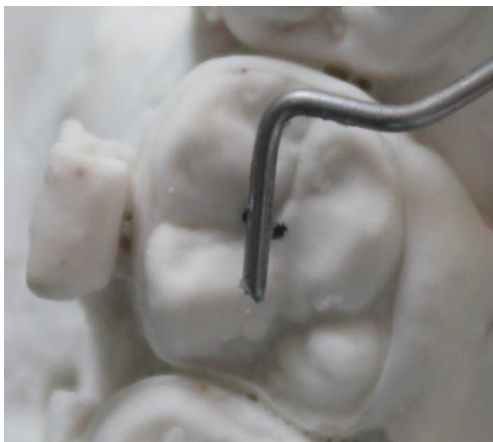

Figure C. Jig placement at occlusal surface of Molar at mid of retraction

## ADVANTAGE

1. Anchorage loss can be assessing at any stage of orthodontic treatment.
2. Easy to fabricate.
3. Cost effective.
4. No specific lab work require to fabrication of this jig.
5. Anchorage preparation can be changed at any stage of treatment.
6. No radiographic exposure.

## DISCUSSION

Anchorage consideration is nonnegotiable part of the orthodontic treatment. Anchorage loss is a multifactorial response aided by extent of extraction site, anchorage unit, age, bone density, thickness of cancellous bone, root position, appliance design and amount of crowding & overjet.<sup>6</sup>

For assessment of anchorage loss stable landmarks was required. According to Hoggan et al third palatal rugae area was the stable area in maxilla for anchorage assessment.<sup>4</sup> Almeida reported in his study that lingual foramen or mental foramen was a stable landmark.<sup>7</sup>

Three dimensional scanning and superimposition methods were advocated of assessing the anchorage loss because of its accuracy and reliability. Various studies<sup>8, 9</sup> found that these superimposition techniques are regarded as accurate and reliable in the comparison of plaster models. Radiographic exposure and cost makes dental study model as more acceptable for clinician to assess anchorage loss in clinical practice.

This simplified anchorage assessment jig having properties like easy fabrication steps, economic armamentarium, no radiographic exposure and a single jig for overall treatment of a patient makes it more useful in comparison to other methods.

## CONCLUSION

This “Anchorage Assessment Jig” helps the clinician to assess accurate anchorage loss at any stage of orthodontic treatment and clinician can change his anchorage auxiliaries or can easily enhance the anchorage preparation on the basis of “Anchorage Assessment Jig” value. This jig provides a real time value of anchorage loss. Easy in office fabrication and simple application of this jig makes it more effective. Clinician can also assess the amount of anchorage loss during levelling and alignment. This economic jig helps to clinician to change their anchorage plan according to their need.

## FINANCIAL SUPPORT AND SPONSORSHIP

Nil.

## CONFLICT OF INTEREST

There are no conflicts of interest.

## REFERENCES

1. Proffit WR, Field HW, Sarver DM. Contemporary Orthodontics 5th edition, C.V. Mosby Co; 2013.p. 180-181.
2. Geron S, Shpack N, Kandos S, Davidovitch M, Vardimon AD. Anchorage Loss—A Multifactorial Response. *Angle Orthod* 2003;73:730–737.

3. Bailey LT, Esmailnejad A, Almeida MA. Stability of the palatal rugae as landmarks for analysis of dental casts in extraction and nonextraction cases. *Angle Orthod* 1996;66:73-8.
4. Hoggan BR, Sadowsky C. The use of palatal rugae for the assessment of anteroposterior tooth movements. *Am J Orthod Dentofacial Orthop* 2001;119:482-8.
5. Nance HN. The limitation of orthodontic treatment. *Am J Orthod Oral Surg* 1947; 33: 253–301.
6. Hart A, Taft L, Greenberg SN. The effectiveness of differential moments in establishing and maintaining anchorage. *Am J Orthod Dentofacial Orthop*. 1992;102:434–442.
7. Almeida MA, Philips C, Kula K, Tulloch C. Stability of the palatal rugae as landmarks for analysis of dental casts. *Angle Orthod*.1995;65:43–48.
8. Sousa MV, Vasconcelos EC, Janson G, Garib D, Pinzan A. Accuracy and reproducibility of 3-dimensional digital model measurements. *Am J Orthod Dentofacial Orthop* 2012;142:269-73.
9. Fleming PS, Marinho V, Johal A. Orthodontic measurements on digital study models compared with plaster models: a systematic review. *Orthod Craniofac Res* 2011;14:1-16.