

To cite: Ajit V. Parihar, Kavin Prasanth A, Dolly Patel, Shivam Verma- Understanding The Importance of Soft Tissue with Cephalometry In Orthodontics - A Comparative Study In Gujarati Population 2019;3(1): 32-39.

Received on:
05-01-2019

Accepted on:
21-03-2019

Source of Support: Nil

Conflict of Interest: None

Understanding the Importance of Soft Tissue with Cephalometry in Orthodontics - A Comparative Study in Gujarati Population

¹Ajit V. Parihar, ²Kavin Prasanth A, ³Dolly Patel, ⁴Shivam Verma

¹⁻⁴Junior Resident II(MDS), Department of Orthodontics, Faculty of Dental Sciences.

¹⁻⁴ Institute of Medical Sciences, Banaras Hindu University.

ABSTRACT

Aims and Objectives: To establish the Soft Tissue and Dentoskeletal parameters for the young Indian adults of Gujarat State, according to Arnett and Bergman STCA and to compare the values of Arnett and Bergman STCA of Gujarati population with the original norms (i.e. for the Caucasian white population) of Arnett Bergman STCA and to identify differences if any.

METHODS

In this study, standard cephalometric radiographs of about 100 adults were taken with age ranging from 19 yrs 1 month to 24 yrs 9 months with Class 1 normal occlusion with all permanent teeth present and possessing good facial symmetry with cephalometric parameter readings within normal range and not having undergone any orthodontic or maxillofacial / plastic surgery in the past.

Tracings were made manually and the values were measured and analysed statistically. Results: The statistical data was analysed with statistical software S.P.S.S 6.1.4 for Windows. The findings obtained revealed a preponderance of weak chin in Gujarati population.

Overall facial length was lower with acute nasolabial angle and thinner lower lip with a decreased inter-labial gap as well as decreased maxillary incisor exposure when compared to the white population. Conclusion: The findings suggest a need for further studies to confirm normal soft tissue cephalometric values not only for the Gujarati population but also for the population of other states because of interstate ethnic group variations. These will directly influence orthodontic and orthognathic diagnosis as well as treatment planning. **Key words:** Gingival display, Maxillary Intrusion Splint, Bidental proclination, Headgear, Vertical Maxillary Excess.

Keywords: Soft tissue cephalometric norms, Arnetts STCA, Gujarati population.

INTRODUCTION

The ability of recognizing beautiful face is innate, but translating it to proper platform to define the ideal treatment goal is problematic. As the health professionals have increased their ability to change faces, the necessity to understand what is and what is not beautiful has to be intensified. As we know that, successful dental and occlusal corrections do not always result in an acceptable facial appearance. They often results in a facial decline.

The three most common ingredients in a negative facial outcome are 1) occlusion directed treatment planning, 2) no facial diagnosis, and 3) no facial treatment plan. Therefore, we need to replace our point of view from inside-out to outside-in to ensure a more predictable overall treatment result. (I) Proper diagnosis and treatment planning of facial changes based on model analysis are unreliable.

When our treatment objectives are based solely on models, the facial result will be negative. Models are essential but they do not focus on facial problems and therefore they are irrelevant to predict facial changes. (II)(III) Unfortunately, reliance on cephalometric studies also contribute to esthetic

problems.

When the cranial base is considered as the reference line for finding the profile, false findings can be generated because of high variability. (IV) Models, Cephalometrics and facial analysis together serve as the cornerstone for successful diagnosis. Facial analysis helps to identify positive and negative facial traits and therefore how the bite should be corrected to optimize facial needs.

(II)(III) The present study was performed with the aims and objectives of establishing the Soft Tissue and Dentoskeletal parameters for the young adults of Gujarati population, according to Arnett and Bergman STCA and identify differences if any, regarding the Facial Skeletal structures, in young adult men and women of Gujarati population and to compare the values of Arnett and Bergman STCA of Gujarati population with the original norms of Arnett and Bergman STCA. **MATERIALS AND METHOD:** The study was conducted on 100 Gujarati subjects (50 males, 50 females). Their ages ranged from 19 yrs 1 month to 24 yrs 9 months.

All the subjects were screened twice; the first screening was done as such: The criteria for selection for screening 1:- Class 1

normal occlusion All permanent teeth present and fully erupted upto second molar Good facial symmetry/harmony/proportion shown Should not have undergone any orthodontic or maxillofacial / plastic surgery in the past The criteria for selection for screening 2:- Those individuals whose following cephalometric parameter readings were not within normal range were discarded.

Horizontal parameters: SNA, SNB, ANB, SND, N Pog-FH, N Pog-AB. Vertical parameters: GoGn-Sn, Y axis. All lateral cephalograms were taken in centric occlusion with lips in repose and the Frankfort plane oriented horizontally to the natural head position.

The subjects were first assessed clinically, in the natural head position, seated condyles, and with lips in passive position. The orbital rim, subpupil, and alar base contours were used as key points to denote anteroposterior position of the maxilla. While taking cephalometric radiograph, small beads of 0.20 S.S Australian wire stabilized with transparent petroleum jelly were placed on the right side of the face to mark key midfacial structures.

The orbital rim marker was placed over the osseous orbital rim and directly under the pupil with the eye in straight-ahead gaze. Cheekbone marking required two perspectives: - a. The face was examined from the left side in 3/4 view and the right malar height of contour was marked with the ink, b. With the examiner standing directly in front of the patient, a bead was placed at the intersection of the right malar height of contour ink mark and a vertical line through outer canthus. The alar base marker was then placed in the deepest depression at the alar base of the nose.

The subpupil marker was placed directly below the straight ahead gaze of the pupil. Vertically, the subpupil marker was placed one half the vertical distance between the orbital rim and alar base marker (Fig I). These midface structures, although normally lost on traditional headfilms, were metallically marked on the headfilm and became the cornerstone for the cephalometric diagnosis and treatment planning.

The cephalometric radiographs were hand traced using a sharp 3H pencil on the acetate tracing paper. The True Vertical Line (TVL) was established. The line was placed through subnasale and was perpendicular to the natural horizontal head position. The important hard and soft tissue landmarks were then marked on the cephalogram.

The vertical and horizontal position of soft tissue and hard tissue landmarks were then measured relative to the subject's natural head position. If all the criteria for selection of subject were fulfilled, then the final analysis was carried out.

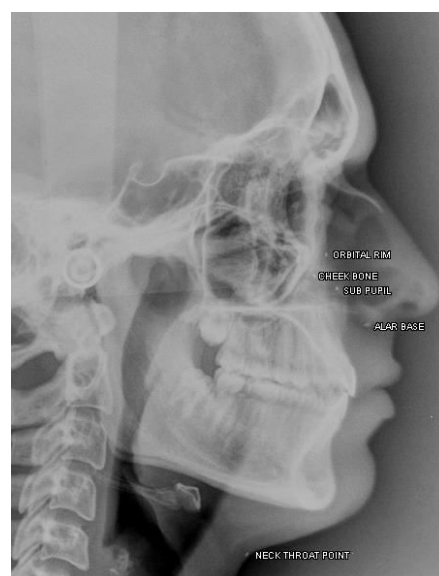

Fig I. Metal markings

RESULTS

The STCA (Soft tissue cephalometric analysis) is an integration of occlusal correction and soft tissue balance.

The STCA is used in assessment of soft tissue structures in relation with their hard tissue and their relationship with face. It is not used alone but can be used in combination with clinical examination and other cephalometric analyses that provide clinically relevant soft tissue information (harmony values). (V)

The STCA has five distinct but cross-contributory elements.

First, the analysis include key dentoskeletal structures which are relevant to the orthodontist (Mx1 to MxOP, Md1 to MdOP) and surgeon (MxOP to TVL). Orthodontic and surgical manipulation of the dentoskeletal factors is the essential key to facial profile and aesthetics (Fig II). Second, it measures key soft tissue structures that affect facial appearance (Fig III).

Third, it measures important vertical soft tissue lengths and soft tissue to hard tissue relationships (Fig IV). Fourth, it measures soft tissue points relative to the true vertical line, thus producing absolute projection values for each point (Fig V). Fifth, the absolute values are then related to one another to test facial harmony (Fig VI).

Harmony values are the key to the facial balance within the individual's face and are independent of the true vertical anteroposterior placement. (V) **STATISTICAL SOFTWARE:** The statistical analysis was carried out with the software S.P.S.S 6.1.4 for Windows (1 Apr 1996) and the data was analyzed accordingly.

Microsoft Word and Excel (Microsoft Office 2003) were used to generate the analytical data. The results of Arnett STCA are as follows: **DENTOSKELETAL FACTORS DISCUSSION:** To lay down the treatment goals with more emphasis on facial

esthetics, the orthodontist must assess the soft tissue point of view.

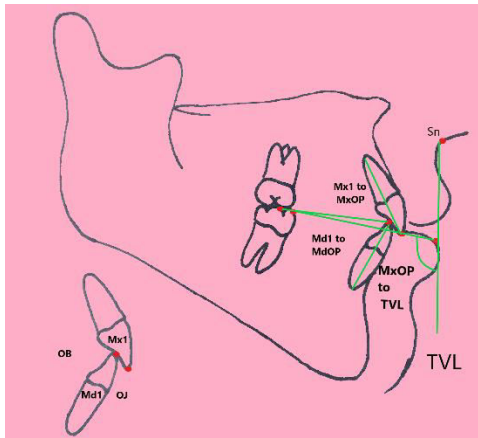


Fig II. Dentoskeletal factors^(V)

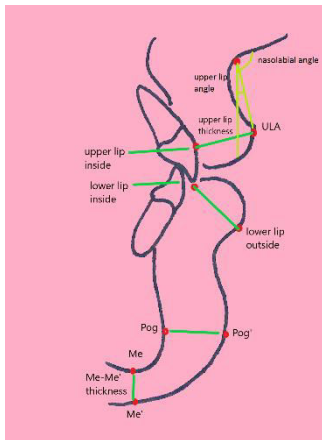


Fig III. Soft tissue Structures^(V)

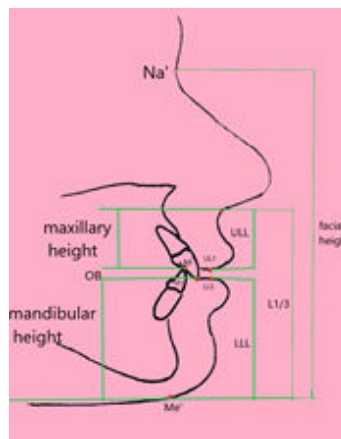
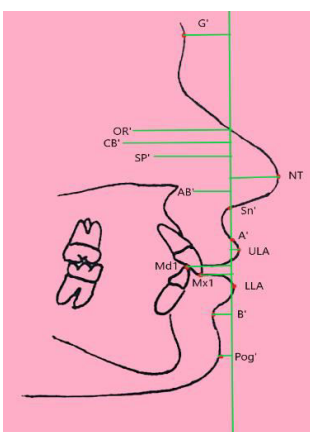


Fig IV. Projections to TVL^(V) Fig V. Facial length^(V)

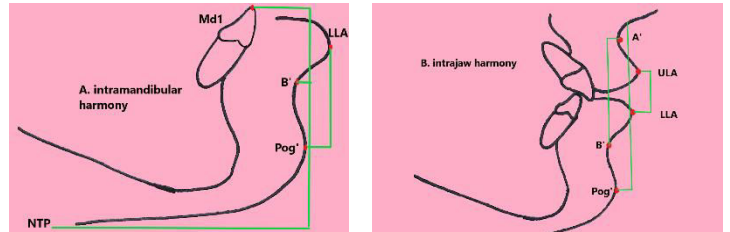


Fig VI. Harmony Values (A,B)^(V)

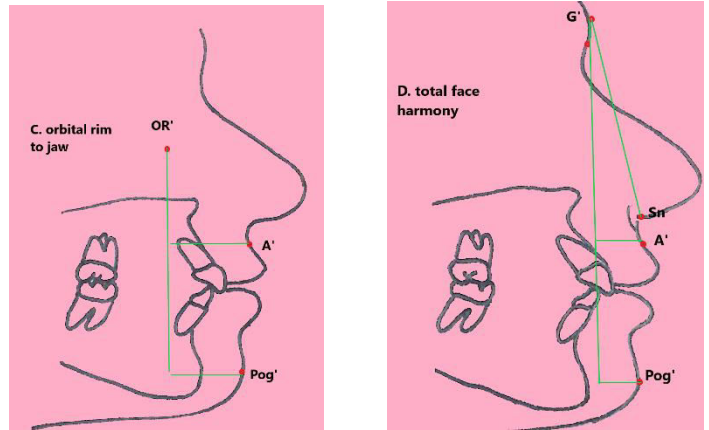


Fig VI. Harmony Values(C,D)^(V)

It is often assumed that if teeth are arranged in the normal position, the soft tissue will automatically be in a harmonious position. However, facial esthetics does not depend solely on hard tissue. Soft tissue dimensions are highly variable due to alternations in the thickness of the tissue, the lip length, and the postural tone.

It is important to study the soft tissue contour to adequately assess facial harmony. In the past, a few soft tissue cephalometric analyses were developed to measure facial positions.(VI,VII,VIII,IX) These analyses were not combined with clinical assessment, and none of them examined all of the important facial components.

Recently, facial balance, clinical diagnosis and treatment planning have been improved by means of a combination of clinical facial analysis and Soft Tissue Cephalometrics (STC). STC ensures objectivity by directly measuring the relative position of all facial parts involved in treatment. It also provides normal values, emphasizes soft tissue outcome, removes the subjective influence of preexisting quality, and lessens the emphasis of overjet as the sole indication of success. STC provide the diagnosis and also predicts the result of orthodontic as well as surgical treatment.

The nature of soft tissue profile is affected by many factors including ethnicity. The normal measurements of one ethnic group cannot be used as standard for other racial group due to

social and geographical variations. Thus different racial groups have to be treated according to

Indian young adults seeking orthodontic treatment or orthognathic surgery.

DENTOSKELETAL FACTORS	VALUES FOR INDIAN BOYS	VALUES FOR INDIAN GIRLS	ARNETT'S ORIGINAL VALUES GIRLS	ARNETT'S ORIGINAL VALUES BOYS
Maxi. Occlusal Plane	98.5 ± 5.33	99.7 ± 3.2	95.6±1.8	95.0±1.4
Maxi. Incisor to Maxi. Occlusal Plane	58.94 ± 5.56	59.6 ± 4.9	56.8±2.5	57.8±3.0
Mandi. Incisor to Mandi Occlusal Plane	63.12 ± 5.86	62.32± 6.4	64.3±3.2	64.0±4.0
Overjet	3.25 ± 0.94	3.2 ± 0.87	3.2±0.4	3.2±0.6
Overbite	3.46 ± 1.39	2.9 ± 1.22	3.2±0.7	3.2±0.7

Table 1. Dentoskeletal factors

their own individual characteristics.(X,XI,XII,XIII,XIV,XV,XVI,XVII,XVIII). All the researches had one common result that there are differences in dentofacial relationships between various

Young adults (ages ranged from 19 yrs 1 month to 24 yrs 9 months) of both sexes were included because most of the orthodontic treatment and orthognathic surgeries are performed in this age group. The data were separated according to sex to

SOFT TISSUE STRUCTURE	VALUES FOR INDIAN BOYS	VALUES FOR INDIAN GIRLS	ARNETT'S ORIGINAL VALUES GIRLS	ARNETT'S ORIGINAL VALUES BOYS
Upper Lip Thickness	15.33 ± 1.6	12.62 ± 1.56	12.6±1.8	14.8±1.4
Lower Lip Thickness	13.9 ± 1.67	12.44 ± 1.31	13.6±1.4	15.1±1.2
Pog – Pog'	13.1 ± 2.23	12.41 ± 1.82	11.8±1.5	13.5±2.3
Menton – Menton'	8.26 ± 1.86	7.08 ± 2.11	7.4±1.6	8.8±1.3
Nasolabial angle	95.9 ± 15.4	96.74 ± 8.36	103.5±6.8	106.4±7.7
Upper Lip angle	8.66 ± 6.15	8.08 ± 4.67	12.1±5.1	8.3±5.4

Table 2. Soft tissue structures

ethnic and racial groups. Therefore, it is important to develop standard values for various population and taken into consideration while formulating the orthodontic treatment plan for the particular ethnic group.

Most of the cephalometric standards are based on sample population of people from European-American ancestries. This study focused on samples of 100 Indian subjects with normal occlusion and well-balanced face. The inclusion criteria and methodology were oriented to identify normative values that can assist in diagnosis and treatment planning for

obtain more specific and useful cephalometric normative values.

For the convenience of comparison the results were divided into 3 groups Comparisons of males only (Whites and Gujarati) Comparisons of females only (Whites and Gujarati) Comparisons of males and females (Gujarati) All the parameters were then individually correlated within the group with its corresponding variable. Student t test was than used to analyze the difference in the means of all the parameters within the three groups.

FACIAL LENGTHS	VALUES FOR INDIAN BOYS	VALUES FOR INDIAN GIRLS	ARNETT'S ORIGINAL VALUES GIRLS	ARNETT'S ORIGINAL VALUES BOYS
Nasion' – Menton'	128 ± 6.79	119.02 ± 5.1	124.6±4.7	137.7±6.5
Upper Lip Length	22.8 ± 2.83	20.87 ± 2.23	21.0±1.9	24.4±2.5
Interlabial Gap	1.174±0.54	1.4 ± 0.61	3.3±1.3	2.4±1.1
Lower Lip Length	49.69 ± 3.6	45.2 ± 2.577	46.9±2.3	54.3±2.4
Lower 1/3rd of face	73.70 ± 5.8	67.47 ± 3.84	71.1±3.5	81.1±4.4
Overbite	3.46 ± 1.39	2.9 ± 1.22	3.2±0.7	3.2±0.7
Maxillary Incisor Exposure	2.15 ± 1.49	2.97 ± 1.25	4.7±1.6	3.9±1.2
Maxillary Height	24.95 ± 3.3	23.73 ± 2.37	25.7±2.7	28.4±3.2
Mandibular Height	51.28 ± 3.3	45.69 ± 2.47	48.6±2.4	56.0±3.0

Table 3. Facial lengths

COMPARISON OF INDIAN MALE AND WHITE MALE (Table 6):

Based on this study, there are significant differences between males of Indian & the white population. In the Dentoskeletal factors, significant differences is found in the inclination of Maxillary occlusal plane to TVL with increased value for Indian males ($P < 0.01$). Analysis of Dentoskeletal factors indicate that the maxillary occlusal plane is steeper in Gujarati males.

When comparing the soft tissue thickness, the significant difference is found in the lower lip thickness as it is thinner in Gujarati males ($p < 0.01$). The Nasolabial angle is comparatively lower in the Gujarati population ($p < 0.01$).

Analysis of soft tissue thickness reveals that the thicker upper lip compensates for the retrognathic maxillary base. Ethnic regional variation can be seen when compared with study done by Valianthan et al (XVIII)¹ in which lower lips were more prominent and thicker than upper lips. Acute nasolabial in Gujarati males indicate increased dental protrusion in Gujarati males. This is accordance with the study done by Valianthan et al.(XVIII). Significant difference is noted while analyzing the facial lengths i.e., total facial height, maxillary height, mandibular height, lower lip length, lower one third of face, interlabial gap and maxillary incisor exposure ($p < 0.01$). Upper lip length ($p < 0.05$) is greater in white population.

Analysis of soft tissue lengths indicate that there is a vertical difference in the two samples. There is overall decrease in the facial length of the Indian males when compared to the white

population. This is in harmony with the average physical characteristics of the particular population i.e. the average build and height of the white males is more in comparison to the Indian males. Regarding the projections from TVL. Glabella ($p < 0.05$) is closure to TVL than seen in white population. While cheek bone, alar base, A point, B point, Lower Lip anterior, Pogonion ($p < 0.05$) are more negative from TVL as compared to white population.

Analysis of TVL projection indicates midface deficiency in Gujarati males, with a prominent forehead and a convex profile. This is similar to results of Grewal et al.(XIX) Comparison of intramandibular harmony shows a significant difference in values of lower lip anterior to Pogonion and neck throat point to Pogonion, both of which signify a weak chin in Gujarati males.

When comparing the mandibular incisors to Pogonion, there is a mild protrusion of lower incisors in Gujarati males as compare to the white population. The thinner lower lips compensate for this mild protrusion. Comparison of interjaw harmony clearly depicts the weakness of mandibular structure when compared to the counterpart maxillary structure, i.e. values of Pogonion to Subnasale, Point A & Point B and Lower Lip Anterior & Upper Lip Anterior Comparison of orbital rim to jaw harmony reveals the chin weakness in the Gujarati male population i.e. a significant difference in Orbitale to Pogonion values. A mild difference is also noted in the position of Orbitale to Point A which confirms the midface deficiency in Gujarati males when compared to the White male population. Analyzing the Total facial harmony i.e.

The facial angle reveals a convex profile in Gujarati males when compared to the White males. Whereas Glabella to Point A signifies a prominent forehead in Gujarati males than white

males. These findings are similar with the results of Valianthan et al (XVIII) and Grewal et al.(XIX). Summarizing, the finding of the Gujarati male population in short we can conclude that the Gujarati males have a convex profile, mildly protrusive dentoalveolar structures (Lower incisor protrusion), midface deficiency, weak chin and a shorter facial height when compared to the white male population. PARAMETERS Table 7.

Comparison of Indian Females and White Females
COMPARISON OF INDIAN MALES AND INDIAN FEMALES (Table 3) The study shows that a significant difference is seen between the females and males of Indian population regarding few parameters. (SEXUAL DIMORPHISM) When comparing the Dentoskeletal values between Indian males and females not much of a difference is seen.

Except regarding the Overbite which was slightly more in Indian males ($p < 0.05$). Analyzing the Dentoskeletal factors reveals, a more protrusive dentoalveolar structures in females i.e. reduced overbite as compared to Gujarati males. Regarding the comparisons of soft tissue structures.

The upper and lower lip thickness and Menton-Menton' were significantly more in males. Similar results were also reported by Genecov et al, Skinazi et al(XX) , Ferrario et al(XII,XXI),

A thicker lower lip and comparative soft tissue chin thickness reveal deep mentolabial sulcus in males which is similar to the study by Hwang et al(XIV). It also shows that sexual dimorphism is seen lesser in white population. While no comparable difference was seen regarding Nasolabial and Upper lip angle. Significant difference was seen while comparing the facial lengths.

Total facial height, maxillary height, mandibular height, upper lip length, lower lip length and lower one third of face, were significantly smaller in females. But Maxillary incisor exposure and Inter labial gap were found to be more in females. Analyses of soft tissue lengths indicate that there is a vertical difference in the two samples.

There is overall decrease in the facial length of the Gujarati females when compared to the Gujarati males. This is in harmony with the average physical characteristics of the males and females i.e. the average build and height of the males is more in comparison to the females.

The increase in interlabial gap and enhanced maxillary incisor exposure is due to the comparatively shorter upper lip in Gujarati females as compared to the Gujarati males. Regarding the position of the structures when projected from TVL, maxillary structure like Orbital, Cheek Bone, subpupil & Alar Base where more negatively placed suggestive of mid face deficiency in males.

PROJECTIONS TO TVL	VALUES FOR INDIAN GIRLS	VALUES FOR INDIAN BOYS	ARNETT'S ORIGINAL VALUES GIRLS	ARNETT'S ORIGINAL VALUES BOYS
Glabella'	-6.38 ± 3.0	-5.57 ± 3.8	-8.5±2.4	-8.0±2.5
Orbital Rim	-22.83± 2.8	-18.29± 2.9	-18.7±2.0	-22.7±2.7
Cheek Bone	-31.8± 3.92	-25.9± 3.97	-20.6±2.4	-25.2±4.0
Subpupil	-18.2 ± 2.9	-13.2 ± 2.8	-14.8±2.1	-18.4±1.9
Alar Base	-10.8 ± 2.0	-8.78 ± 1.7	-12.9±1.1	-15.0±1.7
Nasal Projection	16.9 ± 2.04	15.5 ± 1.83	16.0±1.4	17.4±1.7
Subnasale'	0	0	0	0
A Point'	-2.04 ± 1.0	-1.78 ± 0.7	-0.4±1.0	-0.3±1.0
Upper Lip Anterior	2.16 ± 2.01	2.01 ± 1.51	3.7±1.2	3.3±1.7
Maxillary Incisor	-13.3 ± 5.2	-10.7 ± 2.6	-9.2±2.2	-12.1±1.8
Mandibular Incisor	-17.34± 3.1	-14 ± 2.55	-12.4±2.2	-15.4±1.9
Lower Lip Anterior	-1.49 ± 2.7	-0.65 ± 2.20	1.9±1.4	1.0±2.2
B Point'	-11.4 ± 2.9	-8.87 ± 2.4	-5.3±1.3	-7.1±1.6
Pog'	-8.19 ± 3.8	-6.76 ± 3.3	-2.6±1.9	-3.5±1.8

Table 4. Projections to TVL

and Hwang et al (XIV), regarding their respective population.

Maxillary incisor and Mandibular incisor values were larger in

males suggestive of a more upright position in the arch. This indicates that females have more prominent midface as compared to males but the dentoalveolar structure in females is slightly more protrusive i.e. only in the lowers ($P < 0.05$). This supports the study done by Nanda & Nanda(XV) that revealed a more protrusive skeletodental pattern in females.

The Chin (Pogonion) position is comparable in both sexes but the more negatively placed Point B is suggestive of deep mentolabial sulcus in males. Comparison of Intramandibular harmony values of males & females, Mandibular Incisor-Pogonion reading suggests that the Gujarati males have more upright lower incisors but chin prominence is comparable in both the sexes. Lower lip anterior to Pog value reveals thicker lower lip in Gujarati males than females.

Comparison of interjaw harmony i.e. values of Pogonion to

difference in the extremes of the face i.e., the forehead and the chin.

By comparing the findings between Gujarati males and females, we conclude that the values were quiet similar with few significant differences such that, there is a midface deficiency,

deeper mentolabial sulcus, increased facial lengths and decreased protrusion of the lower incisors in Gujarati males as compared with the Gujarati females. Regarding the smile it should said that the females have a shorter upper lip i.e.

Table 8. Comparison of Indian males and Indian females The difference between the values observed in the Gujarati population and the original values should be taken into consideration while making the diagnosis and treatment plan for these patients.

INTRAMANDIBULAR				
Mandibular Incisor – Pog'	9.55 ± 4.10	7.49 ± 3.31	9.8±2.6	11.5±2.8
Lower Lip Anterior – Pog'	7.15 ± 3.25	5.92 ± 2.82	4.5±2.1	4.4±2.5
B Point' – Pog'	3.79 ± 2.5	2.86 ± 1.61	2.7±1.1	3.5±1.3
Neck Throat Point – Pog'	55.5 ± 5.01	54.8± 4.50	58.2±5.0	61.4±7.4
INTERJAW RELATIONS				
Subnasale'- Pog'	8.24 ± 3.4	6.87 ± 3.25	3.2±1.0	4.0±1.7
A Point – B Point	9.23 ± 2.84	7 ± 2.39	5.2±1.6	6.8±1.5
U Lip Anterior – Lower Lip Anterior	3.74 ± 1.71	2.66 ± 1.45	1.8±1.0	2.3±1.2
ORBIT TO JAWS				
Orbital Rim – A Point'	20.57 ± 3.3	16.73 ±3.3	18.5±2.5	21.1±3.0
Orbital Rim – Pog'	15.39 ±4.4	12.42 ± 3.7	16.0±2.6	18.9±2.8
FULL FACIAL BALANCE				
Facial Balance	166.2 ± 3.9	167.7 ± 4.4	169.3±3.4	169.4±3.2
Glabella' – A Point'	4.88 ± 2.97	4.42 ± 3.19	8.4±2.7	7.8±2.8
Glabella' – Pog'	3.68 ± 3.15	3.68 ± 2.64	5.9±2.3	4.6±2.2

Table 5. Harmony Values

Subnasale, Point A & Point B and Lower Lip Anterior & Upper Lip Anterior. The comparison of Point A & Point B and lower lip anterior & upper lip anterior in Gujarati males and females, reveal that the prominence of maxillary skeletal structures in Gujarati females is more as compared to Gujarati males.

Comparison of orbital rim to jaw harmony i.e. Orbitale to point A and Orbitale to Pogonion values are clearly suggestive of mid face deficiency in Gujarati males. Analyzing the Total facial harmony i.e. the facial angle, Glabella to Pog, Glabella to Point A, reveals a comparable convex profile in both the sexes with no significant

CONCLUSION

The comparative evaluation of the data obtained during the study of Gujarati population (disregarding the gender bias) with that of the Arnetts original values. Dentoskeletal factors: - This reveals a weak chin in Gujarati population. Soft tissue structures: - acute nasolabial angle and thinner lower lip.

Facial lengths: - Overall facial length was comparatively smaller in Gujaratis and they also show a decreased interlabial gap as well as decreased maxillary incisor exposure. Projection to TVL: - Gujaratis have a prominent forehead, mid face deficiency and weak chin. Harmony values: - verifies the overall results obtained i.e. Weak chin, dentoskeletal protrusion

(lower) which is compensated by thin lower lips. Mid face deficiency, prominent forehead and a convex profile.

While the facts that surfaced out when comparison was done within the Gujarati population on the bases of gender was as follows:- Dentoskeletal factors:-More protrusive Dentoskeletal structures in females. Soft tissue structures:-the soft tissue thickness was greater in males. Facial length:- Facial length was significantly smaller in females.

Gujarati females also revealed an increased interlabial gap with more maxillary incisor exposure due to shorter upper lips. Projection to TVL:-Mid face deficiency is seen more in males relative to females. Males also reveal a deeper mentolabial sulcus. Harmony values:-Reveal relatively more upright incisors in males, which are well compensated by the thicker lower lips of males, Mid face deficiency in males relative to females.

At last, it should be said that a need for further study is overdue as it can give better results to confirm normal soft tissue measurements not only for the Gujarati population but also the population of other states because of its inter state variation. This will directly influence orthodontic diagnosis as well as treatment planning and help the orthodontist as well as the oral surgeons to achieve better and stable post-treatment results

REFERENCES

1. Arnett GW. Facial esthetics, orthodontics and orthognathic surgery, Summer2002 PCSO Bulletin. II.
2. Arnett GW, M Gunson, Facial planning for orthodontist and oral surgeons, Am J Orthod Dentofacial Orthop, 2004Sep;126(3)290-5. III. Arnett GW, Bergman RT. Facial keys to orthodontic diagnosis and treatment planning--Part II. Am J Orthod Dentofacial Orthop. 1993 May;103(5):395-411. IV. Arnett GW, Bergman RT. Facial keys to orthodontic diagnosis and treatment planning. Part I. Am J Orthod Dentofacial Orthop. 1993 Apr;103(4):299-312. V.
3. Arnett GW, Jelic JS, Kim J, Cummings DR, Beress A, Worley CM Jr, Chung B. Soft tissue cephalometric analysis: diagnosis and treatment planning of dentofacial deformity. Am J Orthod Dentofacial Orthop. 1999 Sep;116(3):239-53. VI. Holdaway RA. A soft-tissue cephalometric analysis and its use in orthodontic treatment planning. Part II. Am J Orthod. 1984 Apr;85(4):279-93. VII. Holdaway RA. A soft-tissue cephalometric analysis and its use in orthodontic treatment planning. Part I. Am J Orthod. 1983 Jul;84(1):1-28. VIII. Legan HL, Burstone CJ. Soft tissue cephalometric analysis for orthognathic surgery. J Oral Surg. 1980 Oct;38(10):744-51. IX. Spradley FL, Jacobs JD, Crowe DP. Assessment of the anteroposterior soft-tissue contour of the lower facial third in the ideal young adult. Am J Orthod. 1981 Mar;79(3):316-25. X. Bhat M, Sudha P, Tandon S. Cephalometric norms for Bunt and Brahmin children of Dakshina Kannada based on McNamara's analysis. J Indian Soc Pedod Prev Dent. 2001 Jun;19(2):41-51. XI. Cooke MS, Wei SH. A comparative study of southern Chinese and British Caucasian cephalometric standards. Angle Orthod. 1989 Summer;59(2):131-8. XII. Ferrario VF, Sforza C, Poggio CE, Serrao G, Miani A Jr. A three-dimensional study of sexual dimorphism in the human face. Int J Adult Orthodon Orthognath Surg. 1994;9(4):303-10. XIII. Hashim HA, AlBarakati SF. Cephalometric soft tissue profile analysis between two different ethnic groups: a comparative study. J Contemp Dent Pract. 2003 May 15;4(2):60-73. XIV. Hwang HS, Kim WS, McNamara JA Jr. Ethnic differences in the soft tissue profile of Korean and European-American adults with normal occlusions and well-balanced faces. Angle Orthod. 2002 Feb;72(1):72-80. XV. Nanda R, Nanda RS. Cephalometric study of the dentofacial complex of North Indians. Angle Orthod. 1969 Jan;39(1):22-8 XVI. Richardson ER.
7. Racial differences in dimensional traits of the human face. Angle Orthod. 1980 Oct;50(4):301-11. XVII. Sutter RE Jr, Turley PK. Soft tissue evaluation of contemporary Caucasian and African American female facial profiles. Angle Orthod. 1998 Dec;68(6):487-96. XVIII. Valiathan A, John KK. Soft tissue cephalometric analysis of adults from Kerala. J Indian Dent Assoc. 1984 Nov;56(11):419-22, 428. XIX. Grewal H, Sidhu SS, Kharbanda OP.
8. A cephalometric appraisal of dento-facial and soft tissue pattern in Indo-Aryans. J Pierre Fauchard Acad. 1994 Sep;8(3):87-96. XX. Genecov JS, Sinclair PM, Dechow PC. Development of the nose and soft tissue profile. Angle Orthod. 1990 Fall;60(3):191-8. XXI. Ferrario VF, Sforza C. Size and shape of soft-tissue facial profile: effects of age, gender, and skeletal class. Cleft Palate Craniofac J. 1997 Nov;34(6):498-504.