

## Comparative Evaluation of Rate of Enmasse Retraction Using Piezocision and Conventional Retraction Techniques- A Clinical Study

<sup>1</sup>Justin Jolly, <sup>2</sup>Balakrishna Shetty, <sup>3</sup>Goutham Reddy, <sup>4</sup>Sunil Muddaiah, <sup>5</sup>Sanju Somaiah, <sup>6</sup>Muhasin Essa

**To cite:** Justin Jolly, Balakrishna Shetty, Goutham Reddy, Sunil Muddaiah, Sanju Somaiah, Muhasin Essa. Comparative Evaluation of Rate of Enmasse Retraction Using Piezocision and Conventional Retraction Techniques- A Clinical Study. *Journal of Contemporary Orthodontics*, April-June 2019; 3 (2): 8-14.

**Received on:**

10-04-2019

**Accepted on:**

28-05-2019

**Source of Support:** Nil

**Conflict of Interest:** None

<sup>1</sup>MDS-Post Graduate Student, Department of Orthodontics, Coorg Institute of Dental Sciences, Coorg, Karnataka, India.

<sup>2</sup>Professor, Department of Orthodontics, Coorg Institute of Dental Sciences, Coorg, Karnataka, India.

<sup>3</sup>Professor and Head, Department of Orthodontics, Coorg Institute of Dental Sciences, Coorg, Karnataka, India.

<sup>4</sup>Professor, Department of Orthodontics, Coorg Institute of Dental Sciences, Coorg, Karnataka, India.

<sup>5</sup>Professor, Department of Orthodontics, Coorg Institute of Dental Sciences, Coorg, Karnataka, India.

<sup>6</sup>MDS-Post Graduate Student, Department of Orthodontics, Coorg Institute of Dental Sciences, Coorg, Karnataka.

### ABSTRACT

**Background and objective:** With the emerging concept of accelerated orthodontics, the duration of treatment has become a primary concern for the orthodontists and the patients. The emergence of Piezocision has influenced the efficiency, duration, cost and convenience of accelerated orthodontics dramatically. Here, an effort has been made to compare and assess the rate of retraction between piezocision induced and conventional retraction. **Methodology:** A split mouth study was done on patients requiring first premolar extraction to compare the changes in the rate of retraction where enmasse retraction was done by active tie backs, with piezocision on the experimental side and without piezocision on the control side. A mid-level incision was placed between the roots of the teeth allowed insertion of the piezoelectric knife into cortical and medullary bone to get full effect of regional acceleratory phenomenon (RAP). Measurements were taken at 3 intervals: T0 - Beginning of enmasse retraction, T1 - After completion of enmasse retraction on experimental side and T2 - Bilateral completion of enmasse retraction. Cast measurements were taken at T0 and T1 using digital vernier caliper. **Results:** (1) The rate of retraction was in a velocity of  $1.5275 \pm 0.18337$  mm/month versus  $0.8863 \pm 0.09833$  mm/month with conventional enmasse retraction. (2) The Piezocision side is 1.725 times faster than conventional retraction side. (28.8571/16.7286). **Interpretation and Conclusion:** It was concluded from the study that piezocision assisted enmasse retraction was 1.75 times significantly faster than conventional retraction. The difference in the rate of retraction of both was statistically significant.

**Key words:** Piezocision, Piezotome, Accelerated orthodontics, Regional acceleratory phenomenon (RAP)..

### INTRODUCTION

The demand for speedy, effective and accurate orthodontic treatment systems has increased calling for shorter treatment period. Long orthodontic treatment time poses several limitations like decreased patient enthusiasm, gingivitis, patient compliance, extra hygiene appointments and dental caries. Most of the conventional orthodontic treatments require about two years for completion. Unfortunately, many potential orthodontic patients jeopardize their dental health and decline treatment due to the long treatment duration.<sup>1</sup> The search for mechanical orthodontic processes that cause faster and safer tooth movement has been underway with a number of studies focusing on different components like brackets, arch-wires, orthodontic forces, tissue & cellular factors etc. The emergence of Piezocision has influenced the efficiency, duration, cost and convenience of accelerated

orthodontics dramatically. Piezocision is the flapless method of corticotomy using piezosurgery.<sup>2,3</sup> It is believed that the rapid tooth movement after corticotomy surgery is due to elimination of the resistance of the cortical layer of bone and due to reparative process induced after the injury.<sup>4,5</sup>

Rudimentary surgical intervention to affect the alveolar housing and to speed tooth movement has been used for more than 100 years. Corticotomy facilitated tooth movement was first described by L.C. Bryan in 1893 published in a textbook by S. H. Guilford. As early as the 1950s, periodontists began using a corticotomy technique to increase the rate of tooth movement. In 1959, Henrich Kole was the first to describe modern day corticotomy assisted orthodontics.<sup>6,7</sup> Kole believed that it was the continuity and thickness of the denser layer of cortical bone that offered the most resistance to tooth movement. He was actually creating and moving blocks of bone

in which teeth were embedded by disrupting the continuity of this cortical layer of bone. He postulated this theory as “bony block movement”.<sup>8</sup>

In 1980s, Harold Frost; a distinguished orthopedist realized that there was a direct correlation between the degree of injury to a bone and the intensity of its healing response. He called this the Rapid Acceleratory Phenomenon (RAP). Dr. Thomas Wilcko (Periodontist) and William Wilcko (Orthodontist), of Erie, PA in 1995 further modified the corticotomy assisted orthodontic technique with the addition of alveolar augmentation and named the procedure as Periodontally Accelerated Osteogenic Orthodontics (PAOO) later patented as “Wilckodontics” based on the emerging concepts of Wilcko brothers. Wilcko et al mentioned that corticotomy would increase tooth movement by increasing bone turn over and decreasing bone density.

Dibart et al in 2009, introduced a flapless method of corticotomy using piezosurgery called piezocision. This technique combines microincisions limited to the buccal gingiva that allows the use of a piezoelectric knife to give osseous cuts to the buccal cortex and initiate the RAP without involving palatal or lingual cortex. The procedure allows for rapid tooth movement without the downside of an extensive and traumatic surgical approach while maintaining the clinical benefit of a bone or soft-tissue grafting concomitant with a tunnel approach. The active orthodontic treatment period in patients with corticotomy is 2 to 3 times more rapid compared with patients without corticotomy.<sup>9</sup>

Piezocision is an orthodontically guided surgical procedure. It has evolved from being a minimally invasive surgical alternative to conventional corticotomy to a more sophisticated philosophy where the orthodontist is given the tools to control the anchorage value of teeth by selectively altering the bone density surrounding them.<sup>10,11</sup> This decreased resistance has been explained by the underlying regional acceleratory phenomenon (RAP) that occurs after a wound.<sup>12</sup>

However, there is little literature regarding the effects of piezocision. Therefore the purpose of this study was to compare the rate of enmasse retraction in the two opposite quadrants of the maxillary arch in the same patient, where one side piezocision was done whereas the other side acted as control.

### **Aims and objectives of the study**

1. To assess the rate of enmasse retraction on the piezocision side.
2. To assess the rate of enmasse retraction on the conventional retraction side.
3. To compare the rate of enmasse retraction

between piezocision and conventional retraction side.

4. To draw inferences from the above.

### **Methodology**

The study subjects were patients seeking fixed orthodontic treatment from the Department of Orthodontics and Dentofacial Orthopaedics, Coorg Institute of Dental Sciences, Virajpet, Karnataka.

### **Inclusion criteria**

1. Angle’s class I malocclusion indicated for bilateral maxillary first premolar extraction.
2. Male and female patients between the age group of 15 and 35 years.
3. Patients with no clinical signs of periodontal diseases.
4. Patients with no clinical signs of gingival inflammation.

### **Exclusion criteria**

1. Previous history of any orthodontic or orthopaedic treatment
2. Any bone pathology, ankylosed teeth.
3. Patients taking drugs modifying normal bone physiology (ie, biphosphonates) during or before 3 months of study.
4. Patient having a pacemaker or any other active implant.
5. Pregnant or lactating women
6. Patients who have undergone periodontal treatment within three months of baseline examination.
7. Patients with systemic disorder that could influence the periodontal health.

### **Armamentarium**

1. Piezotome [figure 3]
2. Scalpel + BP blade (no:15c)
3. Topical and local anesthetic.
4. Absorbable suture (VICRYL)
5. Digital vernier calliper (WORKZONE)
6. Force measuring gauge (MORELLI ORTODONTIA).
7. Alginate impression material
8. Orthokal dental stone

## Procedure:

### Orthodontic Appliance

The subjects were bonded with 0.022×0.028 inch slot Pre-

No. of weeks	Minimum	Maximum	Mean	Standard deviation	T	Sig.
<b>Experimental group</b>	12.71	25.00	16.7286	3.51443	6.236	<b>0.000 (H.S)</b>
<b>Control group</b>	22.86	40.43	28.8571	5.04717		

**Table II:** Comparison of weeks taken for space closure on experimental and control side.

P<0.05, \*\*\* Highly Significant

adjusted Edgewise Appliance brackets (MBT koden platinum series). Following the extraction of first premolars, initial leveling and alignment was done. A 0.019×0.025 inch SS arch wire was used to obtain standardization (in-situ for four weeks). This period enabled full arch wire passivity before the piezocision and enmasse retraction. Maxillary arch impressions were then made using alginate at the end of standardization. Before entering to 2<sup>nd</sup> phase which is retraction, piezocision was performed followed by conventional MBT retraction technique using active tie backs. Active tie backs were attached from the maxillary first molar hook to the post between canine and lateral incisor. A measuring gauge was used to measure the retraction force (200 grams/side). The maxillary arch was included with bilateral 2<sup>nd</sup> molar banding and a transpalatal bar as the anchorage system.

### Piezocision Procedure

Small vertical incisions were made using No:15 BP blade on the buccal aspect of teeth, precisely interproximally below the interdental papilla as far as possible in the attached gingiva between central and lateral, lateral and canine, canine and second premolar which is the extraction space. This mid-level incision between the roots of the teeth allowed for insertion of the piezoelectric knife. The tip of the piezotome was inserted to the incision previously made and a 7mm length, 3mm deep piezoelectrical alveolar perforation was performed. The perforation passed through the cortical layer and reached the medullary bone to get full effect of regional acceleratory phenomenon (RAP). After the surgical intervention suturing was done using resorbable suture. Patients were recalled and reviewed every two week to activate the active tie backs. This activation procedure had the advantage of the temporary demineralization phase created by piezocision which in turn fastened tooth movement and helped in early completion of retraction. [figure 1]

Measurements were taken at 3 intervals-

T<sub>0</sub> - Beginning of enmasse retraction

T<sub>1</sub> - After completion of enmasse retraction on experimental

side

T<sub>2</sub> - Bilateral completion of enmasse retraction

Cast measurements were taken at T<sub>0</sub> and T<sub>1</sub> using digital

vernier caliper. [figure 4]

## Results

In the present study, rate of retraction were assessed and compared during enmasse retraction in patients where piezocision was done on the one side while on the other side was retracted using conventional retraction techniques.

A split mouth technique was used in all subjects wherein piezocision was performed in-between central and lateral, lateral and canine, canine and second premolar (which is the extraction space) on the left quadrant of upper arch while the right quadrant was left as control. Photographs were collected at baseline, after completion of enmasse retraction on experimental side and complete closure of enmasse retraction bilaterally [figure 2]. Impressions and study models were also made at baseline and after completion of enmasse retraction on experimental side after piezocision for calculating the rate of retraction.

### Statistical Methods Applied For the Study Were

The data was collected, coded and fed in SPSS (IBM version 23) for the statistical analysis. The descriptive statistics included mean and standard deviation. The inferential statistics included Independent t test for comparison between the two independent groups, that is the experimental and the control group. The level of significance was set at 0.05 at 95% Confidence Interval.

On interpretation no significant differences were seen on comparing the rate of space closure between control side and the experimental side irrespective of time taken. [Table 1]

After Complete Retraction	Mean Reduction	Standard Deviation
<b>Right side</b>	6.3040	.62959
<b>Left side</b>	6.3040	1.00139

**Table I:** Comparison of mean rate of retraction between control side and reaction side

Highly significant differences were seen on comparing the

	PIEZOCISION			CONTROL		
	Distance	Weeks	Velocity (distance/wk)	Distance	Weeks	Velocity (distance/wk)
Pt 1	5.54	15.71	0.35	5.63	22.86	0.25
Pt 2	8.64	25.00	0.35	6.88	40.43	0.17
Pt 3	6.6	16.43	0.4	7.06	30.71	0.23
Pt 4	6.39	12.86	0.5	6.6	25.86	0.26
Pt 5	6.02	17.57	0.34	6.85	31.14	0.22
Pt 6	5.41	15.00	0.36	5.88	30.00	0.2
Pt 7	6.42	16.43	0.39	6.31	28.86	0.22
Pt 8	6.95	19.29	0.36	6.84	29.29	0.23
Pt 9	5.09	12.71	0.4	5.34	23.00	0.23
Pt 10	5.98	16.29	0.37	5.65	26.43	0.21

**Table III:** Comparison of velocity taken for retraction on piezocision side and control side.

weeks taken for space closure between control and experimental side. While the experimental side took a minimum of 12.71±3.5 weeks for complete enmasse space closure, the control side took 22.86±5.04 weeks for the same. Comparing the maximum weeks taken for complete space closure, experimental side took almost 25±3.51 weeks whereas the control side took 40.43±5.04 weeks. This suggests that while the experimental (piezocision) side took a mean of 16.728 weeks for enmasse space closure, the same amount of space closure was achieved by the control side in 28.857 weeks, implying that there was significant reduction in time taken for space closure with experimental group. The mean amount of weeks taken for space closure in both experimental and control side suggests that experimental side is 1.725 times faster than control side (28.857/16.7286).

control side. [Table 4]

Velocity ( Distance/ Month)	Mean	Standard Deviation
<b>Control</b>	.8863	.09833
<b>Piezocision</b>	1.5275	.18337

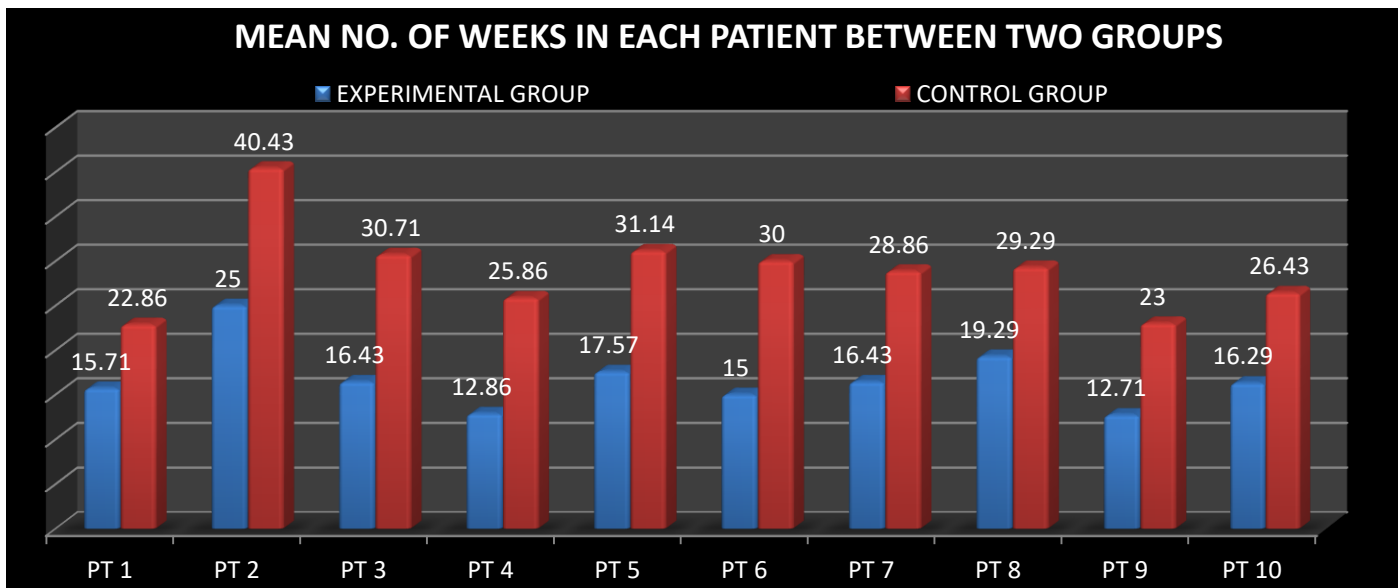
**Table IV:** Mean velocity taken for space closure on piezocision side and control side

Very highly significant differences were seen in the number of weeks taken between experimental and control sides. [Graph 1]

**Graph 1:** Comparison of no of weeks taken for retraction in each subject at Control side and Experimental side.

### Discussion

Corticotomies have been used to assist orthodontic treatment since the late 18th century. There are different surgical techniques available to accelerate tooth movement: PAOO,



[Table 2]

Highly significant differences were seen while comparing the velocity taken between control side and experiment side. [Table 3]

On interpretation of the velocity table, extrapolation of velocities reveals that tooth movement in the piezocision assisted retraction was at a rate of 1.5275±0.18337 mm/month while it was 0.8863±0.09833 mm/ month on

Corticision , Piezocision and Propel<sup>3,4,5,6</sup>. All of the approaches described accelerate orthodontic tooth movement and may protect against root resorption. PAOO and Piezocision offer the option of bone and soft tissue grafting at time of surgery . Corticision , Piezocision and Propel are considered minimally invasive procedures thanks to the flapless approach, but the use of the mallet in Corticision could constitute a trauma for the

patient. The piezoelectric knife creates a more intense Regional Acceleratory Phenomenon (RAP) at the site of injury due to the effect of high frequency vibrations. This suggests that Piezocision could create a greater effect on bone remodeling thereby producing faster tooth movement and extended RAP. The lack of randomized controlled clinical trials makes an effective comparison between these techniques difficult and future studies are needed to better evaluate the outcomes of each of these.

The present study was conducted to assess and compare the rate of enmasse retraction between piezocision and conventional retraction techniques.

### Study Procedure

In the present study, 10 subjects were selected according to the inclusion criteria. Split-mouth technique was used in all subjects wherein the upper left quadrant was designated as the experimental side and the upper right quadrant was designated as the control side. Before commencement of study the patients were advised good oral hygiene methods and also were systematically checked for periodontal problems if any and were given an oral prophylaxis one week prior to study. Piezocision was done on the upper left side and retraction was started on the right and left side simultaneously with conventional active tie backs. At the end of enmasse retraction on experimental side assessment of weeks taken for space closure was noted along with the assessment of space left out in control side. Measurements were noted on both control and experimental side using digital vernier caliper [figure 4]. Impressions and study models were made at baseline and after enmasse space closure on experimental side to assess the rate of retraction. The velocity of tooth movement in both scenario were calculated with assessment of time taken for experimental and control side complete space closure.

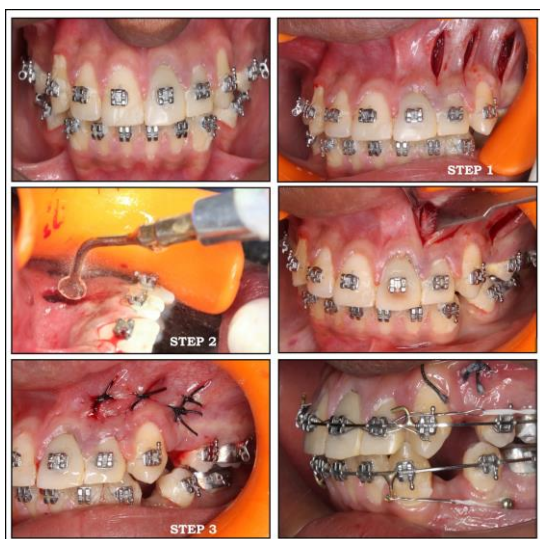

Figure 1: Showing standardization of MBT appliance,

Piezocision procedure step-1: Small vertical incisions made using No:15 BP blade, step-2: Insertion of piezotome, Reflected gingiva showing cuts made using piezotome, Step-3: Suturing and Beginning of enmasse retraction using active tiebacks (T0)

Rate of retraction was evaluated by measuring distance from mesial most point on second premolar to the distal most point of canine using Digital Vernier Calipers. Highly significant differences were seen between control and experimental side for complete enmasse retraction. The mean amount of weeks taken for space closure suggests that experimental side is 1.725 times faster than control side.

Although the piezocision procedure removes less bone than the conventional corticotomy procedure, no clinical difference in bone support or periodontal health was seen between the two sides in this study. This may be explained in the manner of bone removal. The piezocision procedure done was not a true osteotomy, with a block of bone removed. The procedure only perforated the bone in few areas, leaving the original bony architecture intact. This allowed the resorption/deposition cellular process to proceed within the existing architecture. Gingival recession, bone dehiscence, and increase in root resorption were not observed in either experimental and control side. The risk of remaining scars might limit the indications for piezocision in high lip line patients. The patient centered acceptance was satisfactory with this technique, thus considering piezocision as a new promising therapeutic tool for orthodontic treatment.

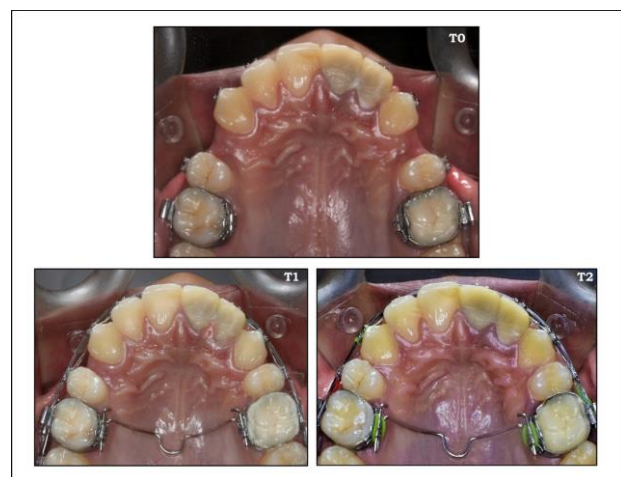

Figure 2: Beginning of enmasse retraction (T0) Completion of space closure on experimental side (T1), Completion of space closure bilaterally (T2)

This new method definitely reduces the treatment time and is a viable method to be incorporated as a routine orthodontic protocol in clinical practice. At this point it is important to emphasize that piezocision has a localized and selective effect on the teeth. Only the teeth, arches or quadrant to be moved need to be operated upon. As the density of the bone around the piezocision cut is less, the anchorage values of the teeth at the

decortication site would be less. Piezocision can be done only around the teeth that are going to be moved and the anchorage values of these teeth can be decreased. Therefore, the need for additional anchorage devices can be eliminated by designing the alveolar decortications according to the desired tooth movements.

### Comparison with Other Similar Studies

Our study showed similarity with another study done by **Abbas NH, Sabet NE, Hassan IT<sup>1</sup>** who evaluated corticotomy-facilitated orthodontics and piezocision in rapid canine retraction. The sample was divided into 2 equal groups. In the first group, 1 side of the maxillary arch was randomly chosen for treatment with corticotomy, and in the second group, piezocision treatment was used. The contralateral sides of both groups served as the controls. Cuts and perforations were performed with a piezotome, and canine retraction was initiated bilaterally in both groups with closed coil nickel-titanium springs that applied 150 g of force on each side. It was concluded that corticotomy-facilitated orthodontics and piezocision are efficient treatment modalities for accelerating canine retraction.

### Conclusion

The present study was conducted to assess and compare the rate of enmasse retraction between piezocision and conventional retraction techniques.

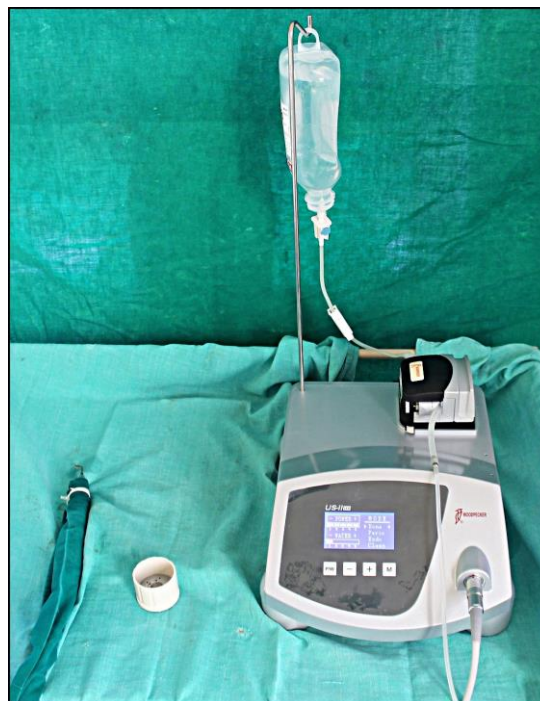It was concluded from the study that the experimental side where piezocision was done showed faster space closure than control side. Piezocision assisted enmasse retraction was 1.75 times significantly faster than conventional retraction.

This study also showcased velocities of retraction which revealed that the piezocision-assisted teeth moved at a rate of 1.5275mm/month against 0.08863 mm/month on control side.

### Summary

The present study was conducted to assess and compare the rate of enmasse retraction between piezocision and conventional retraction techniques. A split mouth technique was used in all subjects wherein the upper left quadrant was designated as the experimental side and the upper right quadrant was designated as the control side. Piezocision was done on the upper left side and retraction was started on the right and left side simultaneously with conventional active tie backs. Active tie backs dissipated about 200 gms of force. At the end of enmasse retraction on experimental side assessment of weeks taken for space closure was noted along with the assessment of space left out in control side. Measurements were noted on both control and experimental

side using digital vernier caliper. Impressions and study models were made at baseline and after enmasse space closure on experimental side to assess the rate of retraction.



**Figure 3:** Piezotome unit

Rate of retraction was evaluated by measuring distance from mesial most point on second premolar to the distal most point of canine using Digital Vernier Calipers. Piezocision side showed rapid enmasse retraction compared to control side.



**Figure 4:** Space closure in experimental and control sides at T0, T1 and T2

Following parameters were compared:

- Variation in Control side and Experimental side at three

time intervals.

- Rate of retraction

The study concluded that:

1. The rate of retraction was significantly higher in piezocision assisted retraction when compared with conventional enmasse retraction.
2. The velocity of piezocision assisted retraction was at a rate of 1.5275mm/month against 0.8863mm/month on control side.
3. The Piezocision side was 1.725 times faster than conventional retraction side.

## References

1. Abbas NH, Sabet NE, Hassan IT. Evaluation of corticotomy-facilitated orthodontics and piezocision in rapid canine retraction. *American Journal of Orthodontics and Dentofacial Orthopedics*. 2016 Apr 30;149(4):473-80.
2. Ileri Z, Akin M, Erdur EA, Dagi HT, Findik D. Bacteremia after piezocision. *American Journal of Orthodontics and Dentofacial Orthopedics*. 2014 Oct 1;146(4):430-6.
3. Dibart S, Yee C, Surmenian J, Sebaoun JD, Baloul S, Goguet-Surmenian E, Kantarci A. Tissue response during Piezocision-assisted tooth movement: a histological study in rats. *European journal of orthodontics*. 2013 Nov 19;36(4):457-64.
4. Fischer TJ. Orthodontic treatment acceleration with corticotomy-assisted exposure of palatally impacted canines: a preliminary study. *The Angle Orthodontist*. 2007 May;77(3):417-20.
5. İşeri H, Kişnişçi R, Bzizi N, Tüz H. Rapid canine retraction and orthodontic treatment with dentoalveolar distraction osteogenesis. *American journal of orthodontics and dentofacial orthopedics*. 2005 May 1;127(5):533-41.
6. AlGhamdi AS. Corticotomy facilitated orthodontics: Review of a technique. *The Saudi dental journal*. 2010 Jan 1;22(1):1-5.
7. Keser EI, Dibart S. Sequential piezocision: a novel approach to accelerated orthodontic treatment. *American Journal of Orthodontics and Dentofacial Orthopedics*. 2013 Dec 1;144(6):879-89.
8. Milano F, Dibart S, Montesani L, Guerra L. Computer-guided surgery using the piezocision technique. *International Journal of Periodontics & Restorative Dentistry*. 2014 Jul 1;34(4).
9. Dibart S, Keser E, Nelson D. Piezocision™-assisted orthodontics: Past, present, and future. In *Seminars in Orthodontics 2015 Sep 1* (Vol. 21, No. 3, pp. 170-175). WB Saunders.
10. Dibart S. Piezocision™: Accelerating orthodontic tooth movement while correcting hard and soft tissue deficiencies. In *Tooth Movement 2016* (Vol. 18, pp. 102-108). Karger Publishers.
11. Charavet C, Lecloux G, Bruwier A, Rompen E, Maes N, Limme M, Lambert F. Localized piezoelectric alveolar decortication for orthodontic treatment in adults: a randomized controlled trial. *Journal of dental research*. 2016 Aug;95(9):1003-9.
12. Alfawal AM, Hajeer MY, Ajaj MA, Hamadah O, Brad B. Effectiveness of minimally invasive surgical procedures in the acceleration of tooth movement: a systematic review and meta-analysis. *Progress in orthodontics*. 2016 Dec 1;17(1):33.