

Interdisciplinary Approach to Cleft Lip and Palate Management: A Case Report

To cite: Abhay Kumar Jain, Ambesh Rai, Anand K Patil, Sanjay V Ganeshkar - Interdisciplinary Approach to Cleft Lip and Palate Management: A Case Report Journal of Contemporary Orthodontics, April -June 2019;3(2): 44-49

Received on:

10-04-2019

Accepted on:

13-05-2019

Source of Support: Nil

Conflict of Interest: None

¹Abhay Kumar Jain, ²Ambesh Rai, ³Anand K Patil, ⁴Sanjay V Ganeshkar

¹Reader Department of Orthodontics & Dentofacial orthopedics Hazaribag College of Dental Sciences and Hospital Jharkhand.

²BDS, MDS. Specialist Orthodontist, Saray Clinic, Kuwait.

³Prof and Head, Department of Orthodontics & Dentofacial orthopedics, SDM College of Dental Sciences and Hospital, Dharwad, Karnataka.

⁴Prof and Head, Department of Orthodontics & Dentofacial orthopedics, P.M.N.M Dental College and Hospital, Bagalkot, Karnataka.

ABSTRACT

Cleft Lip and Palate is the most common congenital abnormalities of the orofacial region. Management of these patients requires a multispeciality approach. A 13-year-old post-pubertal female patient presented with cleft lip and palate, collapsed upper arch, oroantral fistula, missing upper left lateral incisor, deviated nasal septum (DNS) and hypernasality of voice. The orthodontic treatment objectives were to align and expand the arches to correct the crossbite and provide sufficient space for bone grafting to close the oro-antral fistula and replacement of lateral incisor to achieve acceptable facial aesthetics. The patient was treated using a preadjusted edgewise appliance. Arch expansion was carried out using quad helix; subsequently alveolar bone grafting was performed to close oroantral fistula, Maryland bridge was placed to replace missing upper left lateral incisor. Adjunctively, septoplasty was done to address DNS and speech therapy for hypernasality. At the end of treatment Class I canine and molar relationship were achieved bilaterally, the crossbite was corrected and the missing maxillary lateral incisor was replaced with a Maryland's bridge as an interim prosthesis till future implant placement. Posttreatment records showed excellent results with good occlusion, facial balance and esthetic harmony

Key words: Twin Block, MRI, Skeletal Class II malocclusion.

INTRODUCTION

Cleft lip and palate is the most common congenital craniofacial malformations with an incidence of approximately 0.36 to 0.83 per 1000 live births with a multifactorial etiology.¹ The problems associated with cleft ranges from growth defect, dental arch abnormality, morphological defect, speech defect repeated infections and surgery associated morbidity to an endless psychosocial trauma of "ever gazing" eyes.²

The Orthodontic aspect of treatment involves naso-alveolar moulding, arch expansion and growth redirection at various stage of treatment. The appropriate treatment regime is case specific determined predominantly by patient's age and growth status.

Cleft closure is usually done with autogenous bone grafting. According to the time of placement, the graft is classified as primary, secondary and tertiary. When performed during early childhood, at the same time as the primary repair surgeries, bone graft is called as primary. It facilitates feeding and normal speech

development however, the scar tissue can cause impediment of maxillary growth and hence is mostly abandoned.

Bone grafting is called as secondary when performed later at the end of the mixed dentition. It is the most accepted procedure and is performed preferably before eruption of the permanent canine in order to provide adequate periodontal support for eruption and preservation of the teeth adjacent to the cleft.

When bone grafting is performed in the permanent dentition after the completion of orthodontic treatment, it is called a tertiary or late graft. Tertiary grafts are performed to enable prosthodontic and periodontal rehabilitation and to assist in the closure of persistent oro-antral fistulae. A tertiary or late bone grafting cannot repair bone loss in teeth adjacent to the cleft. Occasionally, tertiary graft causes progressive cervical root resorption of teeth adjacent to the cleft, especially canines. Such root resorption is caused by the contact of the grafted bone to the exposed root surface. Secondary bone grafting on the other hand can repair the cleft alveolus without adversely affecting the effect of primary surgery seen on the maxillary growth.³⁻⁷

Grafted cancellous bone fills in the residual alveolar cleft and is anatomically joined to the adjacent bone, becoming indistinguishable in radiographic images after an average period of 3 months.

grafting). During the pre-bone-grafting phase, the upper dental arch is prepared for the graft and the permanent incisors are aligned.

The pre graft orthodontic treatment also results in better access

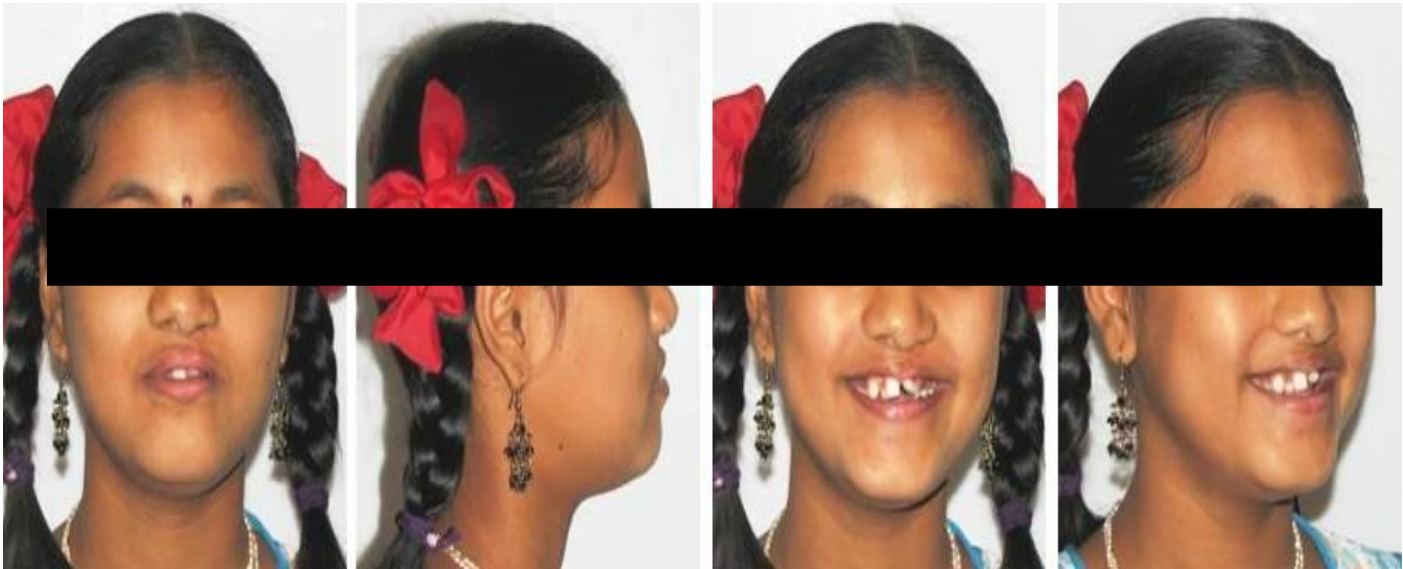
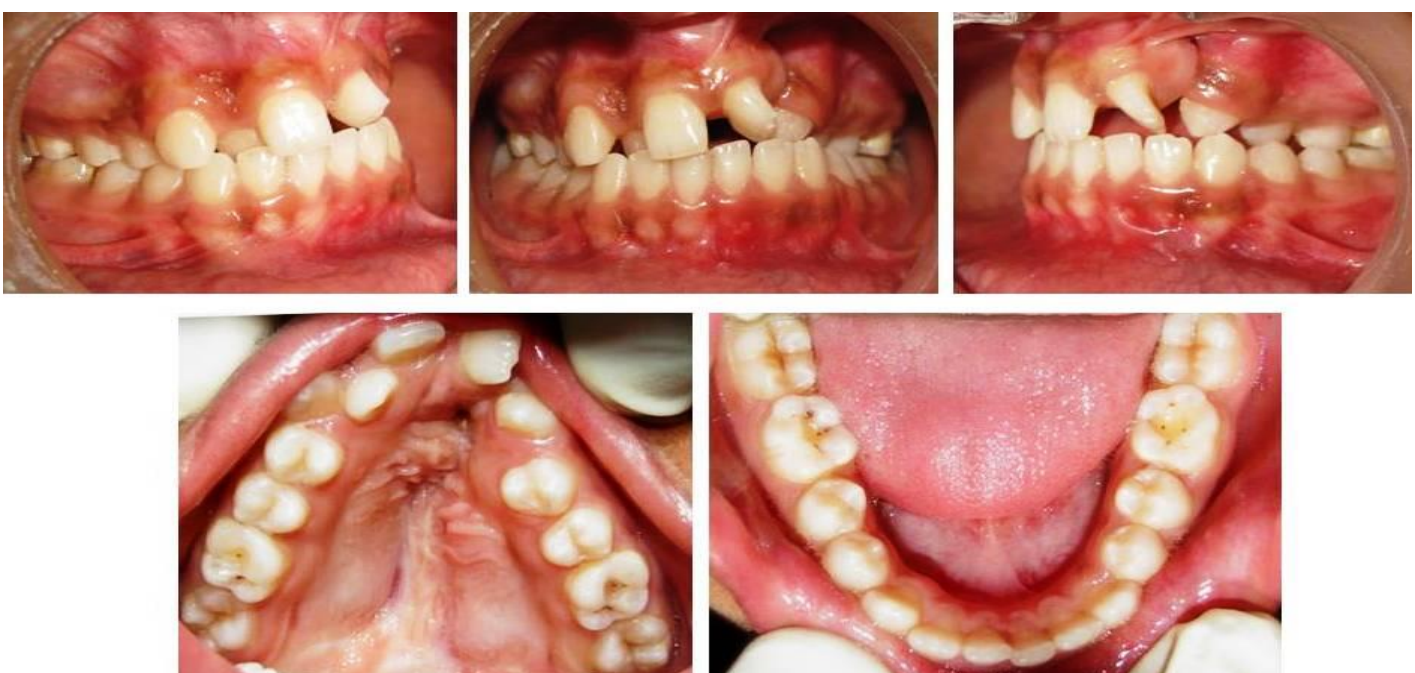
Figure 1: Pretreatment Extraoral Photographs

ORTHODONTIC PERSPECTIVE OF BONE GRAFTING

From an orthodontist perspective, the most important benefit of secondary bone grafting is that the newly grafted bone acts as alveolar bone, allowing the spontaneous migration of the adjacent canine towards the ridge. Therefore, bone grafting has become mandatory in the treatment protocols of cleft patients, establishing two well-defined stages for orthodontic mechanotherapy (pre and post-secondary bone

for the surgeon at the time of the grafting procedure. The pre-surgical orthodontic preparation involves predominantly transverse mechanics with the use of orthodontic or preferable orthopaedic expansion during the mixed dentition in order to reposition the palatal segments. Occasionally some patients are subjected to maxillary protraction in addition to expansion in order to correct maxillary antero-posterior deficiencies. Three months after the bone graft procedure, and depending on the radiographic image of the area, orthodontic treatment is restarted to correct the position of the permanent teeth. This phase involves movement of the teeth through the grafted area⁸⁻¹²



Following orthodontics, prosthetic replacement, lip revision surgery and rhino/ septoplasty is performed to correct the nasal defect. **Figure 2:** Pretreatment Intraoral Photographs

CASE REPORT

A 13 years old post pubertal female patient presented with the chief complaint of irregularly placed teeth and difficulty in speech. She gave a history of surgical repair of cleft of lip alveolus and palate at very young age.

Extraoral examination revealed a leptoprosopic facial pattern with a straight profile, deviated nasal septum to the right, surgical scar on right side of lip with minimal show of incisors on smiling. (fig.1) Intraoral examination revealed full complement of teeth from second molar to second molar in both the arches except maxillary left lateral incisor, scar of surgically repaired cleft palate on the left and an oroantral fistula (positive water test), collapsed and crowded maxillary arch with a relatively well aligned mandibular arch, class I molar relation on the right and end on on the left side and class I canine relation on the right and class II on the left side. An overbite of 2mm overjet of 1 mm.(fig. 2) Hypernasality of speech were also present. (fig.2)

TREATMENT OBJECTIVES

1. Arch expansion to align the upper arch
2. Alveolar bone grafting to repair the oroantral fistula
3. Fixed mechanotherapy to detail the occlusion
4. Prosthetic rehabilitation for the missing lateral incisor
5. Rhino/ septoplasty to correct DNS
6. Speech therapy to improve hypernasality

A Quad helix appliance was used to expand the maxillary arch bilaterally.(fig. 3) 0.022x0.028” Metal MBT™ versatile+ (3M Unitech) were used to align the upper arch sequencing NiTi (fig. 4) through steel wires of progressive higher gauge.

With regular activation of Quad helix upper arch was overcorrected till the palatal cusps of upper buccal teeth occlude with the lower buccal cusps. (fig. 5 and 6)

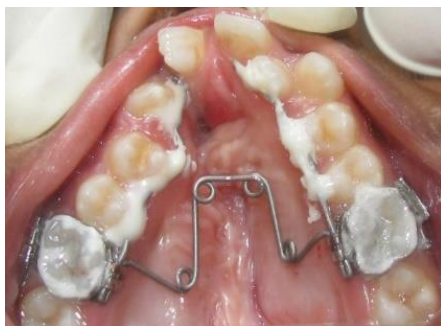

Figure 3: Maxillary arch expansion using Quad Helix

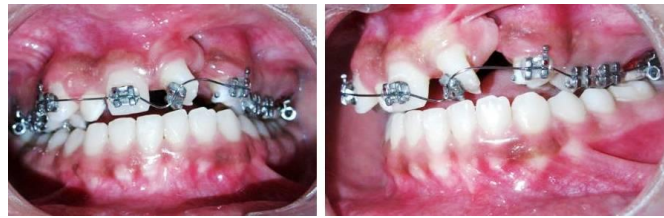

Figure 4: Bonding with 0.022x0.028” Metal MBT™ versatile plus Brackets

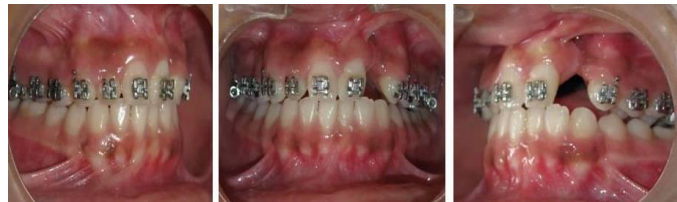

Figure 5: Intraoral Photographs after maxillary arch Expansion

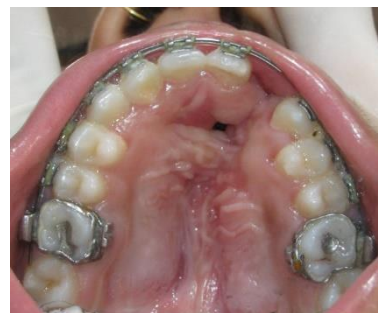

Figure 6: Occlusal Photographs after maxillary arch Expansion

Post expansion the patient underwent a secondary bone grafting in the cleft region using iliac crest graft (fig. 7 and 8). Simultaneous lip revision with columelloplasty was done to correct the nasal deformity.

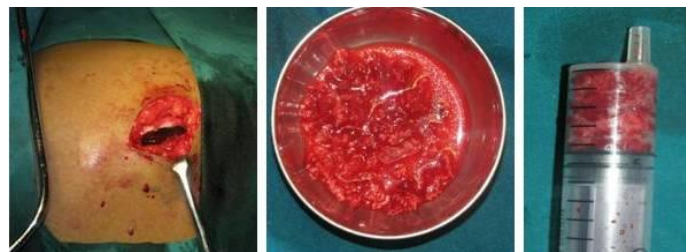


Figure 7: Harvesting Cancellous Bone from Iliac Crest

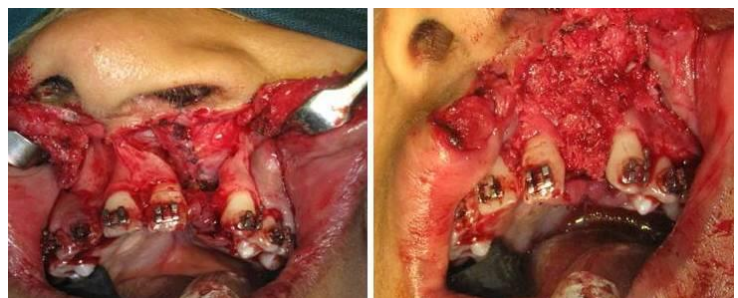

Figure 8: Secondary Bone Grafting into the Cleft Site

The lower arch was strapped up three months post-surgically for levelling and aligning. The arch expansion was maintained using 0.9mm stainless steel wire.

Debonding was done after attaining a good occlusion. Following debonding the missing lateral was replaced with a Maryland bridge till the patient was sufficiently mature to have implant supported prosthesis or fixed bridge deemed appropriate by the prosthodontist at that time. (fig. 9)

The facial photographs after the bone grafting and lip revision showed a commendable change in the nasal and lip deformity. (fig. 10)

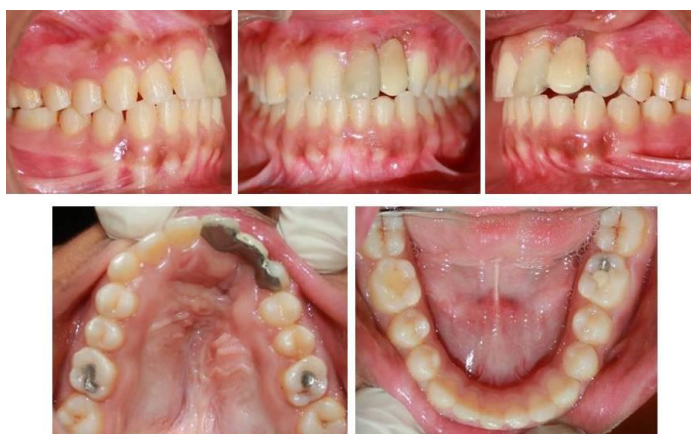

Figure 9: Posttreatment Intraoral Photographs

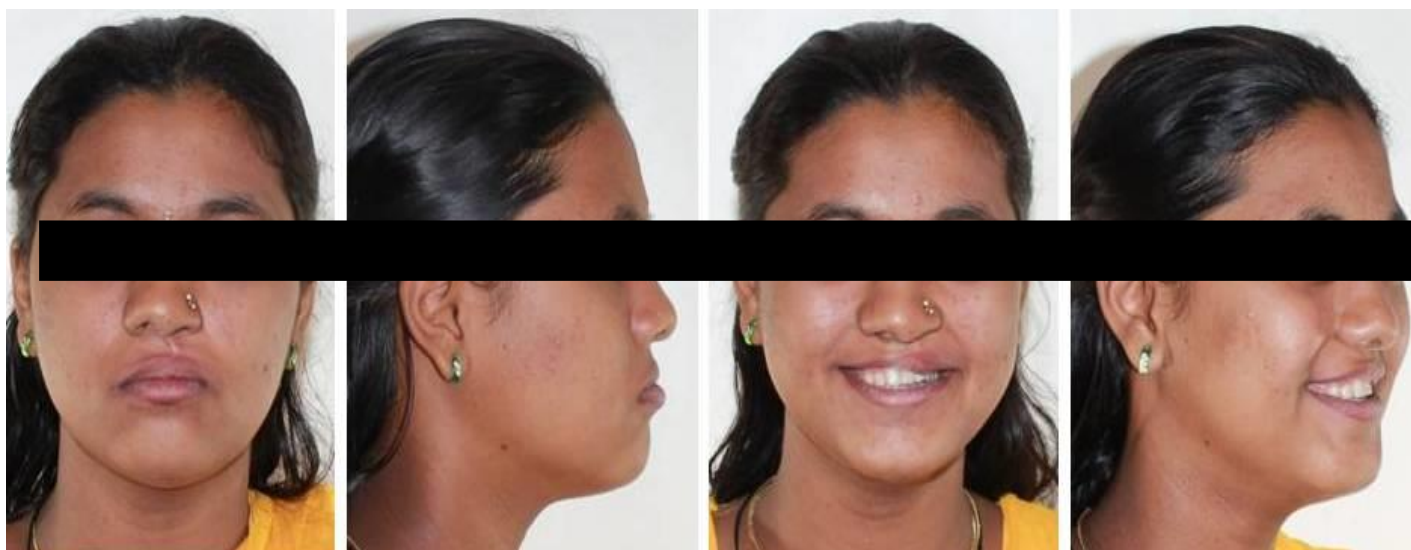

Figure 10: Posttreatment Extraoral Photographs

Post treatment retention was ensured in form of upper and lower lingual bonded retainers and upper wrap around retainer which additionally provided the benefit of preventing the upper arch from collapsing. After an adequate lip support was obtained by the prosthesis a septoplasty was carried out. The patient simultaneously underwent regular speech therapy sessions for her hypernasality which showed marked improvement due to closure of oroantral fistula, septoplasty, restoration of oral dimension and rigorous speech therapy sessions. Thus with a team approach an acceptable form, function and aesthetic were restored.

DISCUSSION

Clefts of the lip and palate can be caused by many etiologic factors but it has been demonstrated that the great majority is caused by the interaction of genetic and environmental

factors.^{13,14} It has been observed that cleft lip and palate patients present with more dental anomalies than do individuals without clefts due to the cleft itself or the early surgery.^{15,16} It has been hypothesized that the absence of fusion between the maxillary and medial processes that result in the cleft, and, is a contributing factor for the various anomalies that affect the lateral incisor.^{17,18} This could explain the frequent absence of lateral incisors, or their distal or

mesial location with respect to the cleft as well as the presence of supernumerary teeth in the same region.¹⁹ Knowledge of dental anomalies occurring in cleft lip and palate patients is fundamental for treatment planning since some of these anomalies may lead to edentulous spaces in the maxillary arch that must be closed by orthodontic movement, prostheses, or implants.

All patients of the SDMCDS, Dharwad underwent the same

treatment protocol: (1) primary surgeries performed during childhood (lip repair after 3 months of age and palate repair after 12 months of age); (2) no early pre- and post-surgical maxillary orthopedics; (3) orthodontic treatment during the mixed dentition; (4) secondary bone graft at the end of the mixed dentition; and (5) fixed orthodontic treatment during the permanent dentition.

Early secondary bone grafting, between the ages of 2 and 6 is done primarily to provide alveolar bone support for the eruption of the lateral incisor. The lateral incisor is often malformed, congenitally missing, or erupts ectopically. Radiographic evaluation of the lateral incisor and canine associated with the cleft defect will help to determine timing of the graft. 95% of the

anteroposterior and transverse growth is completed by the age of 8 and therefore the most common time for alveolar cleft grafting is between the ages of 9 and 11 (before the eruption of the canine when the root is 1/2 to 2/3 formed). Anteroposterior and transverse growth is completed by this age and only vertical growth remains. Grafting between the ages of 9 and 11 does not have much effect on midface growth and will provide bony support for the erupting canine^{20, 21,22}. The anterior iliac crest is the most common donor site used today (gold standard). This site is preferred as the amount of bone, which can be mobilized in adequate amount and has high particulate cancellous bone content. Calvarium and mandibular bone has been advocated, as being a superior donor however there is inconsistent clinical results. However, the bone is membranous, less particulate cancellous bone and quantity harvested is inadequate.

Cancellous bone graft is quickly incorporated and vascularized and, most importantly, does not interfere in the formation of the teeth adjacent to the cleft. This statement has been proved histologically and radiographically.²³ The presence of the tooth contributes to the preservation of the grafted bone and to the differentiation of the periodontal support.

Pre-bone grafting orthodontic management is begun in the mixed dentition stage with the correction of cross bites and the alignment of the anterior teeth. Expansion appliances should be left in place for a minimum of 3 months following placement of the graft to prevent a relapse. Preoperatively the surgeon must evaluate soft tissue for adequate closure, must plan flap design to maintain adequate blood supply, periodontal support of dentition, oronasal communication, and support of the alar base and evaluate the donor site. The three fundamental principles: nasal side closure first, adequate volume of bone and water tight tension free closure of the mucosa. Nasal intubation should be done opposite the side of the cleft. Incision is made as to allow the mucosa of the vertical portion of the cleft to be used for the closure of the nasal floor. The surgical goal is a three-layer closure. Following a watertight closure of the nasal floor the palatal and buccal mucosal flaps are elevated and mobilized. Flap design and blood supply is paramount in successful grafting.^{24,25}

CRITICAL APPRAISAL AND CONCLUSION

Post treatments bilateral class I canine and molar relation were achieved. The soft tissue profile was acceptable; however, some lower lip procumbence was still present. Her hypernasality showed marked improvement due to closure of oroantral fistula, septoplasty, restoration of oral dimension and rigorous speech therapy sessions. Post septoplasty

patient's facial aesthetics showed considerable improvement. The patient was satisfied with the treatment result.

REFERENCES

1. Vanderas AP. Incidence of cleft lip, cleft palate, and cleft lip and palate among races: a review. *Cleft Palate J* 1987;24:216-25.
2. Profit W., Fields W.H, Sarver M.D. *Contemporary Orthodontics* -vol:4, 74-75, Elsevier publishers .2001
3. Johanson B, Ohlsson A. Bone grafting and dental orthopedics in primary and secondary cases of cleft lip and palate. *Acta Chir Scand* 1961 ;122:112-124,
4. Friede H, Johanson B. A follow up study of cleft children treated with primary bone grafting. 1. Orthodontic aspects. *Scand J Plast Reconstr Surg* 1974;8:88-103.
5. Lilja J, Moller M, Friede H, Lauritzen C, Petterson LE, Johanson B. Bone grafting at the stage of mixed dentition in cleft lip and palate patients. *Scand J Plast Surg Hand Surg* 1987;21:73-79.
6. Witsenburg B. The reconstruction of anterior residual bone defects in-patients with cleft lip, alveolus and palate. A review. *J Maxillofac Surg* 1985;13:197-208.
7. Boyne PJ, Sands NR. Secondary bone grafting of residual alveolar and palatal clefts. *J Oral Surg* 1972;30:87-92.
8. Enemark H, Sindet-Pedersen S, Bundgaard M. Long term results after secondary bone grafting of alveolar clefts. *J Oral Maxillofac Surg* 1987;45:913-919.
9. Hinrichs JE, El Deeb ME, Waite DE, Bevis RR, Bandt CL. Periodontal evaluation of canines erupted through grafted alveolar cleft defects. *J Oral Maxillofac Surg* 1984;42:717-721.
10. Troxell JB, Fonseca RJ, Osbon DB. A retrospective study of alveolar cleft grafting. *J Oral Maxillofac Surg* 1982;40:721-725.
11. Epstein LI, Davis WB, Thompson LW. Delayed bone grafting in cleft palate patients. *Plast Reconstr Surg* 1970;46:363-367.
12. Johanson B, Ohlsson A, Friede H, Ahlgren J. A follow up study of cleft lip and palate patients treated by orthodontics, secondary bone grafting and prosthetic rehabilitation. *Scand J Plast Reconstr Surg* 1974;8:121-135.
13. Letra A, Menezes R, Granjeiro JM, Vieira AR. Defining sub phenotype of oral clefts based on dental development. *J Dent Res*, 86: 986-991,2007.
14. Cobourne MT. The complex genetics of cleft lip and palate. *Eur J Orthod*, 26: 7-16, 2004.

15. Menezes R, Vieira AR. Dental anomalies as part of the cleft spectrum. *Cleft Palate Craniofac J*, 45: 414–419, 2008.
16. Will LA. Growth and development in patients with untreated clefts. *Cleft Palate Craniofac J*, 37: 523–526, 2000.
17. Kim NY, Baek SH. Cleft sidedness and congenitally missing or malformed permanent maxillary lateral incisors in Korean patients with unilateral cleft lip and alveolus or unilateral cleft lip and palate. *Am J Orthod Dentofacial Orthop*, 130: 752–728, 2006.
18. Ribeiro LL, Neves LTD, Costa B, Gomide MR. Dental development of permanent lateral incisor in complete unilateral cleft lip and palate. *Cleft Palate Craniofac J*, 39: 193–196, 2002.
19. Tsai TP, Huang CS, Huang CC, See LC. Distribution patterns of primary and permanent dentition in children with unilateral complete cleft lip and palate. *Cleft Palate Craniofac J*, 35: 154–160, 1998.
20. Semb G. Effects of alveolar bone grafting on maxillary growth in unilateral cleft lip and palate patients. *Cleft Palate J* 1988;25:288-295.
21. Amanat N, Langdon JD. Secondary alveolar bone grafting in clefts of the lip and palate. *J Craniomaxillary Surg* 1991;19:7-14.
22. Enemark H, Simonsen EK, Schramm JE. Secondary bone grafting in unilateral cleft lip palate patients: indication and treatment procedure. *Int J Oral Surg* 1985; 14:2-10.
23. Boyne PJ. Use of marrow-cancellous bone grafts in maxillary alveolar and palatal clefts. *J Dent Res*. 1974;53:821–824.
24. Brattstrom V, McWilliam J. The influence of bone grafting age on dental abnormalities and alveolar bone height in patients with unilateral cleft lip and palate. *Eur J Orthod* 1989;11:351-358.
25. Sullivan KO. Tooth eruption in the bone grafted maxillary cleft alveolus. *Int J Oral Surg* 1981; 10:309-312.