

# A novel method for adapting miniplate to infra zygomatic crest

Sasidhar Y.N.<sup>a</sup>, Navya P.<sup>b</sup>, Gangadhara Prasad K.<sup>c</sup>, Ujwala T.<sup>d</sup>, Prudvi Raju A.<sup>e</sup>

**A**nchorage is the resistance to unwanted tooth movement<sup>1,2</sup> This reciprocal reaction is a normal consequence of the orthodontic force applied. This could however be detrimental to the success of orthodontic treatment as anchor loss or anterior movement of anchor units could limit the space available for correcting malocclusions.

There has been a paradigm shift in the recent past where Temporary Anchorage Devices are being extensively used for anchorage purposes to overcome the disadvantages of traditional anchorage solutions such as extraoral anchorage and other intraoral appliances.<sup>3,4</sup> These TADs are fixed to bone temporarily during the treatment period to provide anchorage and can be removed thereafter.<sup>5</sup>

The first idea of using TADs dates back to 1945 when vitallium screws were placed in the ramus of 6 dogs by Gainsforth and Higley to which they applied 140 to 200gms of force.<sup>6</sup> One of the earliest reports was of a case where a surgical vitallium screw was placed just below the anterior nasal spine which was used as an anchor unit for intrusion of the upper anteriors.<sup>3</sup>

Temporary Anchorage devices can be broadly classified as Mini Screws and Miniplates. A miniscrew is a device for anchorage control which can be placed in various locations intraorally. Miniscrews are usually made from biocompatible materials such as titanium and are designed to be placed in any area of alveolar bone with attached gingiva. They are made in various lengths such as 6mm, 8mm, 12mm and are usually of 1.5mm to 2mm in width. Easy installation, reduced cost and greater comfort for the patient have made it a popular choice for orthodontic anchorage.

However, anchorage with miniscrews come with complications such as root penetration, fracture, damage to anatomical structure, periimplantar inflammation, formation of hyperplastic tissue around the mini-implant and difficulty in applying the elastic force. The other major problem associated with miniscrews is failure. Miniscrews also cannot be used when true intrusion or movement of the entire maxillary segment is required as they cannot be placed in regions such as the zygomatic buttress or in regions where unattached gingiva is present. This has prompted orthodontists to look for other reliable and stable sources of anchorage.

Miniplates gradually became a popular choice because of the several advantages they have over miniscrews. They were first reported by Sugawara<sup>7</sup> for the purpose of distalization of molars. Tooth movement can be performed in all planes when miniplates are used as anchorage units as they are placed beyond the apices of the teeth. These are also recommended when higher orthodontic forces have to be applied or when a large segment of teeth have to be moved.<sup>8</sup>

Commercially pure titanium is the material of choice to manufacture miniplates as it is biocompatible and suitable for osseointegration. The anchor plate consists of three parts—the head, the arm, and the body. Three continuous hooks are available on the head component which projects into the oral cavity. It is placed such that it does not hinder tooth movement. Elastics are placed onto the hooks to apply force. The transmucosal arm component is available in three different lengths—short (10.5 mm), medium (13.5 mm), and long (16.5 mm). Different lengths can be chosen as per the anatomy of the patient's maxilla and zygoma. The designs available for the body are the T-plate, the Y-plate, and the I-plate and are placed subperiosteally. One arm of the T plate can be cut off to be used as an L plate if required.<sup>7</sup>

An ideal cortical thickness of at least 2mm is required to fix the anchor plates. Monocortical screws which measure 2.0 mm in diameter and 5.0 mm in length and have an internal tapered square head with a self-tapping threaded body are used to fix plates.<sup>7</sup> The mucosa surrounding the miniplate after placement should be of the keratinized type. The alveolar mucosa is more prone to infection and thereby may lead to miniplate failure.<sup>9</sup>

The zygomatic buttress and the piriform rim are the ideal locations for placement of the miniplate when it has to be used for anchorage in the maxillary arch. The Y-plate is usually placed in the zygomatic buttress when distalization of molars is required. When intrusion of maxillary anteriors is required, the I-plate is used and is placed in at the anterior ridge of the piriform opening.<sup>7</sup>

The main complications associated with use of miniplates for orthodontic anchorage are inflammation and/or infection around the miniplate due to poor oral hygiene which could further lead to failure of the miniplates. Failure could also occur when high traction force is applied. The jugal mucosa is sometimes irritated by miniplates and may cause discomfort to the patient.<sup>10,11</sup>

The major consideration with regards to a miniplate placement is the requirement of a minor surgical procedure under local anesthesia. The miniplate should be placed with minimum discomfort and without causing any morbidity to the patient as it is an adjunctive procedure. Adaptation of the miniplate to the anatomical structures at the chair side would be time consuming thereby increasing the chances of discomfort. Adaptation of the miniplate directly on the patient will not be precise and may cause loosening and failure of the miniplates. Pre-adaptation and contouring of the miniplate would not only save chair side time but also allow placement of the miniplate at the ideal location with precision.

A novel method for adapting miniplates is described here with which the surgical procedure would become a relatively easier and smooth procedure.

## The procedure is described under the following headings:

- Obtaining a Cone Beam Computed Tomography (CBCT Scan)
- Converting DICOM image to STL Format using software
- Fabrication of Prototype of the Structure from the Obtained Image
- Adaptation of the Miniplate
- Surgical Positioning of the Miniplate Intraorally

<sup>a</sup>. Professor. Department of Orthodontics, GITAM Dental College & Hospital, Visakhapatnam

<sup>b</sup>. Reader. Department of Orthodontics, GITAM Dental College & Hospital, Visakhapatnam

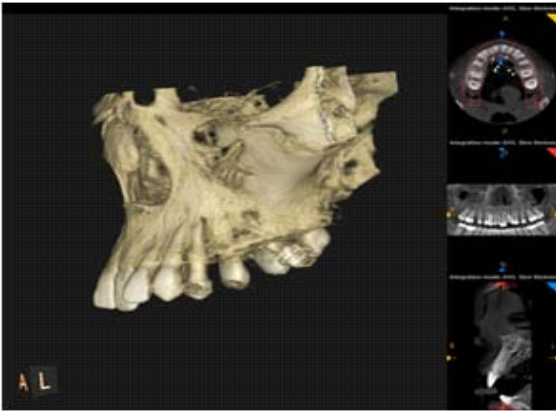
<sup>c</sup>. Professor & Head. Department of Orthodontics, GITAM Dental College & Hospital, Visakhapatnam

<sup>d</sup>. Reader. Department of Orthodontics, GITAM Dental College & Hospital, Visakhapatnam

<sup>e</sup>. Post-Graduate Student. Department of Orthodontics, GITAM Dental College & Hospital, Visakhapatnam

**Obtaining a Cone Beam Computed Tomography (CBCT Scan)**

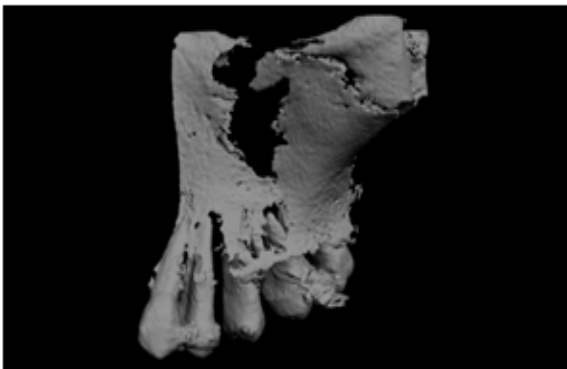
A CBCT scan of the required area is taken to plan the placement of a miniplate. A three dimensional image is constructed from the CBCT thus obtained. (Fig.1)



**Fig 1. CBCT Scan**

**Converting DICOM image to STL format using Software**

The image obtained is in DICOM format (Digital Imaging and Communication in Medicine). After planning of the placement of miniplate is completed, the DICOM format is converted to a STL (Stereolithography) format using a DICOM Imaging Software. (Fig2.)



**Fig 2. Converting DICOM image to STL format using Software**

**Fabrication of Prototype of the Structure from the Obtained Image**



The STL image is then sent to a 3-D printer to create a prototype of the structure which is the Stereolithographic working model. (Fig3)



**Fig 3. Fabrication of Prototype of the Structure from the Obtained Image**

**Adaptation of the Miniplate**

Commercially available miniplates (Y plates) are adapted onto the stereolithographic models. Precise adaptation of the base of the miniplate to the contour of the infra zygomat crest is done on the model. (Fig4&5)

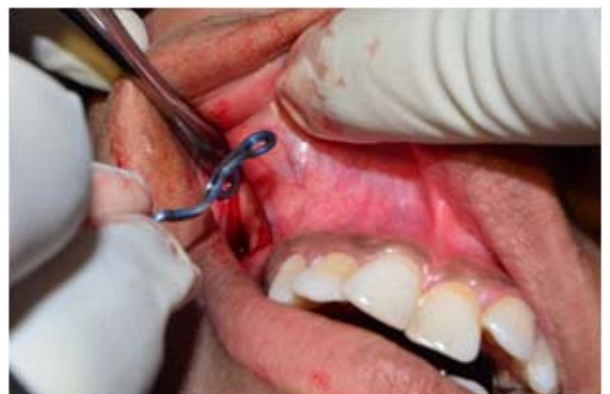

**Fig 4 & 5. Adaptation of the miniplate onto the stereolithographic model**

**Surgical Procedure**

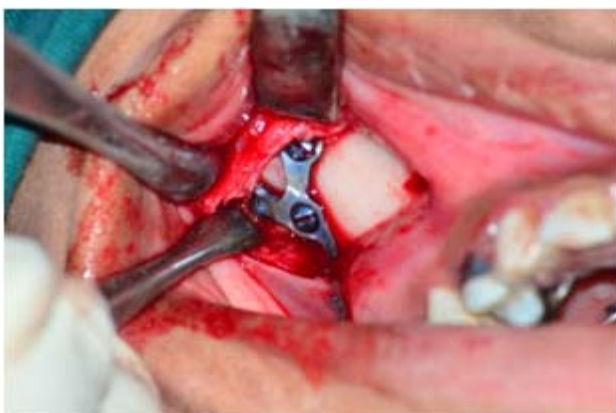
The surgical procedure is performed under local anesthesia. It is similar to the procedure for Bollard Skeletal Anchorage devices placement on maxilla (infra zygomat crest).<sup>12</sup>

After incision is made, the mucoperiosteal flap is raised to expose the bone upto the infra zygomat crest. The adapted miniplate from the STL working model is positioned on the infra-zygomat crest and checked for a proper fit.(Fig6)



**Fig 6. Surgical procedure**

The middle hole of the miniplate is drilled using a 1.6mm diameter round surgical bur. The first screw is not completely fixed in order to allow for some rotation of the miniplate. Once the plate is properly positioned all the three screws are fixed for stable retention. (Fig7)



**Fig 7. Precise positioning of the miniplate at the surgical site**

Finally, the base of the miniplate is covered with the flap such that only the connection bar projects out. The flap is then sutured into position.

### Conclusion

Miniplates are ideal for use as temporary anchorage devices as they provide the desired anchorage and can be used even with moderately high forces and their stability is higher than the other available options such as miniscrews.

The drawback with this method is the requirement of a CBCT image and increased cost.

### References :

1. Lindquist JT. The edgewise appliance. In: Graber TM, ed. *Orthodontics: Current Principles and Techniques*. St Louis, Miss: Mosby; 1985:565–640.
2. Proffit WR. Biomechanics and mechanics. In: Proffit WR, Fields HW Jr, eds. *Contemporary Orthodontics*. St Louis, Miss: Mosby; 2000:295–362.
3. Creekmore TD, Eklund MK The possibility of skeletal anchorage. *Journ Clin Orthod*. 1983; 17:266–269.
4. Silvia Geron et al Anchorage Loss—A Multifactorial Response Angle Orthodontist 2003; 73(6): 730-737.
5. Jason B. Cope. Temporary Anchorage Devices in Orthodontics: A Paradigm Shift *Semin Orthod* 2005; 11:3-9.
6. Gainsforth BL, Higley LB. A study of orthodontic anchorage possibilities in basal bone. *Am J Orthod Oral Surg* 1945; 31:406-416.
7. Sugawara J et al 2004 Distal movement of mandibular molars in adult patients with skeletal anchorage system. *Am. J. Orthod. Dentofacial Orthop.*,2004;125(2):130-138.
8. Chung K. R., Kim Y.S, Linton J. L., Lee Y.J. The miniplate with tube for skeletal anchorage. *J. Clin. Orthod* 2002; 36(7): 407-412.
9. Erverdi N., Ascar A. Zygomatic anchorage for en masse retraction in the treatment of severe Class II division 1. *Angle Orthod* 2005; 75(3):483-490.
10. Erverdi N, Keles A, Nanda R. The use of skeletal anchorage in open bite treatment: A cephalometric evaluation. *Angle Orthod* ; 2004,74(3):381-390.
11. Jorge Faber et al. Miniplates allow efficient and effective treatment of anterior open bites. *Dental Press J.Orthod* 2008;13(5):144-157.
12. Instructions For Use Bollard Skeletal Anchor Available from <http://www.titalink.com/wp-content/uploads/2011/10/instructions-surgeon.pdf>