



## Short Communication

## Changing the dynamics of alveolar molding using a modified single cantilever spring

Dolly Patel<sup>1</sup>, Surina Sinha<sup>1\*</sup>, Sanket Ajay Patel<sup>1</sup>

<sup>1</sup>Dept. of Orthodontics, Ahmedabad Municipal Corporation (AMC) Dental College, Ahmedabad, Gujarat, India



## ARTICLE INFO

## Article history:

Received 22-07-2023

Accepted 12-09-2023

Available online 03-10-2023

## Keywords:

PNAM

Cleft lip and palate

Deviated premaxilla

Feeding plate

Presurgical orthopedics

## ABSTRACT

Deviated premaxillary segment commonly seen in bilateral cleft lip and palate causes difficulty during surgical procedures. Modifications in the conventional feeding plate appliance design by incorporation of a single cantilever spring can enable shifting of the deviated premaxillary segment and facilitate alveolar molding. Thus reducing the tissue tension and in turn preventing the prospect of further scarring which can have severe detrimental effects on maxillary growth and as a result aid in achieving better surgical outcome on lip closure.

This article presents a case of a 27 day old infant with a deviated premaxilla which was repositioned for better retraction using a modified cantilever spring design in the molding plate. Reduction in cleft gap while shifting of the premaxillary segment on the right side was seen after full time wear of only 5-6 weeks.

This is an Open Access (OA) journal, and articles are distributed under the terms of the [Creative Commons Attribution-NonCommercial 4.0 International](https://creativecommons.org/licenses/by-nc/4.0/), which allows others to remix, and build upon the work non-commercially, as long as appropriate credit is given and the new creations are licensed under the identical terms.

For reprints contact: [reprint@ipinnovative.com](mailto:reprint@ipinnovative.com)

### 1. Introduction

In India alone, the number of infants born every year with Cleft lip and palate (CLCP) is 28,600, which means 78 affected infants are born every day or three infants with clefts born every hour.<sup>1</sup> Although the PNAM (Presurgical nasoalveolar molding) by Grayson et al was challenged by some researchers owing to additional cost and with no extra benefits in the final treatment outcome, it still continues to play significant role in neonatal cleft lip and/or palate treatment till date as it aids in accomplishment of a nonsurgical columella lengthening in combination with the molding of the alveolar process.<sup>2</sup>

The primary objective of Presurgical orthopedics in protruded premaxillary cases has been to retract the protruded premaxilla to a position that allows the surgeon to perform a more functional and attractive repair. However, bilateral Cleft cases present a difficult challenge when the

deviation is asymmetrical on either side. The conventional nasoalveolar molding technique as described by Grayson et al uses acrylic nasal stents attached to an oral molding plate in order to mold the nasoalveolar cartilage.<sup>2</sup> This plays a major role in achieving significant reduction in cleft gap in both unilateral (ULCP) and Bilateral cleft lip and palate (BLCP) cases. The present case presents a modification in the feeding plate design with the incorporation of single cantilever spring which helped in the shifting of the deviated premaxillary segment in such a BLCP case.

### 2. Appliance Design

A conventional molding plate for BLCP as described by Grayson et al with a thickness of 2-3mm was fabricated using an acrylic cup for the premaxilla. The inner surface was lined with a soft liner providing a cushioning effect and then connected to the feeding plate using the cantilever spring. (Figure 1) The single cantilever spring with a helix of diameter 1mm was fabricated using 0.018 supreme grade

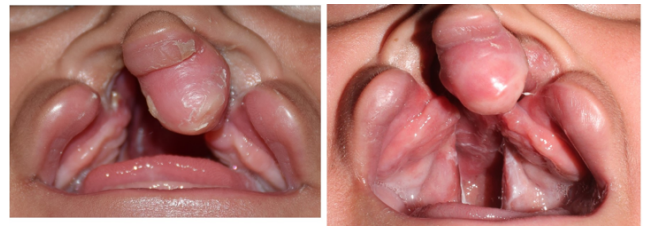
\* Corresponding author.

E-mail address: [surina.sinha11@gmail.com](mailto:surina.sinha11@gmail.com) (S. Sinha).


AJ Wilcock wire and incorporated into the feeding plate which was activated at each appointment by opening the helix with force levels of approximately 25-30gms/cm<sup>2</sup>. It was maintained in position in infant’s mouth 24 hrs a day and removed only for cleaning after feeds.

**3. Case Report**

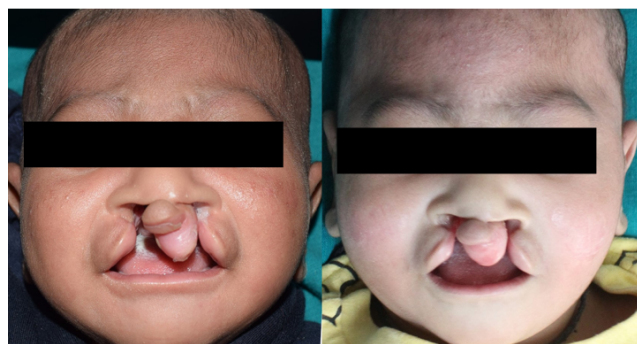A 27-day-old male infant reported with the chief complaint of complete clefting in lip and palate region with difficulty in feeding. He was diagnosed with a complete bilateral cleft lip and palate involving lip, alveolus, hard palate and soft palate (Veau’s Group IV classification) along with a prominent premaxillary segment deviated to left side, thus leading to a severe facial deformity with flattened alar domes and a missing philtrum (Figure 2).




**Figure 4:** Pre and post treatment intraoral photographs aren't at same level



**Figure 1:** Cantilever spring in position before fabrication, Modified feeding plate appliance, Cantilever spring design



**Figure 2:** Pre and post treatment extraoral photographs



**Figure 3:** Anatomical landmarks and pre treatment and post treatment models

**4. Results**

Model analysis (Table 1)<sup>3,4</sup> shows that as the cleft gap reduced between the right and left segments, the distance anterior, middle and posterior segments also reduced (Figure 3). The distance between RPL-LPL increased suggesting widening of the arch and developing arch form. The reduction of 8 mm in X-RAA and 1mm in Y-RAA indicates alignment of premaxilla on the right side in conjunction with the growth of alveolar segments.

**5. Discussion**

In bilateral cleft lip and palate the two posterior segments might be collapsed causing a tripod effect and hence the posterior segments should also be moulded to move buccally while reducing the cleft gap both transverse and A-P direction. The challenge is increased if the premaxillary segment in BLCP is deviated on one side and is not symmetrical.

*5.1. Alveolar molding*

The molding plate was trimmed from inside at the alveolar region along the posterior segments and soft liner was added to aid in remodelling of the arch in the palatal region of the plate. This allowed the alveolar and palatal segments to grow naturally towards the midline without the interference of tongue.<sup>5</sup> After 6 weeks of continuous wear and activation, the cleft gap reduced and the premaxilla shifted on the right side. (Figures 2 and 4).

**6. Conclusion**

Incorporation of the cantilever spring in the conventional design offers a new approach in the dynamics of alveolar molding which aids the shift of the deviated pre-maxillary segment.

**7. Ethical Approval**

We have read and complied with the instructions to authors and in particular the policy of journal on ethical consent.

**Table 1:** Anatomical landmarks and pre treatment and post treatment measurements on study models. (Figure 3)

| Abbreviations        | Landmarks                                                           | Pre-Treatment (mm) | Post Treatment (mm) | Difference (mm) |
|----------------------|---------------------------------------------------------------------|--------------------|---------------------|-----------------|
| RAA-LAA              | Most anterior and superior point of right and alveolar segment      | 15.0               | 12.5                | 2.5             |
| RAM-LAM              | Middle of right and left alveolar segment                           | 15.2               | 10.5                | 4.7             |
| RAP-LAP              | Most posterior and medial point on right and left alveolar segment  | 17.4               | 8                   | 9.4             |
| RPL-LPL              | Most posterior and lateral point on right and left alveolar segment | 33.3               | 35                  | -1.7            |
| LF-POSTERIOR SEGMENT | Labial frenum                                                       | 29                 | 33                  | -4              |
| Y-LAA                | Y-Lateral most point on the left side of premaxilla                 | 9                  | 8                   | 1               |
| X-RAA                | X-Lateral most point on the right side of premaxilla                | 17                 | 9                   | 8               |

## 8. Source of Funding

None.

## 9. Conflict of Interest

None.

## References


1. Mossey P, Little J. Addressing the challenges of cleft lip and palate research in India. *Indian J Plast Surg.* 2009;42(3):9–18.
2. Grayson BH, Santiago PE, Brecht LE, Cutting CB. Presurgical Nasoalveolar Molding in Infants with Cleft Lip and Palate. *Cleft Palate Craniofac J.* 1999;36(6):486–98.
3. Agrawal R, Patel D, Vora P. Orthopaedic traction with passive nasoalveolar moulding in a bilateral cleft lip and palate patient - Rediscovering the old. *JPRAS Open.* 2019;19:50–5.
4. Patel D, Goyal R, Puri T. Presurgical Nasoalveolar Moulding-An Adjunct to Facilitate Surgical Repair in Infants with Cleft Lip and


Palate. *Mod Plast Surg.* 2013;3(1):34–42.

5. Patel D, Goyal R. Pre-surgical nasoalveolar moulding in patient with unilateral cleft of lip, alveolus and palate: Case report. *J Plast Reconstr Amp Aesthet Surg.* 2012;65(1):122–8.

## Author biography

**Dolly Patel**, Dean and Head  <https://orcid.org/0000-0003-1490-656X>

**Surina Sinha**, Lecturer  <https://orcid.org/0009-0006-3875-4221>

**Sanket Ajay Patel**, Post Graduate Student  <https://orcid.org/0009-0003-0216-4340>

**Cite this article:** Patel D, Sinha S, Ajay Patel S. Changing the dynamics of alveolar molding using a modified single cantilever spring. *J Contemp Orthod* 2023;7(3):253-255.