



Original Research Article

Beyond the ARCH: Examining mandibular third molar movements in response to premolar and single incisor extractions in orthodontic practice

Swaroopa Rani Ponnada ^{1*}, Sharmila Kantheti ¹, Chandrasekhar Gandikota ¹,
Ranjit Manne ¹

¹Dept. of Orthodontics, SOA University, Panineeya Mahavidyalaya Institute of dental Sciences and Research Centre, Hyderabad, Telangana, India



ARTICLE INFO

Article history:

Received 17-01-2024

Accepted 06-03-2024

Available online 15-05-2024

Keywords:

Orthopantomogram (OPG)

Mandibular molar

ABSTRACT

Background and Objectives: Mandibular third molars have been the interest of the orthodontic professionals, not only because of their Position Eruptive pattern, also because of their possible role in the development of late incisor crowding. The impaction rate of the third molars (mandible > maxilla) is high compared to any other teeth. The impaction incidence of M3s may be lower in patients with orthodontic premolar extraction due to mesial movement of the posterior teeth. In this study angular and positional changes of mandibular 3rd molars will be evaluated with premolars as well as single incisor extraction.

Materials and Methods: This study includes 30 Pre-treatment and post-treatment orthopantomogram (OPG) of patients seeking orthodontic treatment with extractions of premolars, single incisor are categorized into 2 groups -Group I includes premolar extractions, Group II includes single incisor extractions.

Results : The study concluded that extracting premolars or single incisors did not result in improved mandibular M3 angulation on both left and right sides during the observation period.

Conclusion : The insignificant change in angulation suggests that there are other factors that play a role in the process of alteration of third molar angulation

This is an Open Access (OA) journal, and articles are distributed under the terms of the [Creative Commons Attribution-NonCommercial-ShareAlike 4.0 License](https://creativecommons.org/licenses/by-nc-sa/4.0/), which allows others to remix, and build upon the work non-commercially, as long as appropriate credit is given and the new creations are licensed under the identical terms.

For reprints contact: reprint@ipinnovative.com

1. Introduction

The eruption of the mandibular third molar (M3) and their influence on the dental arch has long been a subject of controversy that interests various specialties of dentistry.¹

The impaction rate for the third molar (M3) is higher than any other tooth, approaching 24% worldwide. M3 impaction is more frequently observed in the mandible than in the maxilla.²

Third molars possess a diverse array of characteristics, including varying shapes, sizes, positions, root formations, and eruption pathways.

There are various hypotheses presumed for impaction of 3rd molars, these include as the bud of the third molar emerges and comes into contact with the second molar, it undergoes significant pre-eruptive rotational movements and angular positioning. These movements and positions continue even after the third molars have fully emerged, causing crowding in the front lower jaw.³

The inadequate space behind the molars and limited jaw bone remodelling can present challenges for the eruption of third molars. Additionally, the absence of periosteal growth on the maxillary tuberosity can also hinder the emerging of maxillary third molars.^{4,5} due to natural attrition between neighbouring teeth which allowed for drifting of the posterior teeth, lack of proper uprightness during the process

* Corresponding author.

E-mail address: swaroopaponnada@gmail.com (S. R. Ponnada).

of root formation often results in third molar impaction, particularly more frequently in the lower jaw rather than the upper.⁶

Third molars can appear on radiographs as early as 5 or as late as 16 years. Initially, lower third molars show mesial inclination, becoming more upright until age 25, often erupting between 18 and 24 years.⁷

Various studies have been validated to substantiate the association between premolar extraction treatment, mesial molar movement, and increased eruption space for third molars.^{8–10}

Hence, the present study has been taken up to see for the possibility of co-relation between extraction pattern and M3 angulation.

2. Materials and Methods

A total of thirty samples of Orthopantomograms (pre-treatment & post-treatment) of patients who have reported to the centre seeking for an orthodontic treatment have been collected.

These were divided into 2 groups

-Group I including Premolar extractions

-Group II including Single incisor extractions

This study was conducted after obtaining an ethical clearance from the institution (IEC No: PMVIDS & RC/IEC/ORTHO/PR/547-22)

The orthopantomograms of patients included in this study were of Asian ethnicity & South Indian demography.

The *inclusion criteria* include

Panoramic radiographs at T0 & T1 of patients with formulated treatment plan of extraction of premolars and single incisor.⁵

The *exclusion criteria* include

1. Patients were excluded if the 3rd molars at T0 had already erupted

2. Any dental abnormalities (hypo-/ hypodontia,³ impaction, dental transposition,¹ microdontia, or cysts), distalization mechanics, congenital malformations,⁹ or syndromes.¹¹

Panoramic radiographs (T0 and T1) were assessed using a standardized technique involving tracing the tooth outlines (premolars and molars) on matte acetate paper.

The line connecting the mesiobuccal cusps of the first molar with the buccal cusps of the second premolar defined the occlusal plane (OP): (M3–OP)

Two angular measurements were measured as described below:

1. The angle between the long axis of the third molar (M3) (line bisecting the line connecting the mesial and distal outlines of the cervical areas)

2. The angle between the long axis of the second molar (M2) (midocclusal point through the midpoint of the root bifurcation and the midpoint between the mesial and distal root tips) and the long axis of the third molar: (M3–M2)¹

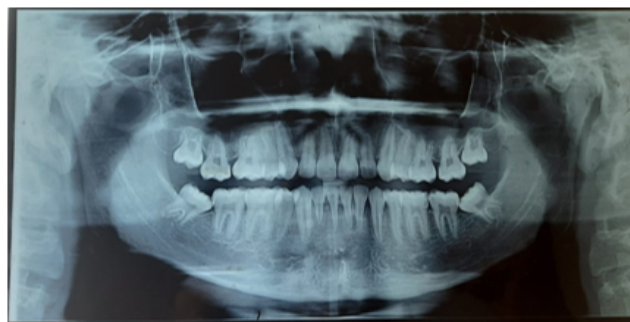

Figure 1: OPG showing angulated molars

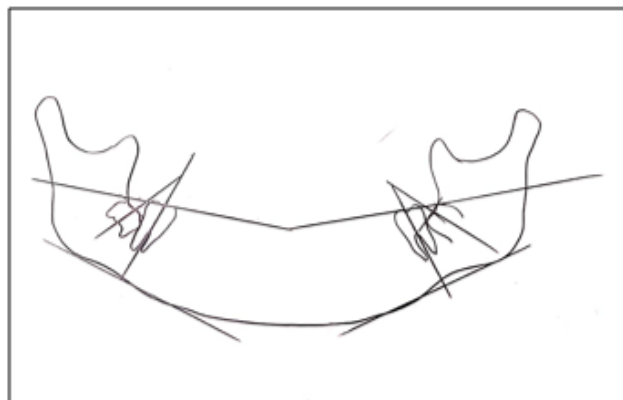
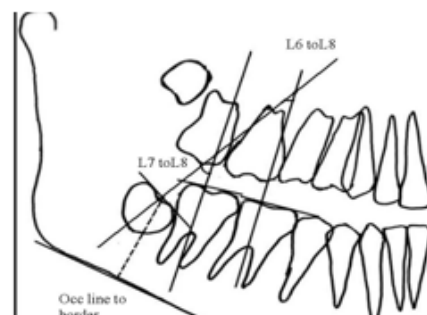
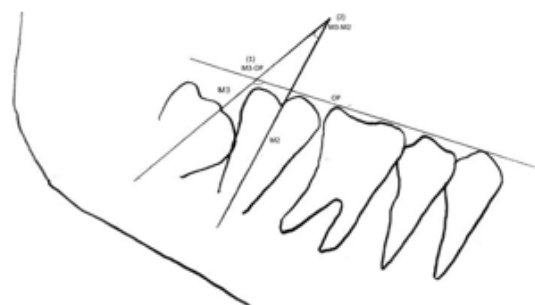


Figure 2: Tracing of OPG with premolar extraction



Figure 3: Tracing of OPG with premolar extraction



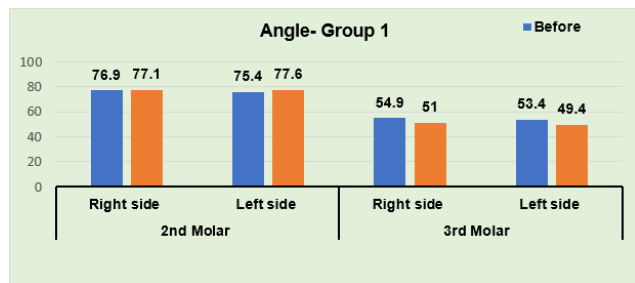
The impaction rate for the third molar (M3) is higher than any other tooth, approaching 24% worldwide. IM3 impaction is more frequently observed in the mandible than in the maxilla.

The impaction rate for the third molar (M3) is higher than any other tooth, approaching 24% worldwide. 1 M3 impaction is more frequently observed in the mandible than in the maxilla.

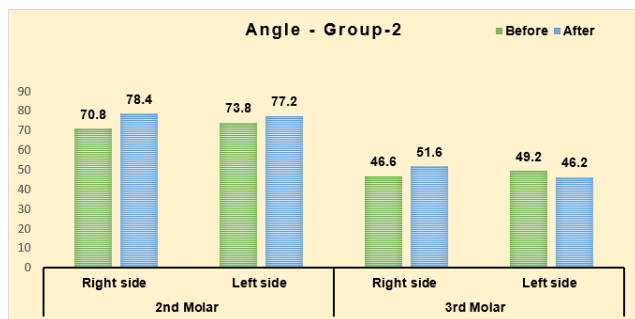
The impaction rate for the third molar (M3) is higher than any other tooth, approaching 24% worldwide. 1 M3 impaction is more frequently observed in the mandible than in the maxilla.

3. Results

The angular measurements of 2nd and 3rd molars and linear measurement of 3rd molar to assess the positional changes on both left and right sides were entered into a master excel sheet and descriptive statistical analysis was performed.



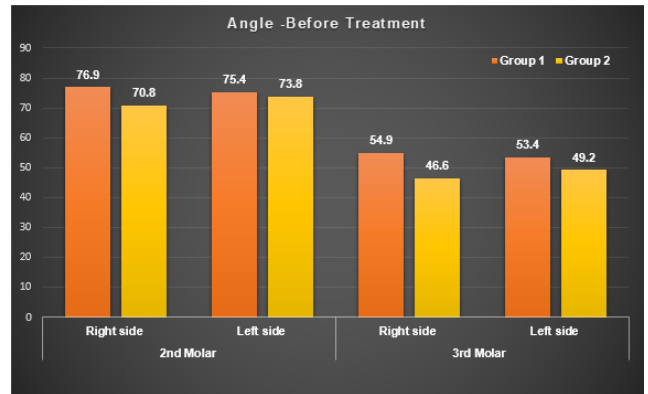
Graph 1: Mean comparison of the angle of Mandibular Molar in Group 1 before and after the treatment.



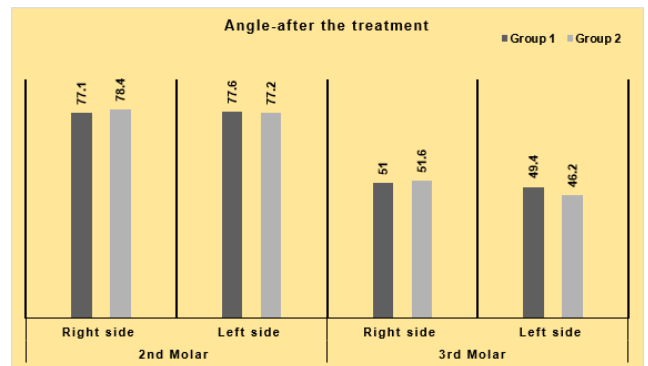
Graph 2: Mean comparison of the angle of Mandibular Molar in Group 2 before and after the treatment.

4. Discussion

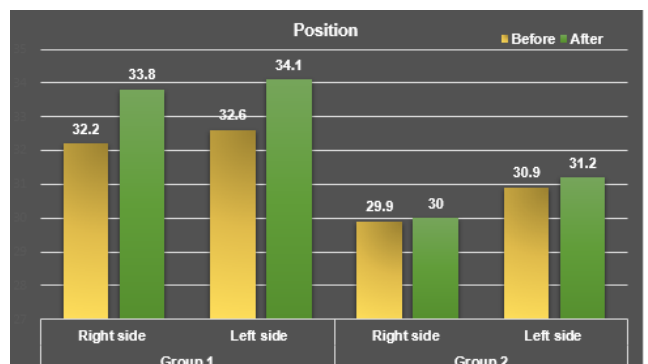Predicting third molar eruption during orthodontic treatment can prevent the future insight of impactions, thereby addressing the clinical challenge associated with third molar impaction.¹²



Graph 3: Mean comparison of the angle of mandibular molar between groups before treatment.



Graph 4: Mean comparison of the angle of Mandibular Molar between Groups after the treatment.



Graph 5: Mean comparison of the position of mandibular molar in groups before and after the treatment.

Table 1: Mean comparison of the angle of Mandibular Molar in Group 1 before and after the treatment.

Mand. Molar	Side	Timeline	n	Mean	SD	Test statistic	P value
2 nd Molar	Right side	Before	15	76.9333	4.46361	-0.228	0.820
		After	15	77.1333	8.28826		
	Left side	Before	15	75.4667	6.20906	-1.155	0.248
		After	15	77.6000	6.06865		
3 rd Molar	Right side	Before	15	54.9333	22.37175	-1.307	0.191
		After	15	51.0667	27.47588		
	Left side	Before	15	53.4000	19.78383	-1.382	0.167
		After	15	49.4667	22.73093		

Wilcoxon Signed Rank test; $p \leq 0.05$ considered statistically significant**Table 2:** Mean comparison of the angle of Mandibular Molar in Group 2 before and after the treatment.

Mand. Molar	Side	Timeline	n	Mean	SD	Test statistic	P value
2 nd Molar	Right side	Before	15	70.8667	9.53090	-2.661	0.008*
		After	15	78.4667	5.65517		
	Left side	Before	15	73.8000	5.73461	-2.091	0.036*
		After	15	77.2000	3.14416		
3 rd Molar	Right side	Before	15	46.6000	15.72441	-0.654	0.513
		After	15	51.6000	20.64600		
	Left side	Before	15	49.2667	15.86310	-1.260	0.208
		After	15	46.2000	17.39951		

Wilcoxon Signed Rank test; $p \leq 0.05$ considered statistically significant**Table 3:** Mean comparison of the angle of Mandibular Molar between Groups before treatment

Mand. Molar	Side	Timeline	n	Mean	SD	Test statistic	P value
2 nd Molar	Right side	Group 1	15	76.9333	4.46361	-2.038	0.042*
		Group 2	15	70.8667	9.53090		
	Left side	Group 1	15	75.4667	6.20906	-0.542	0.588
		Group 2	15	73.8000	5.73461		
3 rd Molar	Right side	Group 1	15	54.9333	22.37175	-1.662	0.097
		Group 2	15	46.6000	15.72441		
	Left side	Group 1	15	53.4000	19.78383	-0.936	0.350
		Group 2	15	49.2667	15.86310		

Mann Whitney U test; $p \leq 0.05$ considered statistically significant**Table 4:** Mean comparison of the angle of Mandibular Molar between Groups after the treatment

Mand. Molar	Side	Timeline	n	Mean	SD	Test statistic	P value
2 nd Molar	Right side	Group 1	15	77.1333	8.28826	-0.354	0.744
		Group 2	15	78.4667	5.65517		
	Left side	Group 1	15	77.6000	6.06865	-0.356	0.722
		Group 2	15	77.2000	3.14416		
3 rd Molar	Right side	Group 1	15	51.0667	27.47588	-0.187	0.852
		Group 2	15	51.6000	20.64600		
	Left side	Group 1	15	49.4667	22.73093	-0.832	0.406
		Group 2	15	46.2000	17.39951		

Mann Whitney U test; $p \leq 0.05$ considered statistically significant

Table 5: Mean comparison of the position of Mandibular Molar in Group 1 before and after the treatment.

Mand. Molar	Side	Timeline	n	Mean	SD	Test statistic	P value
3 rd Molar	Right side	Before	15	32.2000	6.10854	-1.203	0.249
		After	15	33.8667	4.22352		
	Left side	Before	15	32.6000	4.71775		
		After	15	34.1333	4.10342		

Paired t-test; p≤0.05 considered statistically significant

Table 6: Mean comparison of the position of Mandibular Molar in Group 2 before and after the treatment.

Mand. Molar	Side	Timeline	n	Mean	SD	Test statistic	P value
3 rd Molar	Right side	Before	15	29.9333	4.02611	-0.202	0.812
		After	15	30.0667	4.09646		
	Left side	Before	15	30.9333	3.19523		
		After	15	31.2667	4.00832		

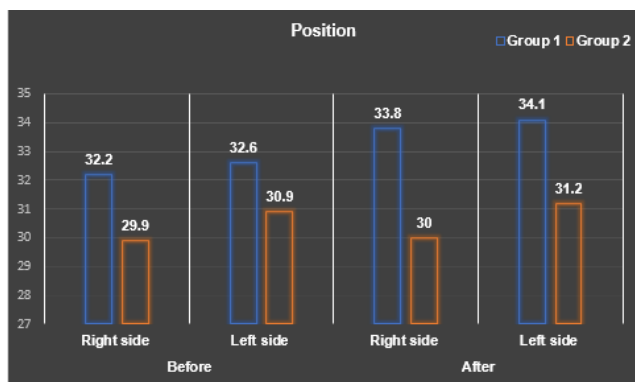
Paired t-test; p≤0.05 considered statistically significant

Table 7: Mean comparison of the position of Mandibular Molar between Groups before the treatment

Mand. Molar	Side	Timeline	n	Mean	SD	Test statistic	P value
3 rd Molar	Right side	Group 1	15	32.2000	6.10854	1.200	0.240
		Group 2	15	29.9333	4.02611		
	Left side	Group 1	15	32.6000	4.71775		
		Group 2	15	30.9333	3.19523		

Table 8: Mean comparison of the position of mandibular molar between Groups after the treatment

Mand. Molar	Side	Timeline	n	Mean	SD	Test statistic	P value
3 rd Molar	Right side	Group 1	15	33.8667	4.22352	2.501	0.018*
		Group 2	15	30.0667	4.09646		
	Left side	Group 1	15	34.1333	4.10342		
		Group 2	15	31.2667	4.00832		



Graph 6: Mean comparison of the position of mandibular molar between Groups before and after the treatment

Measurements of third molar angulation on lateral cephalograms, as seen in previous studies,^{6,8} may be biased because of the differences in the angulation between the superimposed images. Overcoming issues in cephalometric studies of posterior tooth position changes

requires measurements on 60-degree head films of both left and right sides, as demonstrated by Richardson¹³ Hence opps are taken into account in the present study.

There are some factors that influence the eruption of mandibular 3rd molars during calcification, mandibular third molar buds' angle mesially, while maxillary buds' angle distally. Richardson¹³ noted a 11.2° average displacement in mandibular third molars between 10 and 15 years, suggesting a tendency for uprighting. Failure in rotational movements may lead to impaction, but some authors propose that extracting mesially positioned teeth can stimulate uprighting rotational movements.¹⁴

According to various studies, extracting premolars as part of treatment may result in a significant shift of the third molar towards the front of the mouth, while not extracting premolars may lead to a significant increase in the likelihood of the third molar becoming impacted. However, there are differing opinions on this matter, as some researchers have found no noteworthy variances in patients who received treatment with or without premolar extractions.¹⁵

However, in contrast, Haavikko¹⁶ argues that while premolar extractions do have the effect of accelerating the eruption of teeth, they do not necessarily promote the eruption of wisdom teeth.¹⁷

In a study conducted by Saysel et.al. have concluded that the changes in angulation of mandibular third molars in the extraction group were significantly more upright.¹⁸

In a study conducted by Gohilot et.al.¹⁹ A significant improvement in maxillary third molar angulation following extraction treatment was seen on both the right and left sides, however there was no change in the angulation of mandibular 3rd molar was seen in extraction group which was similar to study by Turkoz C et.al.²⁰

In contrary to the above studies significant relationship was observed between the initial age of the patient and the amount of change in the inclination of the third molar in a study by Schiller et.al.²¹

There is gender-specific variations in the angulation of third molars, demonstrating a higher degree of verticalization in women compared to men²² As with previous M3 studies, the present study did not reveal a basis to predict the eruption of M3.²³

In a study conducted by Al kuwari etal it was concluded that the orthodontic treatment involving first premolar extraction has shown improvement in the angulation of third molars during eruption, thereby supporting the implementation of orthodontic extraction therapy in borderline cases.²⁴

In the present study 30 orthopantomograms were taken at T0 and T1 and analysed for positional and angulation changes in mandibular 3rd molars in premolar and single incisor extractions. These were categorized into 2 groups- Group I including premolar extractions & Group II including single incisors.

In comparison between both left and right sides at T0 & T1 there was no significant change in the angular changes of 3rd molars similar to those studies conducted by Saysel etal, Turkoz C etal, and contrary to studies by Al kuwari et.al., Schiller et.al.

However, the present study showed there was statistically significant corelation on the position of mandibular 3rd molar post treatment in comparison to pre-treatment.

The limitations of the present study are that interpreting measurements from dental panoramic tomograms requires caution due to varying vertical and horizontal magnification. Insignificant angulation changes in third molars imply additional factors at play, such as anchorage, impaction type, tooth angulation, treatment duration, and age. These variables contribute to data variability and bias, potentially impacting research results.

5. Conclusion

Extracting the first premolar has a positive impact on the available space for the third molar to properly emerge.

This implies that removing the first premolar allows for additional room, making it easier for the third molar to come through. However, it's worth noting that the study specifically evaluated the third molars' angle and position. While this offers valuable insight, it also recognizes the limitation of not considering other potential factors.

Factors such as dental asymmetry, premature contacts (teeth coming together before they should), and uncontrolled tipping (teeth leaning or tilting) are crucial elements that can influence the overall success of orthodontic treatment involving premolar extraction and impact the final positioning of the third molars

This research highlights the need for a more comprehensive assessment in future studies.

The study emphasizes that while first premolar extraction contributes positively to space management for third molars, a more thorough examination of various dental parameters is essential to draw more conclusive and comprehensive findings.

6. Source of Funding

None.

7. Conflict of Interest


None.

References


1. Durgesh BH, Gowda KH, Alshahrani OA, Almalki AD, Almalki WD, Balharith MM, et al. Influence of premolar extraction or non-extraction orthodontic therapy on the angular changes of mandibular third molars. *Saudi Journal of Biological Sciences*. 2016;23(6):736–776.
2. Rosa MDL, Langer MR, Kouroupakis-Bakouros LJ, Jost-Brinkmann F, Bartzela PG, N T. 2023.
3. Oksayan R, Topcuoglu T. Effects of mandibular third molar angulation and position on crowding. *Turk J Orthod*. 2013;26(3):129–162.
4. Faubion BH. Effect of extraction of premolars on eruption of mandibular third molars. *J Am Dent A*. 1968;76:316–320.
5. Velachery S, Backer S, Shetty S, Parveen K, Shetty NK, Husain A. Angular changes of impacted mandibular third molars and developing mandibular third molars in premolar extraction cases- A retrospective radiographic study. *Int J Oral Health Dent*. 2021;7(1):43–47.
6. Artun J, Thalib L, Little RM. Third molar angulation during and after treatment of adolescent orthodontic patients. *Eur J Orthod*. 2005;27:590–596.
7. Elsey MJ, Rock W. Influence of orthodontic treatment on development of third molars. *British Journal of Oral and Maxillofacial*. 2000;38:350–353.
8. Kim TW, Artun J, Behbehani F, Artese F. Prevalence of third molar impaction in orthodontic patients treated non-extraction and with extraction of 4 premolars. *Am J Orthod Dentofacial Orthop*. 2003;123:138–145.
9. Russell B, Skvara M, Draper E, Proffit WR, Philips C, White RP. 2013.
10. Dierkes DD. An investigation of the mandibular third molars in orthodontic cases. *Angle Orthod*. 1975;45:207–212.
11. Singh S, Garg AK, Gupta DK. Changes in Mandibular Third Molar Angulation in High-anchorage Extraction vs Non-extraction Orthodontic Treatment: A Prospective Study. *J Contemp Dent Pract*. 2020;21(10):1182–1188.

12. Jain S, Valiathan A. Influence of first premolar extraction on mandibular third molar angulation. *Angle Orthod.* 2009;79:1143–1148.
13. Richardson ME, Dent M. Some aspects of lower third molar eruption. *Angle Orthod.* 1974;44(2):141–145.
14. Silling G. Development and eruption of the mandibular third molar and its response to orthodontic therapy. *Angle Orthod.* 1973;43(3):271–8.
15. Tarazona B, Paredes V, Llamas JM. Influence of first and second premolar extraction or non-extraction treatments on mandibular third molar angulation and position. A comparative study. *Med Oral Patol Oral Cir Bucal.* 2010;15(5):760–6.
16. Haavikko K, Altonen M, Mattila K. Predicting angulation development and eruption of the lower third molar. *Angle Orthod.* 1978;48(1):39–48.
17. Mihai AM, Lulache IR, Grigore R, Sanabil AS, Boiangiu S, Ionescu E, et al. Positional changes of the third molar in orthodontically treated patients. *J Med Life.* 2013;6(2):171–5.
18. Saysel MY, Meral GD, Kocadereli I, Tasar F. The effects of first premolar extractions on third molar angulations. *Angle Orthod.* 2005;75:719–41.
19. Gohilot A, Pradhan T, Keluskar KM. Effects of first premolar extraction on maxillary and mandibular third molar angulation after orthodontic therapy. *J Oral Biol Craniofac Res.* 2012;2(2):97–104.
20. Türköz C, Ulusoy C. Effect of premolar extraction on mandibular third molar impaction in young adults. *Angle Orthod.* 2013;83(4):572–7.
21. Shiller WR. Positional changes in mesio-angular impacted mandibular third molars during a year. *J Am Dent Assoc.* 1979;99(3):460–4.
22. Mendoza-García LV, Jiménez EV, Rocha AG. Effect of orthodontic treatment involving first premolar extractions on mandibular third molar angulation and retromolar space. *J Clin Exp Dent.* 2017;9(3):333–7.
23. Hattab FN. Positional changes and eruption of impacted mandibular third molars in young adults. A radiographic 4-year follow-up study. *Oral Surg Oral Med Oral Pathol Oral Radiol Endod.* 1997;84(6):604–8.
24. Albadr RM, Talakey HM, and AAAS. Influence of orthodontic treatment with first premolar extraction on the angulation of the mandibular third molar. *Saudi Med J.* 2013;34(6):639–43.

Author biography

Swaroop Rani Ponnada, Research Scholar & Professor
 <https://orcid.org/0000-0003-3626-377X>

Sharmila Kantheti, PG Student  <https://orcid.org/0000-0003-3626-377X>

Chandrasekhar Gandikota, Professor  <https://orcid.org/0000-0003-3626-377X>

Ranjit Manne, Professor & Head  <https://orcid.org/0000-0003-3626-377X>

Cite this article: Ponnada SR, Kantheti S, Gandikota C, Manne R. Beyond the ARCH: Examining mandibular third molar movements in response to premolar and single incisor extractions in orthodontic practice. *J Contemp Orthod* 2024;8(2):215–221.