



## Original Research Article

# Comparative evaluation of buccolingual inclination of molars in low-angle cases and high-angle cases using manual technique- A pilot study

Ananya Singla <sup>1\*</sup>, Vijay Agarwal <sup>1</sup>, Karamdeep Singh Ahluwalia <sup>1</sup>, Lokendra Singh Dagur <sup>1</sup>, Hari Narayan Choudhary <sup>1</sup>

<sup>1</sup>Dept. of Orthodontics and Dentofacial Orthopaedics, Jaipur Dental College, Jaipur, Rajasthan, India

## ARTICLE INFO

## Article history:

Received 16-02-2024

Accepted 20-03-2024

Available online 27-08-2024

## Keywords:

Buccolingual inclination

Maxillary 1st molar

Vertical growth pattern

Horizontal growth pattern.

## ABSTRACT

**Background:** The general feature of occlusal curvature, when viewed from the front, consists of a buccal inclination of the maxillary molars and a lingual inclination of the mandibular molars. The fourth key of Andrew's six keys of occlusion is related to the curve of Wilson, describing the posterior inclination of the crowns of the lower posterior teeth as a concave curve, setting the molars with a lingual torque. Facial skeletal characteristics of subjects with a vertical growth pattern include increased total face height, especially the lower anterior face height, high mandibular plane angle, clockwise mandibular rotation, short mandibular ramus, and high gonial angle. Opposite aspects are present in subjects with a horizontal growth pattern. This study aimed to measure the buccolingual inclination of maxillary first molars in low-angle and high-angle cases using a manual technique.

**Materials and Methods:** 20 subjects with permanent dentition were divided into 2 groups. Group I comprises 10 subjects with a low-angle case (proportionally short lower anterior facial height) and group II with a high-angle case (proportionally long lower anterior facial height). The buccolingual inclination of 1st molar was assessed on model casts.

**Conclusion:** The maxillary posterior teeth of subjects with a vertical growth pattern (group II) had a significantly greater buccal inclination compared with those of subjects with a horizontal growth pattern (group I).

This is an Open Access (OA) journal, and articles are distributed under the terms of the [Creative Commons Attribution-NonCommercial 4.0 International](https://creativecommons.org/licenses/by-nc/4.0/), which allows others to remix, and build upon the work non-commercially, as long as appropriate credit is given and the new creations are licensed under the identical terms.

For reprints contact: [reprint@ipinnovative.com](mailto:reprint@ipinnovative.com)

## 1. Introduction

Factors such as age, sex, and ethnic group are important in making a proper orthodontic treatment plan; another important factor is the facial growth pattern and its several clinical characteristics.<sup>1</sup> The expression of disharmonious proportions in the facial skeleton can be attributed to the failure of normal, coordinated growth of the various regions of the craniofacial complex in terms of timing, magnitude, and direction. The facial growth pattern is established at an early age, before the eruption of the maxillary first molar.<sup>2</sup>

Facial skeletal characteristics of subjects with high-angle cases include increased total face height, high mandibular plane angle, increased palatal plane angle, clockwise mandibular rotation, short mandibular ramus, and high-gonial angle. Opposite aspects are present in subjects with a low-angle case.<sup>3–10</sup> The soft tissues attempt to compensate for extremes in vertical skeletal support in those persons with long and short vertical facial patterns. Those with short facial patterns have a thinner soft tissue drape that may attempt to mask the strong appearance of the mandible in profile. Conversely, those with long vertical patterns have a thicker integumental profile, which may compensate for the lack of skeletal support.<sup>11–13</sup>

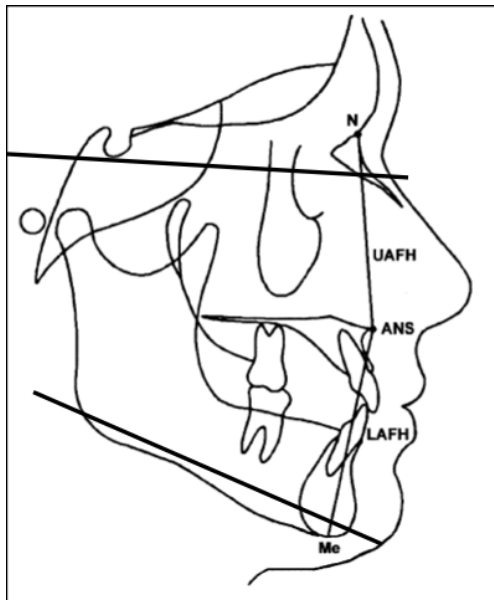
\* Corresponding author.

E-mail address: [ananyasingla9990@gmail.com](mailto:ananyasingla9990@gmail.com) (A. Singla).

Maxillary dental arches of low-angle cases are broader and also show increased overbite. Maxillary dental arches of high-angle cases are narrower, with posterior crossbite tendency and anterior open bite.<sup>14,15</sup>

Andrews suggested the six keys to normal occlusion. The third key relates to crown inclination, which refers to the labiolingual or buccolingual inclination of the long axis of the crown, not to the long axis of the entire tooth. He reported a lingual inclination present in the maxillary and mandibular posterior crowns. It has been reported that the buccolingual inclination of molar crowns changes with the growth of an individual.

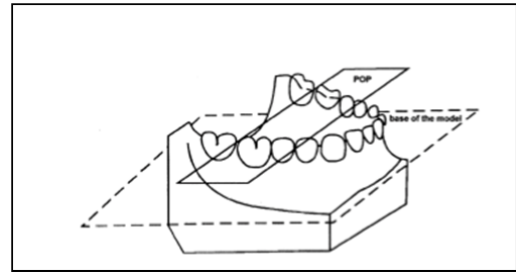
The present study investigated the characteristics of subjects with different facial patterns. We compared the buccolingual inclinations of the posterior teeth (1st molars) in subjects with a low-angle case (proportionally short lower anterior face height) with those in subjects with a high-angle case (proportionally long lower anterior face height) using the conventional technique (model casts).



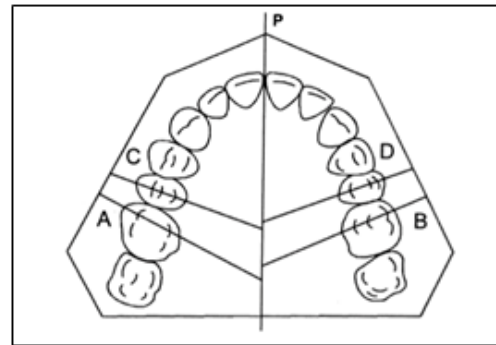
**Figure 1:** Landmarks: nasion (N), anterior nasal spine (ANS), and menton (Me). Linear distances: upper anterior face height (UAFH) and lower anterior face height (LAFH). Angular measurement: mandibular plane angle (Go-Gn-SN).

## 2. Materials and Methods

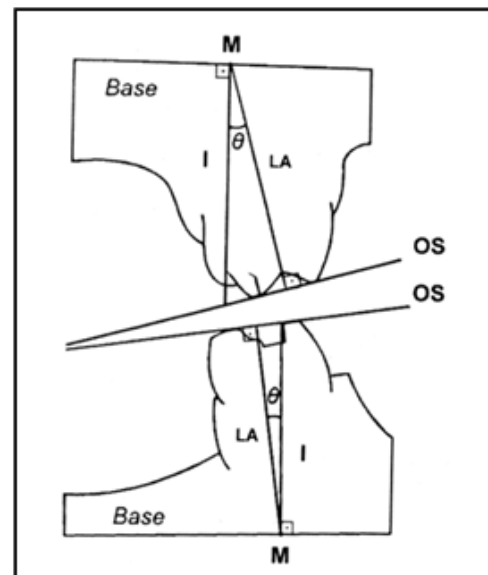
Subjects were selected from the outpatient department of the Department of Orthodontics and Dentofacial Orthopaedics at Jaipur Dental College, Jaipur, Rajasthan. These subjects came to the department voluntarily for orthodontic treatment. Patients who had not undergone orthodontic treatment earlier. The exclusion criteria include patients having severe premolar and molar rotations, partially erupted molars, anterior open bite, any skeletal



**Figure 2:** Trimming of base of models, parallel to posterior occlusal plane (POP), according to method described by Ross et al.



**Figure 3:** Occlusal view of maxillary dental study model. P, Maxillary midline; A, occlusal cut line for maxillary right molar; B, occlusal cut line for maxillary left molar; C, occlusal cut line for maxillary right premolar; D, occlusal cut line for maxillary left premolar.



**Figure 4:** Anteroposterior view of both models. M, Intersection of tooth long axis and dental study model base; LA, tooth long axis; I, line perpendicular to base of models. The angle represents relationship between tooth inclination and line perpendicular to base of model. Reproduced, with modifications, from Ross et al.

deformity, any syndrome, scissor bite and crossbite in the premolar-molar region.

20 subjects with permanent dentition were divided into 2 groups. Group I comprises 10 subjects with low-angle cases (proportionally short lower anterior facial height) and group II with high-angle cases (proportionally long lower anterior facial height). The buccolingual inclination of 1st molar was assessed on model casts.

All subjects were evaluated clinically and facial and lateral photographs were taken. The lateral cephalometric radiograph was used. The cephalograms were traced on an acetate sheet. The ratio between upper and lower anterior face height was determined to check whether either subject is low-angle or high-angle. Go-Gn-SN angle is also checked.

The following landmarks are marked on traced cephalometric sheet (Figure

1. Menton (Me) : the lowest point of the mandibular symphysis
2. Anterior nasal spine (ANS : the tip of the anterior nasal spine
3. Nasion(N):the anterior end of the naso-frontal suture
4. Gonion (Go): A point on the curvature of the angle of the mandible located by bisecting the angle formed by lines tangent to the posterior ramps and the inferior border of the mandible.
5. Gnathion (Gn): A point located by taking the midpoint between the anterior (pogonion) and inferior (menton) points of the bony chin.
6. Sella (Se): The geometric centre of the pituitary fossa

Upper anterior face height (UAFH): the distance between N and ANS (N-ANS).

Lower anterior face height (LAFH): the distance between ANS and Me (ANS-Me).

The mandibular angle is also measured from (Go-Gn-SN). If the angle is less than 32° are considered low-angle cases (horizontal growth pattern) and if the angle is more than 32° are considered high-angle cases (vertical growth pattern).

The 20 dental study models (maxillary and mandibular pretreatment dental study models from the 20 subjects) were taken. The POP was formed by the three most occlusally located cusps of the two first molars and one or both of the premolars. The base of the models was trimmed parallel to the POP. The angle formed by the molar occlusal surface and the POP was determined by trimming the heel of each cast perpendicular to its base (and POP) and parallel to the occlusal line that connects the mesiobuccal and mesiolingual cusp tips through the buccal groove. The right and left heels of each cast were photocopied independently. The inclination of the occlusal surface (OS) was reported as the angle formed by a perpendicular to the OS line and its intersection with the model base, plus or minus

90°. The angle was termed positive when the molar was buccally inclined and negative when the molar was lingually inclined.<sup>16</sup>

Andrews tried to determine the tooth crown inclination, considering the facial axis of the clinical crown and the occlusal plane that passes through the anterior and posterior teeth. The orthodontic study models were sequentially divided into right and left halves through the P cut (Figure 3). The distal portions of each side were then trimmed perpendicularly to their base (and to the POP) up to the occlusal lines (A and B cuts) that pass through the mesiobuccal and mesiolingual cusps of the first molars (Figure 3). The mesial portions of each side were also trimmed perpendicularly to their base and up to the occlusal lines (C and D cuts) that pass through the buccal and lingual cusps (mesiolingual cusp for the mandibular teeth) of the second premolars (Figure 3).

Independent photocopies of the study models were obtained for each quadrant, from the cuts of the first molar and second premolar from both the right and left sides, to determine the planes and angles of interest. Photocopies from partially erupted teeth or teeth with significant rotation were rejected. The M point was obtained by the intersection of the tooth long axis and the dental study model base, from which a line perpendicular to the base was drawn (I line)(Figure 4). Therefore, the angle was obtained between this line and the tooth long axis; it indicated the buccolingual inclination of the occlusal surface of the first molars and second premolars. The angle was positive when the long axes of these teeth (as obtained from the occlusal surfaces) had a buccal inclination, and negative in cases of lingual inclination.

### 3. Result

Mean Value= GROUP I (horizontal growth pattern) shows 1.1° and in GROUP II (vertical growth pattern) shows 5°. Median value calculated for group I (horizontal growth pattern) is 1 and in group II (vertical growth pattern)

### 4. Discussion

The skeletal differences that lead to disproportionate lower face height in long-faced and short-faced children are related to mandibular morphology. The length of the body and ramus of the mandible is similar to that of normal children, but the gonial angle is greatly increased or decreased, respectively.<sup>17</sup> There was an inverse correlation between the upper and the lower anterior and posterior dentoalveolar heights and the ratio UAFH/LAFH, that is, as the ratio increases, the dentoalveolar height decreases. In cases with decreased UAFH/LAFH ratio value (long LAFH), the dentoalveolar height will usually be increased as well, consequently extruding forces on the dentition should be avoided. Evaluation of environmental influences,

such as airway obstruction, should also be performed because there is evidence that a severely obstructed airway is in some instances related to increased or increasing LAFH. On the other hand, cases with short lower anterior face height (large UAFH / LAFH ratio value) or with decreasing lower face height usually present a clear airway passage. In these cases, the dentoalveolar height is also decreased and extrusive forces can and sometimes have to be used to improve the vertical relationships.<sup>18</sup>

**Table 1:** Shows the buccolingual inclination of maxillary 1st molar in Group I (horizontal) and Group II (vertical growth pattern)

Sample no.	Group I	Group II
1	0°	4°
2	1°	6°
3	1°	5°
4	2°	4°
5	2°	6°
6	0°	5°
7	1°	4°
8	2°	4°
9	0°	7°
10	2°	5°

The buccolingual inclination angle does not correspond to the actual long-axis inclination of the teeth but, rather, to the occlusal surface inclination, as evaluated by connecting a line between the mesiobuccal and mesiolingual cusp tips of the posterior teeth.

When there is a severe discrepancy between dental and skeletal, extraction of permanent teeth is usually indicated. However, slight-to-moderate discrepancies between dental and skeletal can be corrected by reducing dental structures by interproximal stripping, expanding the dental arch, or a combination of both. Therefore, when slight or moderate crowding is associated with a narrow dental arch and not with increased dental size, procedures to increase arch dimensions might be considered, to avoid the need for extractions.<sup>19–23</sup>

The suggestion of Howe et al.,<sup>24–29</sup> to treat borderline patients with palatal expansion and buccal inclination of the mandibular posterior teeth, is especially applicable for those with horizontal facial patterns, as compared with those with vertical growth patterns. A common collateral effect of maxillary expansion is buccal tipping of the maxillary posterior teeth.<sup>30–33</sup> Therefore, because of the greater palatal inclination of the maxillary posterior teeth in this facial pattern, a greater maxillary expansion could be carried out without causing an accentuated and unfavourable buccal tipping of the posterior teeth, which could lead to a greater relapse of the expansion.

## 5. Conclusion

The following conclusion can be made:

The maxillary posterior teeth in subjects with high-angle cases have a significantly greater buccal inclination as compared with those with low-angle cases.

## 6. Source of Funding

None.

## 7. Conflict of Interest

None.


## References


- Christie T. Cephalometric patterns of adults with normal occlusion. *Angle Orthod.* 1977;47(2):128–63.
- Nanda S. Patterns of vertical growth in the face. *Am J Orthod Dentofac Orthop.* 1988;93(2):103–19.
- Lai J, Ghosh J, Nanda R. Effects of orthodontic therapy on the facial profile in long and short vertical facial patterns. *Am J Orthod Dentofac Orthop.* 2000;118(5):505–18.
- McLaughlin R, Bennett J. The extraction-non extraction dilemma as it relates to TMD. *Angle Orthod.* 1995;65(3):175–86.
- Taner-Sarisoy L, Darendeliler N. The influence of extraction orthodontic treatment on craniofacial structures: evaluation according to two different factors. *Am J Orthod Dentofac Orthop.* 1999;115(5):508–22.
- Woods M. A reassessment of space requirements for lower arch leveling. *J Clin Orthod.* 1986;20(11):770–8.
- Yamaguchi K, Nanda R. The effects of extraction and nonextraction on the mandibular position. *Am J Orthod Dentofac Orthop.* 1991;100(5):443–52.
- Dahlberg G. Statistical methods for medical and biological students. *Br Med J.* 1940;2(4158):358–9.
- Bean L, Kramer J, Khouw F. A simplified method of taking radiographs for cephalometric analysis. *J Oral Surg.* 1970;28(9):675–83.
- Khouw F, Proffit W, White R. Cephalometric evaluation of patients with dentofacial disharmonies requiring surgical correction. *Oral Surg Oral Med Oral Pathol.* 1970;29(6):789–98.
- Blanchette ME, Nanda RS, Currier GF, Ghosh J, Nanda SK. A longitudinal cephalometric study of the soft tissue profile of short and long-face syndromes from 7 to 17 years. *Am J Orthod Dentofac Orthop.* 1996;109(2):116–47.
- Creekmore TD, Cetlin NM, Ricketts RM, Root TL, Roth RH. JCO roundtable: diagnosis and treatment planning. *J Clin Orthod.* 1992;26(9):585–606.
- Klapper L, Navarro SF, Bowman D, Pawlowski B. The influence of extraction and nonextraction orthodontic treatment on brachyfacial and dolichofacial growth patterns. *Am J Orthod Dentofac Orthop.* 1992;101(5):425–55.
- Isaacson J, Isaacson R, Speidel T, Worms F. Variation in vertical facial growth and associated variation in skeletal and dental relations. *Angle Orthod.* 1971;41(3):219–48.
- Schudy F. Cant of the occlusal plane and axial inclinations of teeth. *Angle Orthod.* 1963;33:69–82.
- Ross V, Isaacson R, Germane N, Rubenstein L. Influence of vertical growth pattern on faciolingual inclinations and treatment mechanics. *Am J Orthod Dentofac Orthop.* 1990;98(5):422–31.
- Fields H, Proffit W, Nixon W, Phillips C, Stanek E. Facial pattern differences in long-faced children and adults. *Am J Orthod.* 1984;85(3):217–40.
- Janson G, Metaxas A, Woodside D. Variation in maxillary and mandibular molar and incisor vertical dimension in 12-year-old subjects with excess, normal, and short lower anterior face height. *Am J Orthod Dentofac Orthop.* 1994;106:409–27.
- Howe RP, Mcnamara JA, Connor O. An examination of dental crowding and its relationship to tooth size and arch dimension. *Am*

- J Orthod.* 1983;83(5):363–73.
20. Peck S, Peck H. Crown dimension and mandibular incisor crowding. *Angle Orthod.* 1972;42:148–53.
  21. Sheridan J. Air-rotor stripping. *J Clin Orthod.* 1985;19(1):43–59.
  22. Sheridan J. Air-rotor stripping update. *J Clin Orthod.* 1987;21(11):781–9.
  23. Sheridan J, Hasting J. Air-rotor stripping and lower incisor extraction treatment. *J Clin Orthod.* 1992;26(1):18–22.
  24. Ingervall B, Helkimo E. Masticatory muscle force and facial morphology in man. *Arch Oral Biol.* 1978;23(3):203–6.
  25. Proffit W, Fields H, Nixon W. Occlusal forces in normal- and long-face adults. *J Dent Res.* 1983;62(5):566–71.
  26. Proffit W, Fields H. Occlusal forces in normal- and long-face children. *J Dent Res.* 1983;62(5):571–5.
  27. Van Spronsen P, Weijs WA, Valk J, Andersen BP, Van Ginkel F. A comparison of jaw muscle cross-sections of long-face and normal adults. *J Dent Res.* 1992;71(6):1279–85.
  28. Weijs W, Hillen B. Relationships between masticatory muscle cross-section and skull shape. *J Dent Res.* 1984;63(9):1154–61.
  29. Howe R. Palatal expansion using a bonded appliance: report of a case. *Am J Orthod.* 1982;82(6):464–72.
  30. Adkins M, Nanda R, Currier G. Arch perimeter changes on rapid palatal expansion. *Am J Orthod Dentofac Orthop.* 1990;97(3):194–203.
  31. Haas A. Long-term posttreatment evaluation of rapid palatal expansion. *Angle Orthod.* 1980;50(3):189–217.
  32. Mew J. Relapse following maxillary expansion. A study of twenty-five consecutive cases. *Am J Orthod.* 1983;83(1):56–61.
  33. Wertz R. Skeletal and dental changes accompanying rapid mid palatal suture opening. *Am J Orthod.* 1970;58(1):41–66.

### Author biography

**Ananya Singla**, PG Student  <https://orcid.org/0009-0001-7889-2569>

**Vijay Agarwal**, Head of Department, Professor  <https://orcid.org/0009-0005-1039-2284>

**Karamdeep Singh Ahluwalia**, Professor  <https://orcid.org/0000-0002-5457-2325>

**Lokendra Singh Dagur**, Reader  <https://orcid.org/0009-0000-8840-2044>

**Hari Narayan Choudhary**, Reader  <https://orcid.org/0009-0008-1239-586X>

**Cite this article:** Singla A, Agarwal V, Ahluwalia KS, Singh Dagur L, Choudhary HN. Comparative evaluation of buccolingual inclination of molars in low-angle cases and high-angle cases using manual technique- A pilot study. *J Contemp Orthod* 2024;8(3):360-364.