



Case Report

Severe dental malocclusion in a case of repaired unilateral cleft palate managed by orthodontic mechanotherapy alone

Sachin S. Kakodkar ^{1*}

¹Dept. of Orthodontics & Dentofacial Orthopedics, Goa Dental College and Hospital, Bambolim, Goa, India



ARTICLE INFO

Article history:

Received 07-03-2024

Accepted 21-03-2024

Available online 27-08-2024

Keywords:

Severe malocclusion

Preadjusted edgewise appliance

Permanent retention

ABSTRACT

Cleft palate is a developmental abnormality that perforates the palate, and divides the arch segments producing grave malocclusion. Crossbites, labiolingual displacements, rotations, archform distortion and incompatibility are a few facets characterizing the problem. Teeth may be congenitally missing or periodontally infirm in the vicinity of the breakdown. If the skeletal jaw base discrepancy is not major, orthognathic surgery may be omitted and orthodontic mechanics alone can suffice to manipulate the teeth into a decent occlusion. Restorative work for esthetic embellishment can enhance the overall result, particularly if teeth are malformed. This case report describes how severe dental malocclusion arising from a repaired unilateral cleft palate defect was corrected with a fixed preadjusted edgewise appliance, adorning smile esthetics and boosting the patient's self-confidence.

This is an Open Access (OA) journal, and articles are distributed under the terms of the [Creative Commons Attribution-NonCommercial 4.0 International](https://creativecommons.org/licenses/by-nc/4.0/), which allows others to remix, and build upon the work non-commercially, as long as appropriate credit is given and the new creations are licensed under the identical terms.

For reprints contact: reprint@ipinnovative.com

1. Introduction

Cleft lip and palate is the most common craniofacial deformity with higher frequency in Asian people than in other races.^{1,2} These anomalies arise from the blending of genetic and environmental factors or can be one manifestation of a syndrome.^{2,3} Cleft palate is engendered when the palatal shelves fail to unite between the fourth and twelfth week of gestation.² Unilateral cleft lip and palate (UCLP) is the most frequent type⁴ of this class of disorders. The deficiency of maxillofacial growth in UCLP is attributed lack of tissue and intrinsic growth potential as also early reconstructive surgery.⁴⁻⁸ Among dental abnormalities hypodontia, malformations, abnormal eruption patterns are rife.⁸⁻¹² It is not unusual to find congenitally missing teeth or supernumerary teeth in the region of the cleft. To resolve the multiplicity of issues, UCLP patients generally call for interdisciplinary care

with occlusal rehabilitation to meet functional and esthetic norms.

1.1. Diagnosis & etiology

A 19-year-old female patient with unilateral cleft palate (Group II according to Veau's classification) surgically repaired in childhood presented to the department of Orthodontics seeking redressal for her crooked teeth and unsightly smile. She had a leptoprosopic face with hyperdivergent growth trend, straight profile, protrusive upper lip and a shallow labio-mental sulcus. Upon intraoral examination, a Class I malocclusion was apparent with severe crowding, rotations and labiolingual displacements of teeth. The upper right deciduous canine along with all second deciduous molars were over-retained and on the verge of exfoliation. The maxillary anterior teeth were in edge-to-edge bite with the lateral incisors in frank anterior crossbite and the canines highly placed, labially blocked out. The upper dental arch somewhat constricted especially

* Corresponding author.

E-mail address: orthdont@gmail.com (S. S. Kakodkar).

in the canine-bicuspid region (Figure 1).

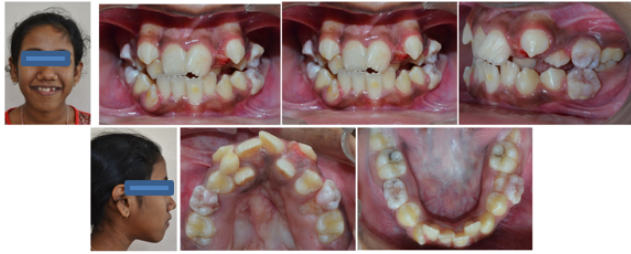

Figure 1: Pretreatment photos (Facial & intra-oral)

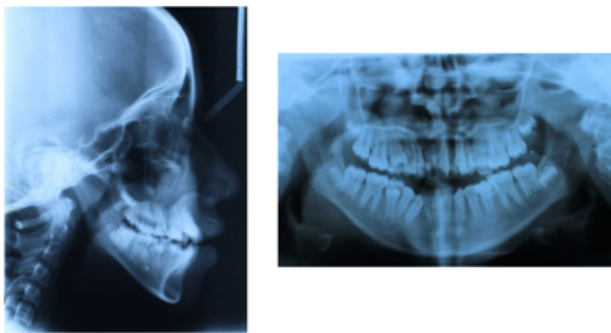
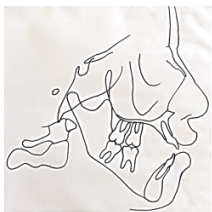

Figure 2: Pretreatment radiographs (Lateral cephalogram & OPG)



| Parameter | Measured value | Norm | Inference |
|--|----------------|-----------|--|
| 1. \angle SNA | 76° | 83±3° | Retrognathic maxilla |
| 2. \angle SNB | 74° | 81±3° | Retrognathic mandible |
| 3. \angle ANB | 2° | 2±2° | Skeletal Class I relation of jaw bases |
| 4. Effective midfacial length (Cd-ANS) | 84 mm. | 94±6 mm. | Under-sized maxilla |
| 5. Effective mandibular length (Cd-Gn) | 111 mm. | 122±4 mm. | Small-sized mandible |
| 6. Jarabak ratio | 54.5% | 62-65% | Hyperdivergent |
| 7. \angle FMA | 43° | 23±6° | Vertical growth pattern |
| 8. \angle UI-SN | 105° | 101-104° | Normally inclined |
| 9. \angle IMPA | 83° | 99±7° | Retroclined |
| 8. Nasolabial angle (\angle Cm-Sn-Ls) | 75° | 102±8° | Acute |

Figure 3: Pre-treatment cephalometric tracing & analysis

1.2. Treatment objectives

Treatment objectives were to rid the patient of dental malocclusion and impart a Class I tooth articulation with comports arches, upscaled masticatory efficiency and smile esthetics, boosting the patient’s self-esteem and acceptance among the peer group.

1.3. Treatment progress

A preadjusted edgewise fixed assembly (0.022” slot, MBT prescription) was availed to rectify the extreme dental irregularity. In addition to the overlying primary

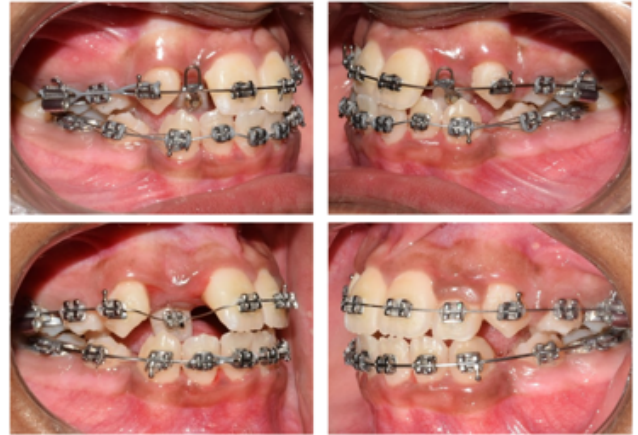

Figure 4: Initial alignment with super-elastic niti wires after space regaining with push coil springs

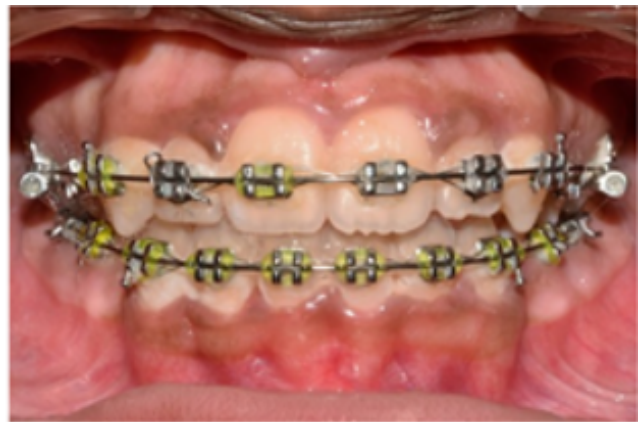

Figure 5: Final alignment with steel arch wires

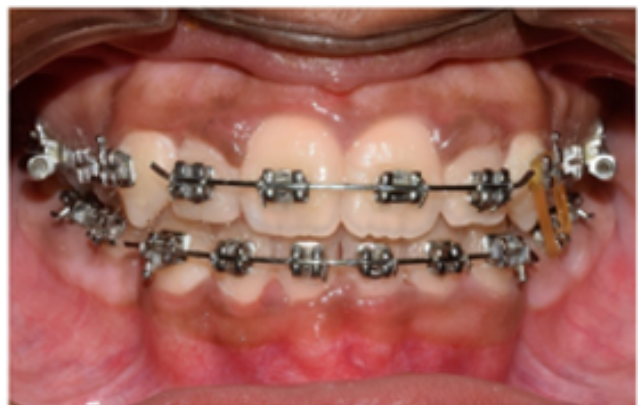

Figure 6: Setting & detailing the occlusion

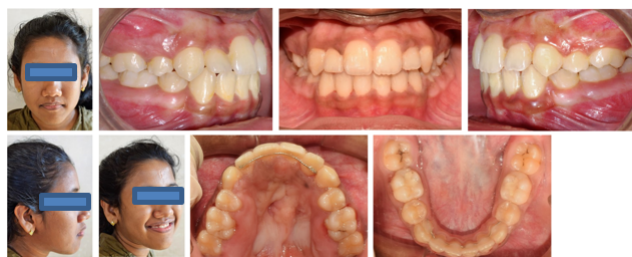

Figure 7: Post-treatment photographs (Facial & intraoral)

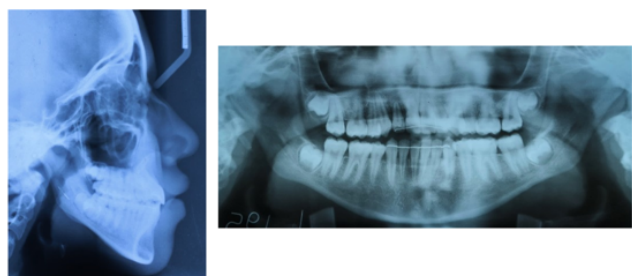


Figure 8: Post-treatment radiographs (lateral cephalogram & OPG)

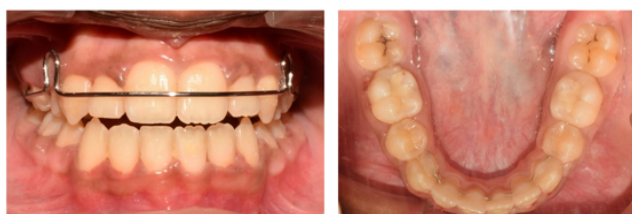

Figure 9: Upper removable Hawley's plate, lower bonded lingual retainer

molars, first bicuspid were extracted in all four quadrants to deal with intense the tooth material-arch length discrepancy. Initial unravelling of overlapping anterior teeth was effected with an 0.014" superelastic Nickel-Titanium (NiTi) wire. Once decrowding had progressed to the point where Australian stainless steel round wires could be engaged, space regaining phase to align the instanding maxillary lateral incisors commenced with push coil springs. Elastomeric traction aided the incisors to 'jump the bite.' Brackets on 12, 22 were inverted to generate labial root torque (Figure 4). After leveling and alignment was consummate in opposing dental arches, coordinated 0.019" x 0.025" rectangular stainless steel wires were ligated with steel ties for optimal arch forms and expression of all features incorporated in the appliance (Figure 5).

Nearly two years of orthodontic mechanotherapy yielded a Class I occlusion with normalized overjet-overbite characteristics, compatible dental arcades and splendid tooth intercuspation in the buccal segments. Crossbites were eliminated and smile esthetics ameliorated (Figure 7).

2. Discussion

Diminished arch lengths in both jaws and transverse maxillary width deficiency have been recorded in preschool children with repaired unilateral cleft lip and palate when contrasted with those healthy and possessing normal occlusion.¹³ The relation of the nasal septum to the palatal processes may play a crucial role in underdevelopment of the maxilla in cleft lip and palate afflictions. Maxillary growth is better and palate dimensions nearly normal when palate closure is carried out after 4 years of age.¹⁴ Surgical repair of the palate prior to 24 months adversely impacted subsequent maxillary growth whereas optimal maxillary arch development occurred when the same transpired between 24-36 months.¹⁵ Maxillary arch widths have not been found to vary between unilateral, bilateral and non-cleft children at age 10 years. Asymmetry was more significant in unilateral clefts when compared with bilateral and non-cleft patients.¹⁶ Maxillary hypoplasia consequent to cleft palate surgery is culpable for dental arch constriction, crossbite and extreme tooth imbrication. Severe skeletal disharmony imposes orthognathic surgery. Unfortunately, this recourse suffers from drawbacks such as 25-40% instability, velopharyngeal incompetency as a limiting factor to the scope of maxillary advancement and the invasive character of the procedure.¹⁷ In the case treated, major disparity between the stricken and normal jaw was not apparent in adult life. However, the scarring i.e. post-cleft darning had given rise to gross distortion of the dentition in both arches. The dental irregularity, crossbites, arch incongruence and poor smile esthetics justified comprehensive orthodontic ministrations with fixed appliances. A bonded lingual flexible wire section in the lower anterior sector and a removable Hawley's plate for the maxillary arch were deemed apposite for long-term retention (Figure 9). The patient is being reviewed every six months for any signs of relapse.

3. Conclusion

While cleft palate rehabilitation largely remains an interdisciplinary endeavor, the orthodontist is a major stakeholder. The warped arch forms, skeletal dysplasia and dental malocclusion are within the purview of his powers and expertise to mitigate. If the skeletal discrepancy is not too grave, orthognathic surgery can be staved off and fixed orthodontic mechanics alone can address the sundry problems with succour from the restorative dentist who can normalize diminutive/malformed teeth, and the prosthodontist who must replace missing teeth in the event of orthodontic space closure not being feasible. Slow dentoalveolar arch expansion may be contemplated when the upper arch has caved-in significantly. Also of cardinal import are delayed alveolar bone grafting to bolster the feeble zone, closure of fistulae, speech therapy and nose/lip

revision surgery if the lip is also breached by the anomaly.

4. Source of Funding

The author received no financial support for research, authorship, and/or publication of this article.

5. Conflict of Interest

The author declared no potential conflict of interest concerning research, authorship, and/or publication of this article.


Acknowledgments

The author would like to thank everyone from the department of Orthodontics in this academic institution for their help, guidance and encouragement.

References

- Ching GH, Chung HS. A genetic study of cleft lip and palate in Hawaii. 1. Interracial crosses. *Am J Hum Genet.* 1974;26:162–76.
- Kim NY, Baek SH. Cleft sidedness and congenitally missing or malformed permanent maxillary lateral incisors in Korean patients with unilateral cleft lip and alveolus or unilateral cleft lip and palate. *Am J Orthod Dentofac Orthop.* 2006;130(6):742–50.
- Kernahan DA, Rosenstein HW. Cleft lip and palate: a systemic management. Baltimore, MD: Williams and Wilkins; 1990. p. 3–51.
- Filho OS, Ramos AL, Abdo RC. The influence of unilateral cleft lip and palate on maxillary dental arch morphology. *Angle Orthod.* 1992;62(4):283–90.
- Trotman CA, Collett AR, Mcnamara JA, Cohen SR. Analysis of craniofacial and dental morphology in monozygotic twins discordant for cleft lip and unilateral cleft lip and palate. *Angle Orthod.* 1993;63(2):135–75.
- Isola G, Matarese G, Cordasco G, Perillo L, Ramaglia L. Mechanobiology of tooth movement during orthodontic treatment: a literature review. *Minerva Stomatol.* 2016;65(5):299–327.
- Garrahy A, Millett DT, Ayoub AF. Early assessment of dental arch development in repaired unilateral cleft lip and palate versus controls. *Cleft Palate Craniofac J.* 2005;42(4):385–91.
- Susami T, Oqihara Y, Matsuzaki M, Sakiyama M, Takato T, Shaw WC. Assessment of dental arch relationships in Japanese patients with unilateral cleft lip and palate. *Cleft Palate Craniofac J.* 2006;43(1):96–102.
- Olin WH. Dental anomalies in cleft lip and palate patients. *Angle Orthod.* 1964;22(2):119–42.
- Ranta R, Tulensalo T. Symmetry and combinations of hypodontia in non-cleft and cleft palate children. *Scand J Dent Res.* 1988;96(1):1–8.
- Shapira Y, Lubit E, Kufninec MM. Hypodontia in children with various type of clefts. *Angle Orthod.* 2000;70(1):16–21.
- Casolato SF, Ross B, Paedo D, Noble J, Tompson B. Treatment of dental anomalies in children with complete unilateral cleft lip and palate at SickKids Hospital. *Cleft Palate Craniofac J.* 2009;46:166–72.
- Buran AS, Nawaya FR. Comparison of dental arch dimensions in models of preschool children with cleft lip/palate repaired by means of surgery alone versus controls. *J Egypt Public Health Assoc.* 2016;91(3):150–5.
- Jorgenson RJ, Shapiro SJ, Odinet KL. Studies of facial growth and arch size in cleft lip and palate. *J Craniofac Genet Dev Biol.* 1984;4(1):33–41.
- Shamsudeen M, Tewari PS. Effect of timing of palatal repair on transverse development of the maxillary alveolar arch in complete-cleft cases. *J Indian Soc Pedod Prev Dent.* 1991;8(1):15–23.
- Schliephake H, Donnerstag JL, Berten N. Palate morphology after unilateral and bilateral cleft lip and palate closure. *Int J Oral Maxillofac Surg.* 2006;35(1):25–30.
- Kim JH, Lee H, Lee SM, Yang B. Distraction osteogenesis and orthognathic surgery for a patient with unilateral cleft lip and palate. *Am J Orthod Dentofac Orthop.* 2015;147(3):381–93.

Author biography

Sachin S. Kakodkar, Assistant Professor  <https://orcid.org/0000-0001-5941-3617>

Cite this article: Kakodkar SS. Severe dental malocclusion in a case of repaired unilateral cleft palate managed by orthodontic mechanotherapy alone. *J Contemp Orthod* 2024;8(3):370-373.